RD
651
U58
fasc.4
1969

# TUMORS of the THYROID GLAND

by

WILLIAM A. MEISSNER, M.D.

and

SHIELDS WARREN, M.D.

AFIP

NIH LIBRARY

# TUMORS of the THYROID GLAND

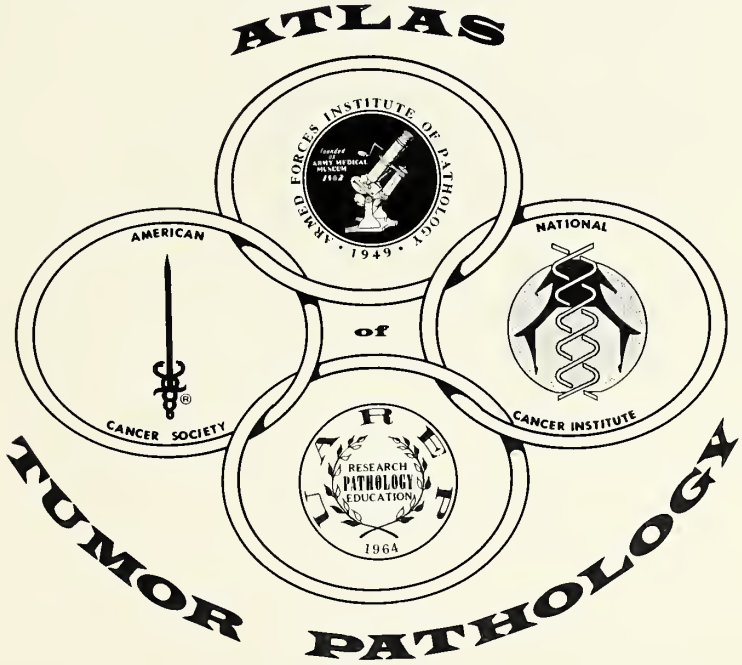

# ATLAS OF TUMOR PATHOLOGY

Second Series

Fascicle 4

# TUMORS OF THE THYROID GLAND

by

WILLIAM A. MEISSNER, M.D.
Clinical Professor of Pathology, Harvard Medical School
Pathologist in Chief, New England Deaconess Hospital
Boston, Massachusetts

and

SHIELDS WARREN, M.D.
Professor of Pathology Emeritus, Harvard Medical School
Pathologist, New England Deaconess Hospital
Boston, Massachusetts

Published by the
ARMED FORCES INSTITUTE OF PATHOLOGY
Washington, D. C.

Under the Auspices of
UNIVERSITIES ASSOCIATED FOR RESEARCH AND EDUCATION IN PATHOLOGY, INC.
Bethesda, Maryland
1969

Accepted for Publication
1968

---

For sale by the American Registry of Pathology
Armed Forces Institute of Pathology
Washington, D. C. 20305

# ATLAS OF TUMOR PATHOLOGY

Sponsored and Supported by

AMERICAN CANCER SOCIETY

NATIONAL CANCER INSTITUTE, NATIONAL INSTITUTES OF HEALTH

U. S. PUBLIC HEALTH SERVICE

and

ARMED FORCES INSTITUTE OF PATHOLOGY


EDITOR

HARLAN I. FIRMINGER, M.D.

Professor, Department of Pathology

University of Maryland School of Medicine

Baltimore, Maryland 21201

and

Director, Universities Associated for

Research and Education in Pathology, Inc.

9650 Rockville Pike

Bethesda, Maryland 20014



EDITORIAL ADVISORY COMMITTEE

| | |
|---|---|
| Lauren V. Ackerman, M.D. | Washington University School of Medicine<br>St. Louis, Missouri |
| David G. Freiman, M.D. | Harvard Medical School<br>Boston, Massachusetts |
| John K. Frost, M.D. | The Johns Hopkins School of Medicine<br>Baltimore, Maryland |
| James C. Harkin, M.D. | Tulane University School of Medicine<br>New Orleans, Louisiana |
| Dante G. Scarpelli, M.D. | University of Kansas Medical Center<br>Kansas City, Kansas |
| Robert E. Scully, M.D. | The Massachusetts General Hospital<br>Boston, Massachusetts |
| Philippe Shubik, M.D. | University of Nebraska College of Medicine<br>Omaha, Nebraska |
| Harlan J. Spjut, M.D. | Baylor University College of Medicine<br>Houston, Texas |

## EDITOR'S NOTE

The Atlas of Tumor Pathology was originated by the Committee on Pathology of the National Academy of Sciences—National Research Council in 1947. The form of the Atlas became the brain child of the Subcommittee on Oncology and was shepherded by a succession of editors. It was supported by a long list of agencies; many of the illustrations were made by the Medical Illustration Service of the Armed Forces Institute of Pathology; the type was set by the Government Printing Office; and the final printing was made by the press at the Armed Forces Institute of Pathology. The American Registry of Pathology purchased the fascicles from the Government Printing Office and sold them at cost, plus a small handling and shipping charge. Over a period of 20 years, 15,000 copies each of 40 fascicles were produced. They provided a system of nomenclature and set standards for histologic diagnosis which has received world-wide acclaim. Private contributions by almost 600 pathologists have helped to finance the compilation of an index by The Williams & Wilkins Company to complete the original Atlas.

Following the preparation of the final fascicle of the first Atlas, the National Academy of Sciences—National Research Council handed over the task of further pursuit of the project to Universities Associated for Research and Education in Pathology, Inc. Grant support for a second series was generously made available by both the National Cancer Institute and the American Cancer Society. The Armed Forces Institute of Pathology has expanded and improved its press facilities to provide for a more rapid and efficient production for the next series. A new Editor and Editorial Advisory Committee were appointed, and the solicitation and preparation of manuscripts continues.

This second series of the Atlas of Tumor Pathology is not intended as a second edition of the first Atlas and, in general, there will be variation in authorship. The basic purpose remains unchanged in providing an Atlas setting standards of diagnosis and terminology. Throughout this new series, the term chosen by the Committee on Tumor Nomenclature of the International Union Against Cancer is shown by an asterisk if it corresponds to the author's heading, or as the first synonym in italics if it differs from the author's first choice. Hematoxylin and eosin stained sections still represent the keystone of histologic diagnosis; therefore, most of the photomicrographs will be of sections stained by this technic, and only sections prepared by other technics will be specifically designated in the legends. It is hoped that in many of the new series a broader perspective of tumors may be offered by the inclusion of special stains, histochemical illustrations, electron micrographs, data on the biologic behavior, and other pertinent information for better understanding of the disease.

The format of the new series is changed in order to allow better correlation of the illustrations with the text, and a more substantial cover is provided. An index will be included in each fascicle.

It is the hope of the Editor, the Editorial Advisory Committee, and the Sponsors that these changes will be welcomed by the readers. Constructive criticisms and suggestions will be appreciated.

Harlan I. Firminger, M.D.

## ACKNOWLEDGMENTS

The authors wish to thank the many individuals whose assistance made the publication of this fascicle possible.

We are indebted to Dr. Gustavus Klinck for his numerous suggestions and for the availability of his files and photographs during the preparation of the manuscript. The interest and recommendations of the special critics are also greatly appreciated. We are grateful to Dr. Harlan I. Firminger, Editor, the members of the Editorial Advisory Committee, and other members of the Editorial Staff. We thank Miss Ethel O'Brien for her secretarial help in preparing the manuscript. We also thank the Photography Department of the Armed Forces Institute of Pathology for their skillful help.

Permission to use copyrighted material has been granted by:

American Medical Association:

J.A.M.A. 113:1098–1105, 1939. For our figure 21

American Society of Clinical Pathologists:

Seminar on Tumors of the Neck given at International Congress of Clinical Pathology by Dr. William A. Meissner, Chicago, 1955. For our figures 87, 96

Franklin H. Martin Memorial Foundation:

Surg. Gynec. Obstet. 88:31–44, 1949. For our figures 73, 89, 90, 93

J. B. Lippincott Company:

Amer. J. Cancer 15:2563–2582, 1931. For our figure 114

Ann. Surg. 112:977–1005, 1940. For our figure 79

J. Clin. Endocr. 8:749–765, 1948. For our figures 69, 78, 83, 109

J. Clin. Endocr. 9:1216–1231, 1949. For our figures 66, 80

Massachusetts Medical Society:

New Eng. J. Med. 238:758–766, 1948. For our figure 35

Radiology Society of North America, Inc.:

Radiology 54:401–407, 1950. For our figures 81, 82

The Williams & Wilkins Company:

Amer. J. Clin. Path. 20:443–445, 1950. For our figure 64

W. B. Saunders Co.:

A Textbook of Pathology, 2d ed., Philadelphia, 1951. For our figures 45, 51

The authors wish to thank Dr. Gilles Tremblay, Montreal, Canada, for Figures 7 through 11; Dr. Charles Gilmore, Boston, Massachusetts, for Figures 55 and 56; and Dr. Merlin L. Trumbull, Memphis, Tennessee, for Figure 121. All other illustrations are the authors' own. The A.F.I.P. atlas numbers are for identification of negatives at the Armed Forces Institute of Pathology.

William A. Meissner, M. D.

Shields Warren, M. D.

# CONTENTS


Page No.

INTRODUCTION ..... 11
THE NORMAL THYROID ..... 13
Morphology ..... 13
Development ..... 19
Physiology ..... 19
TUMOR-LIKE LESIONS ..... 25
Anomalous and Ectopic Thyroid Tissue ..... 25
Struma Ovarii ..... 27
Thyroglossal Duct Cyst ..... 28
Intrathyroidal Cysts ..... 29
Adenomatous Goiter ..... 30
Plate I–A, p. 113
Graves' Disease ..... 37
Thyroiditis ..... 37
Plate III–C, p. 117
Subacute Thyroiditis ..... 38
Struma Lymphomatosa ..... 38
Riedel's Struma ..... 38
Nonspecific Chronic Thyroiditis ..... 40
Hamartomatous Adiposity ..... 41
Amyloid Goiter ..... 41
Squamous Metaplasia ..... 42
BENIGN TUMORS ..... 43
Adenoma ..... 43
Table I, p. 50
Follicular Adenoma ..... 43
Plate I–B, p. 113
Embryonal Adenoma ..... 45
Fetal Adenoma ..... 45
Simple Adenoma ..... 46
Colloid Adenoma ..... 46
Oxyphil Adenoma ..... 46
Atypical Adenoma ..... 46
Papillary Adenoma ..... 50
Benign Teratoma of the Thyroid and Thyroid Region ..... 53
Other Benign Tumors ..... 53

Page No.

MALIGNANT TUMORS, GENERAL DISCUSSION ..... 55
Classification ..... 55
Table II, p. 55
Grading ..... 55
Staging ..... 55
Table III, p. 56
Etiology and Histogenesis ..... 57
Epidemiology ..... 57
Spontaneous Tumors in the Thyroid of Animals ..... 58
Experimental Tumors ..... 59
Relationship to Other Thyroid Disease ..... 60
Hyperplasia ..... 60
Adenomatous Goiter ..... 60
Thyroiditis ..... 61
Adenoma ..... 61
Relationship to Other Endocrine Disease ..... 64
Goitrogens ..... 65
Ionizing Radiation ..... 65
Radioiodine Uptake in Thyroid Carcinoma ..... 67
Carcinoma of the Thyroid in Children ..... 69
CARCINOMA ..... 70
Papillary Adenocarcinoma ..... 70
Plates II–A, B, C, p. 115; IV–A, B, p. 119
Mixed Papillary and Follicular Carcinoma ..... 82
Follicular Carcinoma ..... 84
Plate I–D, p. 113
Clear Cell Carcinoma ..... 93
Oxyphil Carcinoma ..... 95
Plate II–D, p. 115
Medullary Carcinoma ..... 96
Plate IV–C, D, E, p. 119
Undifferentiated Carcinoma ..... 102
Plate III–B, p. 117
Small Cell Carcinoma ..... 102
Giant Cell Carcinoma ..... 106
Plate I–C, p. 113
Epidermoid Carcinoma ..... 111

Page No.

MISCELLANEOUS MALIGNANT TUMORS ..... 121
Lymphoma of the Thyroid ..... 121
Primary Lymphoma ..... 121
Secondary Lymphoma ..... 122
Other Sarcomas ..... 123
Malignant Teratoma of the Thyroid and Thyroid Region ..... 126
Carcinoma in Ectopic Thyroid Tissue ..... 127
Secondary Tumor in Thyroid ..... 127
Plate III–A, D, p. 117

INDEX ..... 131

# TUMORS OF THE THYROID GLAND

## INTRODUCTION

Clinical observations and experimental studies have contributed enough new information since publication of the first "Tumors of the Thyroid Gland" in 1953 to warrant a rather complete rewriting of the fascicle. The diagnosis and treatment of thyroid cancer have been improved with the introduction of new technics and with better understanding of the disease. The hormonal dependency of some thyroid tumors is appreciated. In 1963 the pharmacologists, Hirsch and associates, discovered a new thyroid hormone, thyrocalcitonin. More reliable statistics regarding incidence and death rates of thyroid cancer allow a better evaluation of the biologic behavior of these tumors. Many studies implicate radiation as having a role in the development of thyroid tumors in children. In addition to these and other developments, a specific type of thyroid carcinoma has been defined and established as a part of a new syndrome.

In this second writing, we have brought the previous classification and descriptions up to date. Most of the references are recent and many have particularly good bibliographies. Discussions of unusual tumors and tumor-like conditions have been expanded so that the fascicle might be of greater use as a reference. In the pathologic diagnosis of thyroid tumors there are particular problem areas for us, and apparently for our colleagues as well, as evidenced by cases sent for consultation; we have attempted to clarify such problem areas with more extensive discussion and additional photomicrographs.

In spite of great advances in the understanding of thyroid tumors, there are problems and unanswered questions. The great variety of types and the wide range of aggressiveness of thyroid cancers continue to complicate both diagnosis and management. It is a paradox that the low grade papillary adenocarcinoma and the highly malignant giant cell carcinoma both arise from the same follicular epithelium. Evaluation of different methods of therapy continues to be a problem partly because thyroid cancers are uncommon and partly because many of them are very low grade. Five or 10 years is insufficient time for adequate follow-up information for many thyroid tumors; clinical recurrences or death from the tumor may not take place until 20 or 30 years after the original diagnosis. Lastly, it should be stressed that it is still difficult clinically, and at times pathologically, to distinguish true neoplasm from a nodule of endemic goiter.

## THE NORMAL THYROID

**MORPHOLOGY** (Figures 1–13)

The thyroid gland consists of two lateral lobes which usually are connected by an isthmus of variable size. In addition, a pyramidal lobe extends upward from the isthmus in about 40 per cent of persons. The right lobe is often somewhat larger than the left. The gland normally is soft, yellow-red and covered with a thin capsule. Cut surfaces glisten because of colloid. The rich blood supply comes from the superior and inferior thyroid arteries. Lymphatics drain to deep cervical nodes, to pretracheal nodes, and to retrosternal nodes.

The average weight of the normal thyroid generally has been considered to be 25 to 30 gm. with a range of 10 to 60 gm. Recent studies, however, give lower figures, perhaps because of the widespread use of iodized salt. Mochizuki and associates found that the mean weight of adult glands (18 years of age and over) in New York City was 16.7 ± 6.9 gm. (females 14.9 ± 6.7 gm. and males 17.5 ± 6.8 gm.). They estimated that one per cent of New York residents had thyroids weighing about one third of the mean. In children, according to Kay and associates, the average normal weight (again with a wide range) increases from 1.5 gm. at birth to 14.2 gm. in the 15 to 19 year age group.

The unit of thyroid structure is the follicle, a closed sac lined with epithelium and containing colloid (figs. 1, 2). Individual follicles are roughly spherical and vary considerably in size with an average diameter of about 200 micra. Thyroid lobules consist of 20 to 40 follicles bound together by a thin sheath of connective tissue and supplied by a lobular artery; it is possible that nodules develop from such an anatomical unit. In spite of the great vascularity and the close relationship of small vessels and capillaries to the follicles, neither blood vessels nor interfollicular stroma are conspicuous in the normal gland.

NORMAL THYROID

Figure 1. This thyroid when removed at autopsy from an 8-year-old child was considered to be normal. There was no clinical evidence of thyroid disease. Hematoxylin and eosin stain.* × 100. A.F.I.P. Atlas No. 67-3–1.

* Throughout the fascicle where the stain is not so designated, hematoxylin and eosin stain has been used.

The epithelium of the follicle is usually single-layered, cuboidal, and rests on a basement membrane. Electron microscopic studies (figs. 3–5) (Klinck; Heimann) show that the basement membrane envelops the entire follicle, extending without interruption along the bases of the follicular cells, but never into the intercellular spaces. The lateral borders and the base of the cell are covered with a plasma membrane, with the membranes of adjacent cells separated by a space of relatively constant width. On the colloid surface of the cells, there is a brush border composed of cytoplasmic extensions or microvilli which project into the colloid. The microvilli are up to 0.2 microns long.

NORMAL THYROID

Figure 2. The thyroid gland from an 80-year-old man was removed at autopsy. It weighed 15 gm. and was considered to be grossly and microscopically normal. There was no clinical evidence of thyroid disease. On the average, the follicles are somewhat larger than those in the 8-year-old child and the epithelium tends to be more flattened, indicating decreased activity. × 100. A.F.I.P. Atlas No. 67-3-2.

In the resting cell the nucleus is usually central, roughly spherical, and about one-third the diameter of the cell. The nucleolus is not prominent. Mitochondria are evenly distributed throughout the cytoplasm. They are rod-shaped with the cristae oriented at right angles to the long axis. The endoplasmic reticulum is conspicuous, widely distributed, and predominantly of the rough-surfaced type. Ribosomes lie both free in the cytoplasm and along the covering membranes of the cisterns. The colloid is uniform in density and slightly acidophilic. With the light microscope, vacuoles are often seen at its periphery, giving a scalloped appearance. By electron microscopy, such vacuoles are not found.

When stimulated to increased activity, the follicle becomes smaller, colloid diminishes, the follicular cells become tall columnar, and the nuclei enlarge and lie nearer the base. There is an increase in endoplasmic reticulum and in ribosomes, and the Golgi apparatus hypertrophies. Microvilli are greatly increased both in number and in length. Intracytoplasmic droplets appear which apparently are colloid droplets and represent colloid that has been engulfed by cytoplasmic pseudopod streamers.

With decreased activity the follicles enlarge and accumulate more colloid; the epithelium changes to a low cuboidal or flat type. In older individuals the follicles become less active, presumably because of diminished requirements; some, but not all, glands in older persons show a mild increase of stromal connective tissue.

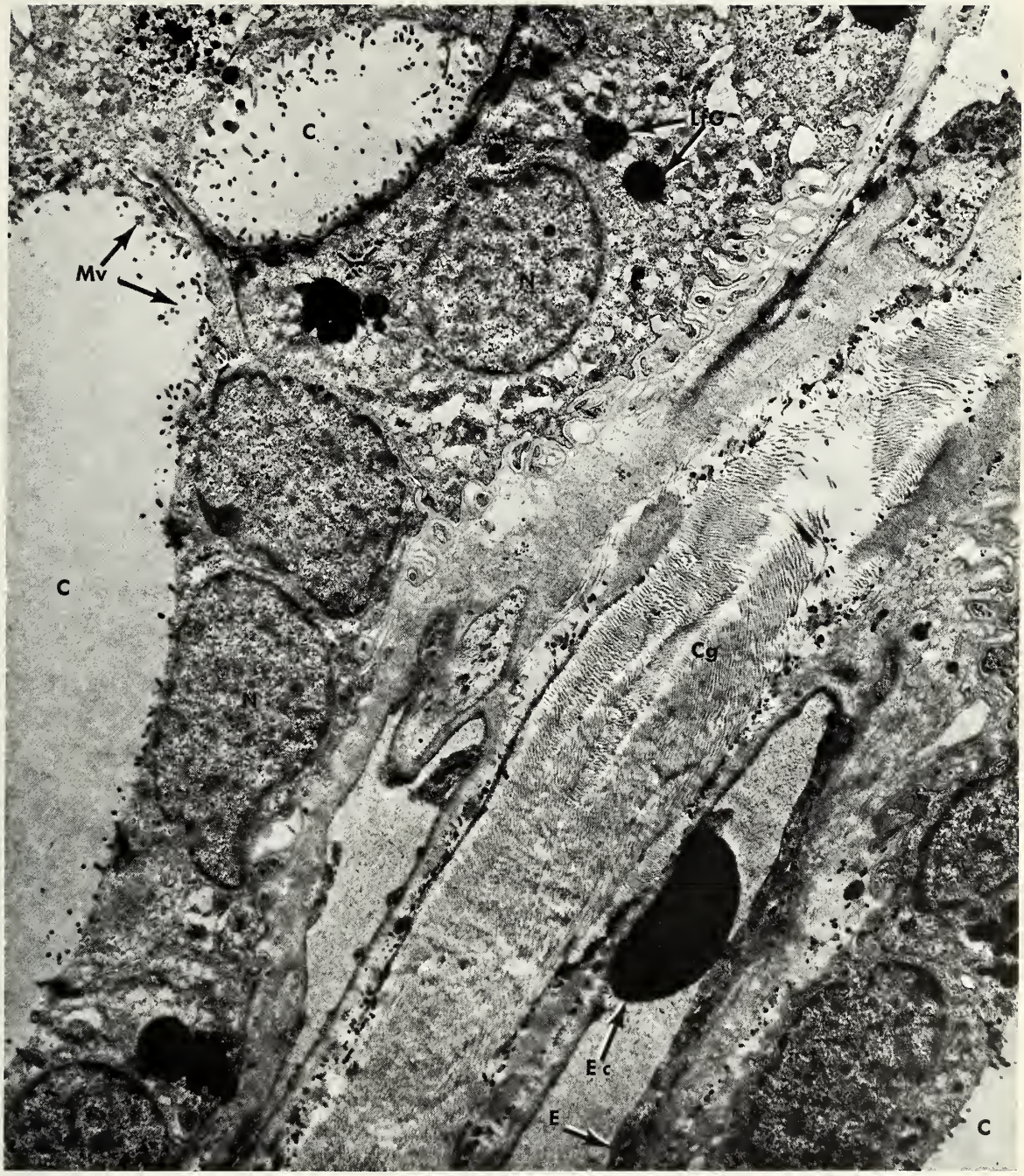


NORMAL THYROID

Figure 3. An electron micrograph shows portions of two adjoining follicles. The microvilli projecting into the colloid are clearly visible. The structures are identified as follows: C, colloid; Cg, collagen; E, endothelium; Ec, erythrocyte; LfG, lipofuscin granule; Mv, microvilli; N, nucleus. Approx. × 4500. (Courtesy of the Armed Forces Institute of Pathology.) A.F.I.P. Atlas No. 67-3-3.

NORMAL THYROID

Figure 4. This electron micrograph also shows portions of two adjacent follicles. The epithelial layer of the lower follicle is flat. These structures are identified as follows: BL, basal lamina; C, colloid; Cg, collagen; Ec, erythrocyte; IS, intercellular space; LfG, lipofuscin granule; M, mitochondria; N, nucleus; Nl, nucleolus. × 10,000. (Courtesy of the Armed Forces Institute of Pathology.) A.F.I.P. Atlas No. 67-3-4.

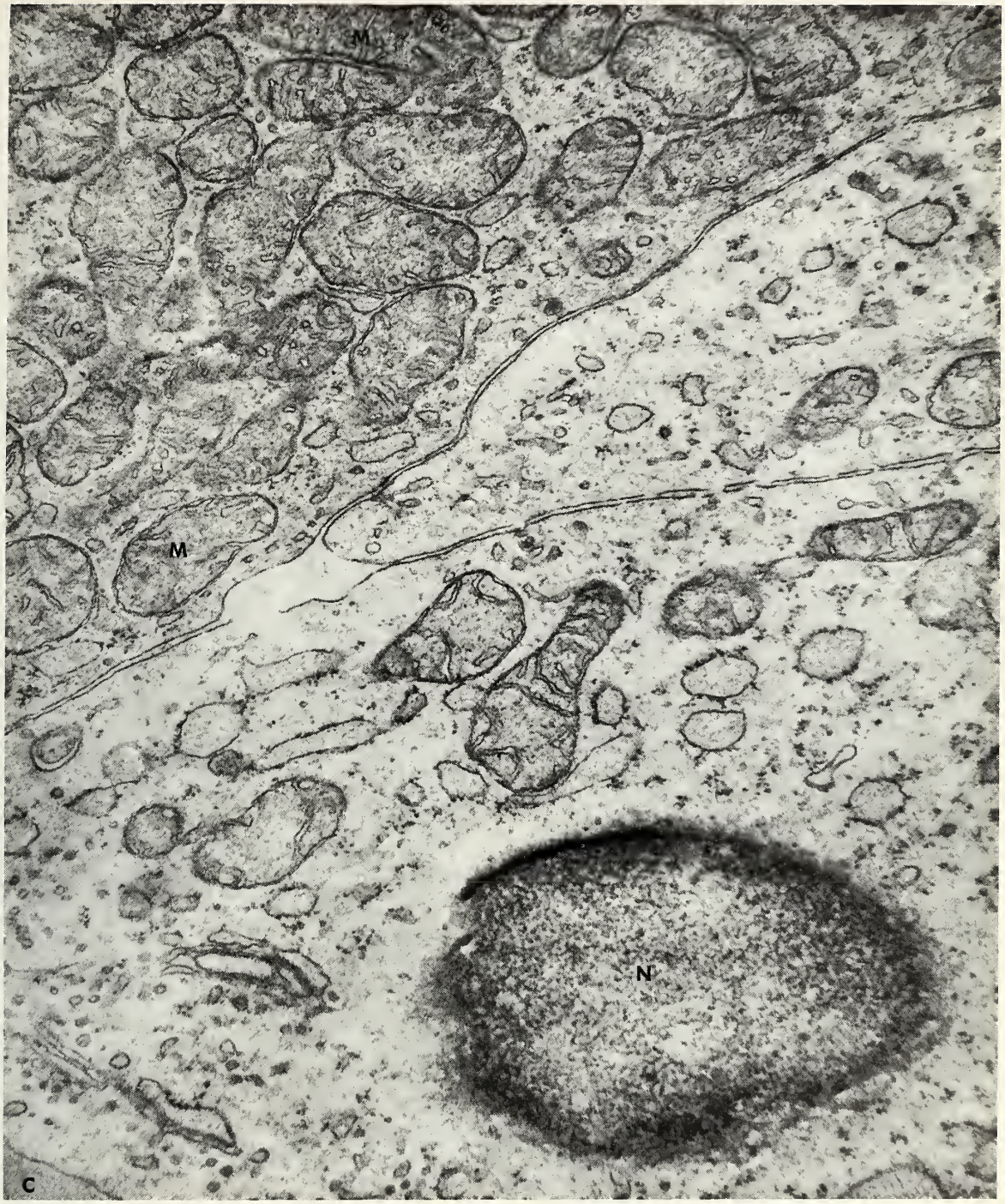


NORMAL THYROID

Figure 5. This electron micrograph shows a normal follicle cell in the lower right half of the field and an oxyphilic cell in the upper left half of the field. Note the numerous mitochondria in the cytoplasm of the oxyphilic cell. The following structures are identified: C, colloid; M, mitochondria; N, nucleus. × 34,000. (Courtesy of the Armed Forces Institute of Pathology.) A.F.I.P. Atlas No. 67-3-5.

In various pathologic conditions of the thyroid gland, and occasionally in otherwise normal glands, there are follicular cells differing from the usual in that they are larger and have granular, acidophilic cytoplasm. Such cells may have bizarre hyperchromatic nuclei and tend to form small follicles or compact groups (fig. 6). These cells described by Askanazy have been called Askanazy cells, eosinophilic cells, acidophils, oncocytes, oxyphils, or Hürthle cells. The cell Hürthle actually described was a parafollicular cell in the thyroid of a puppy. Since these cells are usually found associated with various pathologic states of the thyroid, it has been assumed they represent either degenerated or exhausted follicular cells. Recently, however, studies by Pearse, Tremblay, and others have shown that they contain an abundance of both actively functioning mitochondria and oxidative enzyme systems (figs. 7–11), which suggest they are metaplastic or even hyperplastic variants of the follicular cell. The unusually large number of mitochondria at times almost fills the cytoplasm (fig. 5). In addition, many of the mitochondria may display morphologic alterations. It should be emphasized that they are not a separate type of epithelial cell, but merely a variant of the follicular cell. The abundance and abnormalities of the mitochondria, plus the pattern of enzyme systems, relate these cells functionally to acidophilic cells of the parathyroid glands, salivary glands, and elsewhere (Roth et al.); Hamperl has suggested the term oncocyte to encompass all such cells.

Interfollicular cells (figs. 12, 13) are quite apparent in the thyroid glands of many animals (Young and Leblond; Klinck, 1967). The parafollicular cell, also called the "C cell" or the "light cell" because its cytoplasm is lighter than that of the follicular cell, is said to be the source of thyrocalcitonin. Such parafollicular cells have not as yet been conclusively demonstrated in the human thyroid.

The colloid of the thyroid follicle consists essentially of thyroglobulin, a glycoprotein, and stains well with the PAS reaction. Klinck (1963) has shown that, in contrast to the parathyroid, thyroid cells contain very little glycogen. It should be noted, however, that some thyroid adenomas and a considerable number of thyroid carcinomas do contain glycogen in variable amounts, so that the presence or absence of glycogen in

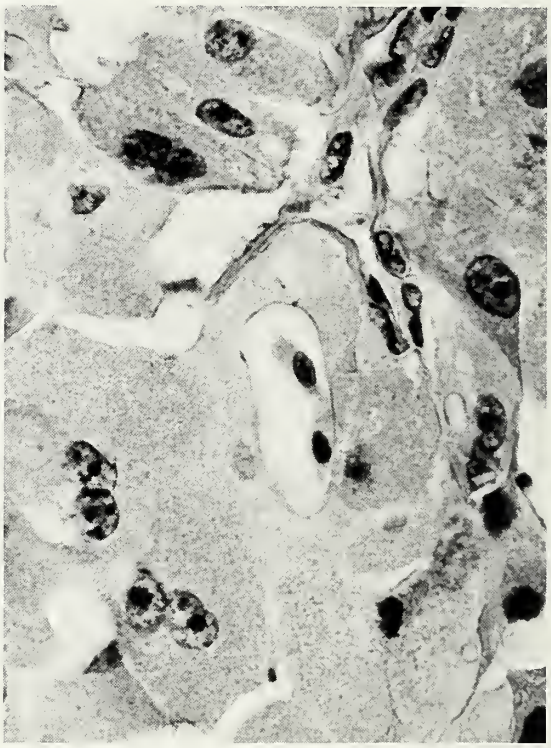

OXYPHILIC CELLS

Figure 6. The photomicrograph of oxyphilic cells reveals granular cytoplasm caused by the numerous mitochondria (see figure 5). × 600. A.F.I.P. Atlas No. 67-3-7.

a thyroid tumor is of little diagnostic assistance. Since, at times, the colloid may stain irregularly with mucicarmine, the possibility exists that carminophilic material might also appear in the cells of a thyroid carcinoma. In general, histochemical technics have not been of much value in the surgical pathology of thyroid tumors.

Alkaline phosphatase activity in the thyroid is largely related to the endothelium of the perifollicular capillary. Acid phosphatase, however, is present in some follicular cells. Oxidative enzymes, such as adenosine triphosphatase (ATPase), succinic dehydrogenase, and cytochrome oxidase, are particularly prominent in hyperplastic cells and in oncocytes (figs. 7–11) (Tremblay, 1960).

Droplets of lipid are rather common in the thyroid epithelium. The presence of iodine in thyroid cells and in colloid is best demonstrated by autoradiography.

## DEVELOPMENT

The thyroid gland takes its origin from a single downgrowth of entoderm from the pharyngeal floor. At first a hollow tube, the downgrowth soon becomes solid as it migrates caudally, and normally the lumen is obliterated by the sixth embryonic week. The proximal end is represented by a vestige of the original opening of the duct, the foramen cecum of the tongue. The distal end terminates in the pyramidal lobe of the thyroid and forms most, if not all, of the functioning thyroid tissue in man. Remnants of the thyroglossal duct may persist at any point along its course, giving rise to ectopic thyroid tissue, cysts, or sinuses.

Although in some mammals the ultimobranchial bodies, derivatives of the fourth branchial pouch, contribute to the formation of the definitive thyroid, there is little evidence that such takes place in man. The ultimo-branchial bodies in man disappear completely, although the possibility of their occasional persistence helps explain certain cysts and anomalies.

## PHYSIOLOGY

The physiologic activity of the follicular epithelium is maintained by the thyrotropic hormone (TSH) of the anterior pituitary. With increased amounts of thyroxin ($T_4$), TSH is decreased and the thyroid gland becomes less active. Since some thyroid tumors are hormonally dependent on TSH, thyroxin is usually administered therapeutically to patients with thyroid tumors in the hope that with suppression of TSH the tumor may grow more slowly. With a deficiency of the thyroid hormone, TSH increases and stimulates the thyroid to become hyperplastic. Many tumor-like lesions of the thyroid are due to acute or chronic deficiencies of the thyroid hormone and the resultant hyperplasia and hypertrophy of the gland. Some thyroid tumors may actually be stimulated to greater activity with TSH therapy, a principle which may be useful in bringing about a greater uptake of radioiodine by the tumor.

The follicular cells perform many functions. They form colloid which is essentially thyroglobulin. The cells trap and incorporate iodide into the thyroglobulin, and by secreting various oxidative enzymes bring about the iodination of tyrosine to transform it into the thyroid hormone. The same cells also elaborate a proteolytic enzyme that breaks the thyroglobulin-thyroxin bond so that thyroxin may be released and transported to the tissues. Since it has been demonstrated by autoradiography that various constituents of thyroglobulin as well as iodine are taken up by each cell of the

## ENZYME REACTIONS OF FOLLICULAR EPITHELIUM

Figure 7. Cytochrome oxidase activity is shown in a hyperplastic goiter. A cluster of follicles lined by oxyphilic cells reacts strongly. Some of the hyperplastic follicular cells are moderately active, but less so than the oxyphils. × 140. A.F.I.P. Atlas No. 67-3–9.

Figure 8. Cytochrome oxidase activity in an adenomatous goiter indicates an intense reaction of the oxyphilic cells. × 220. A.F.I.P. Atlas No. 67-3–10.

Figure 9. Succinic dehydrogenase activity in an adenomatous goiter shows the oxyphilic cells reacting strongly; normal follicular cells are reacting weakly. × 90. A.F.I.P. Atlas No. 67-3–11.

Figure 10. Succinic dehydrogenase activity in an adenomatous goiter shows the follicles, lined by oxyphilic cells, producing a stronger reaction than those lined with normal follicular epithelium. × 90. A.F.I.P. Atlas No. 67-3–12.

Figure 11. Adenosine triphosphatase (ATPase) activity is shown in a section adjacent to figure 10. The oxyphilic cells and blood vessel walls show an intense reaction. × 90. A.F.I.P. Atlas No. 67-3–13.

Note: Figures 7 through 11 represent photomicrographs of enzyme reactions. Although the normal or hyperplastic follicular epithelium sometimes shows the enzyme, the oxyphilic cells show a much higher enzyme content. (All photographs are the courtesy of Dr. Gilles Tremblay, Montreal, Canada, from "The Oncocytes" to be published in Vol. 4, 1968, of "Methods and Achievements in Experimental Pathology.")

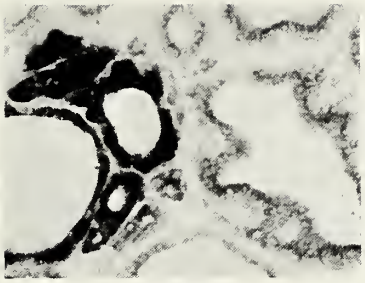

Fig. 7



Fig. 8

Fig. 9

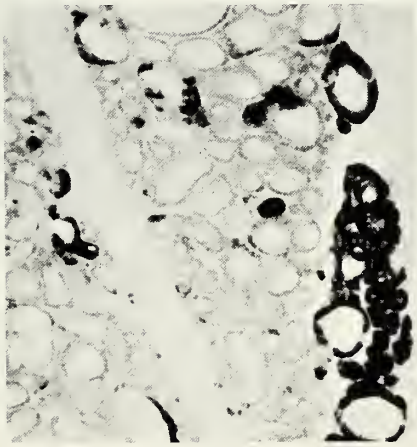

Fig. 10

Fig. 11

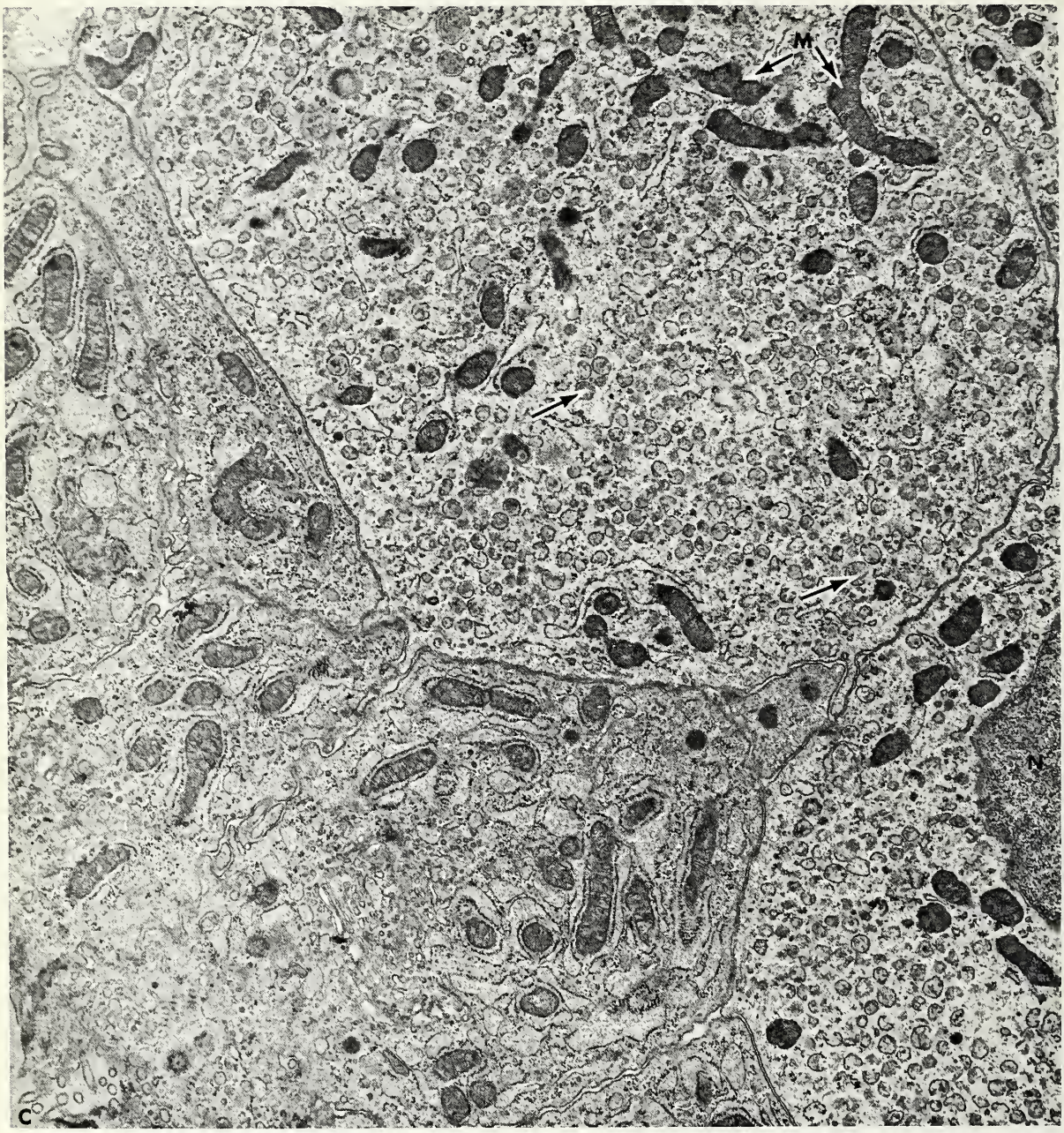


PARAFOLLICULAR CELLS

Figure 12. This electron micrograph depicts the thyroid gland from a puppy. Three parafollicular (light) cells in the center and to the right of the field are surrounded by normal follicular cells. The parafollicular cells contain numerous granules (arrows) that are thought to be the source of thyrocalcitonin. According to some sources (Braunstein et al.; Gonzalez-Licea et al.; Meyer and Abdel-Bari; Williams), these cells give rise to medullary carcinomas. The following structures are identified: C, colloid; M, mitochondria; N, nucleus. × 12,000. (Courtesy of the Armed Forces Institute of Pathology.) A.F.I.P. Atlas No. 67-3-6.

follicle, it appears that all follicular cells perform the same functions. Histochemistry and electron microscope autoradiography have been used intensively to study synthesis and secretion of thyroglobulin and thyroxin as summarized by Doniach.

The homeostatic mechanisms as well as the formation and secretion of thyroxin are obviously complicated. It is not surprising, therefore, that many conditions and states may interfere with one or more phases of the complex function of the thyroid.

In addition to thyroxin, evidence is now available that a hormone which lowers plasma calcium and phosphorus levels is secreted by the thyroid gland. It has been named "thyrocalcitonin" by Hirsch and associates. While most of the studies on thyrocalcitonin have been in animals, it has been shown that man is sensitive to the action of the hormone and presumably it is secreted by the human thyroid. While in animals the thyrocalcitonin apparently is produced by the parafollicular cells, the exact site and origin of the hormone in the thyroid of man is still to be determined.

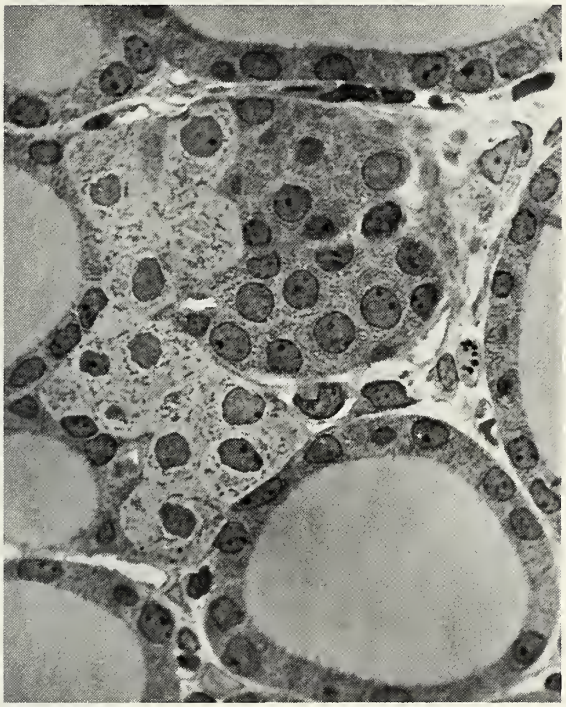

PARAFOLLICULAR CELLS

Figure 13. Parafollicular (light) cells in the thyroid gland of a puppy are seen at the left of center. Darker cells represent normal follicular epithelium. A tangential section of a follicle shows an interfollicular mass of follicular cells. × 600. A.F.I.P. Atlas No. 67-3-8.

## References


Braunstein, H., Stephens, C. L., and Gibson, R. L. Secretory granules in medullary carcinoma of the thyroid. Arch. Path. 85:306–313, 1968.

Doniach, I. The structure of the thyroid gland. In: McGowan, G. K., and Sandler, M. Symposium on the Thyroid Gland. J. Clin. Path. 20 (Suppl. 1): 309–317, 1967.

Gonzalez-Licea, A., Hartmann, W. H., and Yardley, J. H. Medullary carcinoma of the thyroid. Ultrastructural evidence of its origin from the parafollicular cell and its possible relation to carcinoid tumors. Amer. J. Clin. Path. 49:512–520, 1968.

Hamperl, H. Onkocytes and the so-called Hürthle cell tumor. Arch. Path. 49:563–567, 1950.

Heimann, P. Ultrastructure of human thyroid. A study of normal thyroid, untreated and treated diffuse toxic goiter. Acta Endocr. 53 (Suppl. 110): 1–102, 1966.

Hirsch, P. F., Gauthier, G. F., and Munson, P. L. Thyroid hypocalcemic principle and recurrent laryngeal nerve injury as factors affecting the response to parathyroidectomy in rats. Endocrinology 73:244–252, 1963.

Kay, C., Abrahams, S., and McClain, P. The weight of normal thyroid glands in children. Arch. Path. 82:349–352, 1966.

Klinck, G. H. Glycogen in thyroid and parathyroid tumors. In: Sunderman, F. W., and Sunderman, F. W., Jr. Evaluation of Thyroid and Parathyroid Functions, pp. 122–123. Philadelphia: J. B. Lippincott Company, 1963.

———. Interfollicular cells of the thyroid. Presidential Address to the American Thyroid Association, 1967. (To be published)

———. Structure of the thyroid. In: Hazard, J. B., and Smith, D. E. The Thyroid, pp. 1–31. Baltimore: The Williams & Wilkins Company, 1964.

Meyer, J. S., and Abdel-Bari, W. Granules and thyrocalcitonin-like activity in medullary carcinoma of the thyroid gland. New Eng. J. Med. 278:530–533, 1968.

Mochizuki, Y., Mowafy, R., and Pasternack, B. Weights of human thyroids in New York City. Health Phys. 9: 1299–1301, 1963.

Mortensen, J. D., Woolner, L. B., and Bennett, W. A. Gross and microscopic findings in clinically normal thyroid glands. J. Clin. Endocr. 15:1270–1280, 1955.

Roth, S. I., Olen, E., and Hansen, L. S. The eosinophilic cells of the parathyroid (oxyphil cells), salivary (oncocytes) and thyroid (Hürthle cells) glands. Light and electron microscopic observations. Lab. Invest. 11: 933–941, 1962.

Russfield, A. B. Histology of the human hypophysis in thyroid disease—hypothyroidism, hyperthyroidism, and cancer. J. Clin. Endocr. 15:1393–1408, 1955.

Thomas, C. G., Jr. The dependency of thyroid cancer. A review. Ann. Surg. 146:879–891, 1957.

Tonietti, G., Baschieri, L., and Salabe, G. Papillary and microfollicular carcinoma of human thyroid. An ultrastructural study. Arch. Path. 84:601–614, 1967.

Tremblay, G. Oncocytes, a review. (To be published in Vol. 4, 1968, of Methods and Achievements in Experimental Pathology.)

———, and Pearse, A. G. Histochemistry of oxidative enzyme systems in the human thyroid, with special reference to Askanazy cells. J. Path. Bact. 80: 353–358, 1960.

Valenta, L., and Jirasek, J. E. Histochemistry of thyroid tumors. Significance of two enzymes and PAS-positive materials. Arch. Path. 84:215–223, 1967.

Williams, E. D. Histogenesis of medullary carcinoma of the thyroid. J. Clin. Path. 19:114–118, 1966.

Young, B. A., and Leblond, C. P. The light cell as compared to the follicular cell in the thyroid gland of the rat. Endocrinology 73:669–686, 1963.

## TUMOR-LIKE LESIONS

### ANOMALOUS AND ECTOPIC THYROID TISSUE

(Figures 14–19)

There is so much variation in the size and configuration of the thyroid gland that it is often difficult to decide what to describe as an anomaly and what to accept as normal. Among the common variations in configuration that may be mistaken for tumor are the following: asymmetry, particularly when the right lobe is larger than the left; widening of the isthmus; and presence of a pyramidal lobe.

As might be expected, ectopic thyroid tissue is most commonly found along the course of the thyroglossal duct tract and about the two main lobes of the gland. Small nodules of the thyroid tissue about the main gland are quite common. Sublingual thyroid (fig. 14) centered about the foramen cecum may be the only thyroid tissue present in the individual. A few cases of ectopic thyroid masses, either subhyoid (Grieve), intratracheal (Cooper), intralaryngeal, or intraesophageal (Fish and Moore), have been reported. Since the primitive heart slips caudally past the primitive thyroid, remnants of thyroid anlage may be displaced into the mediastinum (fig. 15) to the aortic arch, pericardium, and diaphragm. In one instance,

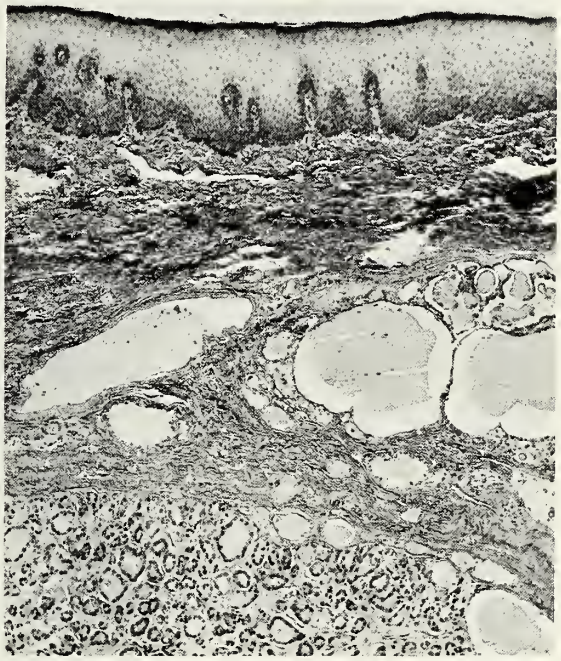

SUBLINGUAL THYROID

Figure 14. Eight gm. of thyroid tissue, showing changes of adenomatous goiter, were removed from the posterior portion of the tongue of a 28-year-old woman. The thyroid tissue lies beneath the lingual stratified squamous epithelium. × 50. A.F.I.P. Atlas No. 67-3–16.

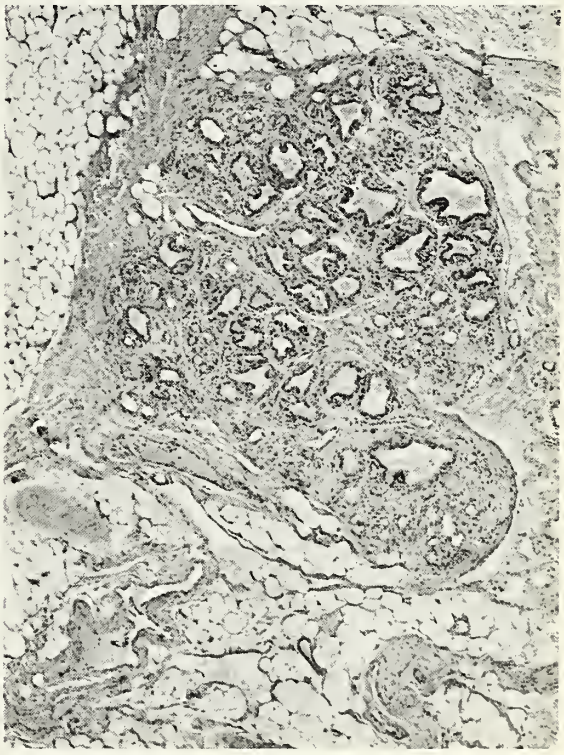

ECTOPIC THYROID FOLLICLES IN FAT

Figure 15. This photomicrograph shows a small cluster of non-neoplastic aberrant thyroid follicles in mediastinal fat. × 50. A.F.I.P. Atlas No. 67-3–18.

normal thyroid tissue was found adjacent to the common bile duct. Ectopic thyroid tissue in the various locations is usually an incidental microscopic finding; only rarely does it reach a sufficient size to become palpable or grossly visible, thus confusing it clinically with tumor. True neoplasms arising from ectopic thyroid tissue are quite uncommon and are discussed on page 127.

In the embryo there is an intimate relationship between the primitive thyroid and adjacent striated muscle (Gardiner). Although the thyroid lobes are covered with a capsule, small nests of thyroid tissue in the adjacent muscle and soft tissues (fig. 16) are frequent and are particularly prominent when the thyroid is hyperplastic, as in Graves' disease. Sometimes striated muscle is included within the thyroid gland itself (fig. 17).

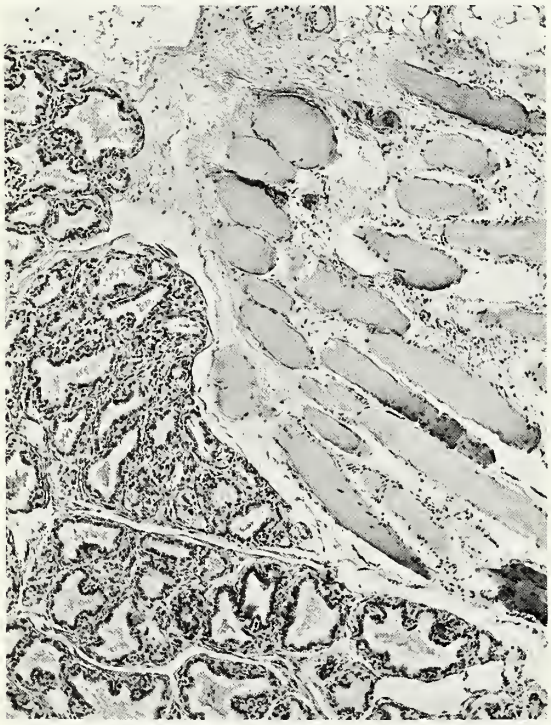

THYROID IN MUSCLE

Figure 16. Extension of slightly hyperplastic thyroid tissue through the capsule into striated muscle is revealed. Small extensions such as these are rather common, especially in hyperplastic goiter. × 50. A.F.I.P. Atlas No. 67-3-14.

STRIATED MUSCLE IN THYROID

Figure 17. Inclusion of striated muscle within the thyroid is probably congenital and the result of the intimate relationship of primitive thyroid and muscle. The thyroid showed a mild nonspecific chronic thyroiditis. × 50. A.F.I.P. Atlas No. 67-3-15.

Histologically, normal thyroid follicles are found occasionally in lateral cervical lymph nodes as incidental findings (fig. 18) (Roth; Nicastri et al.; Block et al.). The follicles lie in or near the sinus of the nodes or even outside the node capsule. The clusters of follicles are small—often only 10 or 20 follicles—so that they are rarely visible grossly and do not cause palpable enlargement of the node involved. A sufficient number of instances of such ectopic follicles have been studied to conclude that they are non-neoplastic. It is probable that they represent a lymphatic transport of benign

ECTOPIC THYROID FOLLICLES IN LYMPH NODE

Figure 18. This small cluster of benign thyroid follicles in the periphery of a lymph node was removed from the lateral area of the neck. This was an incidental finding in the autopsy of a 48-year-old man who died from a myocardial infarction. No tumor of the thyroid gland was found after careful examination. × 100. A.F.I.P. Atlas No. 67-3-17.

thyroid tissue according to the theory of "benign metastasis." It is unlikely that they may represent remnants of the ultimobranchial bodies. It is important to emphasize that the rests are very small, nonpapillary, and morphologically not suggestive of neoplasia. If the mass of thyroid tissue in a lateral cervical lymph node is large, papillary, or histologically neoplastic, it must be assumed to represent a metastasis from a carcinoma of the main gland.

**Struma ovarii** (fig. 19) is not a developmental anomaly of the thyroid, but rather represents an ovarian teratoma with an accent on the formation of thyroid tissue. Similar thyroid tissue is occasionally found in teratomas of other organs of the body. Struma ovarii is said to contribute to or to produce thyrotoxicosis occasionally. Tumors arising in struma ovarii are discussed under tumors of ectopic thyroid tissue on page 127.

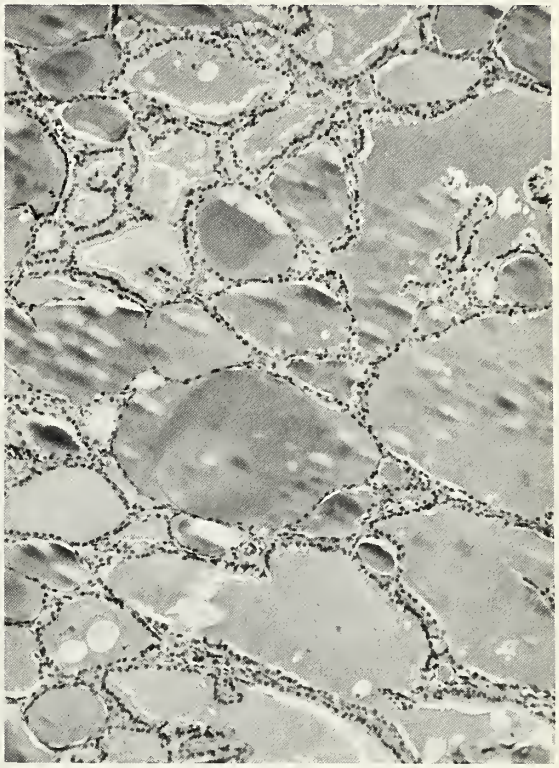

STRUMA OVARII

Figure 19. In this case of struma ovarii, each ovary in this patient was largely replaced by masses of fairly normal appearing thyroid tissue. Although the thyroid tissue appears benign histologically, there was seeding of the tumor in the peritoneum (see figure 131). × 100. A.F.I.P. Atlas No. 67-3-19.

## References

Block, M. A., Wylie, J. H., Patton, R. B., and Miller, J. M. Does benign thyroid tissue occur in the lateral part of the neck? Amer. J. Surg. 112:476–481, 1966.

Cooper, T. V. A case of aberrant thyroid tissue in the trachea. J. Clin. Path. 3:48–50, 1950.

Fish, J., and Moore, R. M. Ectopic thyroid tissue and ectopic thyroid carcinoma: A review of the literature and report of a case. Ann. Surg. 157:212–222, 1963.

Gardiner, W. R. Unusual relationships between thyroid gland and skeletal muscle in infants. A review of the literature and four case reports. Cancer 9:681–691, 1956.

Gricouroff, G. La thyroïdose métastatique bénigne et ses tumeurs. Bull. Ass. Franc. Cancer 49:300–311, 1962.

———. The problem of lateral aberrant thyroids. Its interpretations, pp. 29–34. In: Tumors of the Thyroid Gland. Appaix, A. (ed.) New York: American Elsevier Publishing Company, Inc., 1966.

Grieve, J. A subhyoid median ectopic thyroid. Arch. Dis. Child. 34:18–19, 1959.

Klopp, C. T., and Kirson, S. M. Therapeutic problems with ectopic non-cancerous follicular thyroid tissue in the neck: 18 case reports according to etiologic factors. Ann. Surg. 163:653–664, 1966.

Long, R. T., Evans, A. M., and Beggs, J. H. Surgical management of ectopic thyroid: Report of a case with simultaneous lingual and subhyoid median ectopic thyroid. Ann. Surg. 160:824–827, 1964.

Nicastri, A. D., Foote, F. W., Jr., and Frazell, E. L. Benign thyroid inclusions in cervical lymph nodes. J.A.M.A. 194:113–116, 1965.

Roth, L. M. Inclusions of non-neoplastic thyroid tissue within cervical lymph nodes. Cancer 18:105–111, 1965.

**A thyroglossal duct cyst** (fig. 20) is a non-neoplastic cyst arising from the remnants of the embryonic thyroglossal duct.

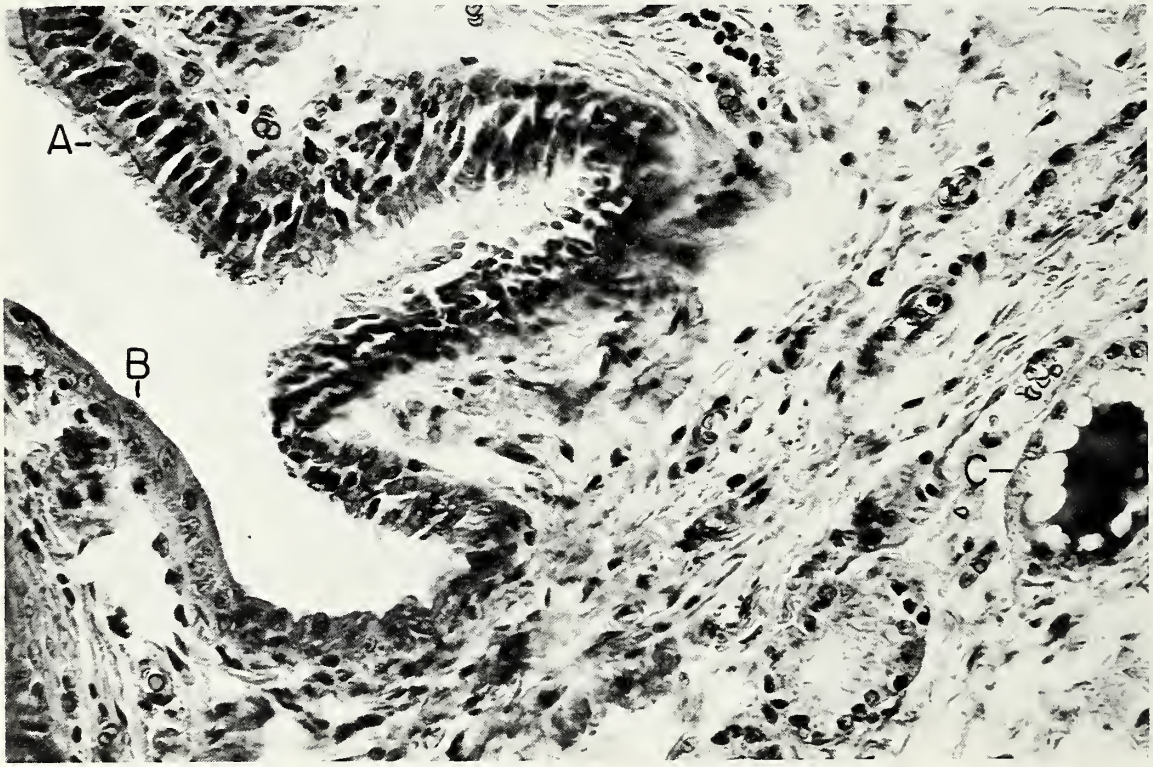


THYROGLOSSAL DUCT CYST

Figure 20. This typical thyroglossal duct cyst shows the following: A, ciliated epithelium; B, stratified squamous epithelium; and C, thyroid tissue in the wall. × 350. A.F.I.P. Acc. No. 219764–3.

GROSS. These cystic masses are found in or near the midline of the neck, usually just below the level of the hyoid bone. Their average diameter is 1 to 2 cm., but occasionally much larger cysts develop. Keynes reported a cyst which had been growing for 20 years and reached the size of the patient's head. An uncomplicated cyst is thin-walled; with infection, fibrotic thickening of the wall is the rule. Ordinarily the cysts are filled with clear, mucinous fluid, but occasionally the contents are pasty and similar to those in a wen; with infection, the contents are purulent.

MICROSCOPIC. Usually the epithelium lining the cysts is simple columnar form, but often it is ciliated and may be transitional, squamous, or mixed. A case reported by Iswariah and Froome had a lining similar to the mucosa of the small intestine. With degenerative or inflammatory changes, which are frequent, the epithelium may be destroyed and replaced by a thick layer of fibrous tissue. There may be cholesterol crystals in the cyst. Small collections of histologically normal thyroid tissue are frequent in the cyst wall, but accumulations of lymphocytes like those seen in branchial cleft cysts do not occur.

NATURAL HISTORY. About one third of the cysts seen in children were present at birth; however, remnants of the thyroglossal duct may persist for years before becoming cystic by draining into the oral cavity through the foramen cecum until the persistent duct is obstructed by infection. In adults, half the cases have a history of inflammation of the cyst.

DIFFERENTIAL DIAGNOSIS. Thyroglossal duct cysts may be confused clinically with enlarged lymph nodes, branchial cleft or sebaceous cysts or lipomas. Occasionally, they may be confused with prominence or neoplasms of the pyramidal lobe of the thyroid. Upward movement of the mass on swallowing is characteristic of thyroglossal duct cyst.

TREATMENT. Gross and Connerley believe no treatment is necessary in children if the cyst is small and there is no disfigurement or inflammation. Otherwise the accepted treatment is surgery, with careful radical excision of the entire tract, including partial removal of the hyoid bone.

### References

Gross, R. E., and Connerley, M. L. Thyroglossal cysts and sinuses; a study and report of 198 cases. New Eng. J. Med. 223:616–624, 1940.

Iswariah, J. D., and Froome, K. An unusual thyroglossal cyst. Brit. J. Surg. 49:597, 1962.

Keynes, G. A large thyroglossal cyst. Brit. J. Surg. 47:447–449, 1960.

Pollock, W. F., and Stevenson, E. O. Cysts and sinuses of the thyroglossal duct. Amer. J. Surg. 112:225–232, 1966.

## INTRATHYROIDAL CYSTS

Most cysts of the thyroid represent degeneration of a nodule of adenomatous goiter or, less frequently, of a tumor. Intrathyroidal cysts lined with squamous or columnar epithelium occur occasionally, and may become large enough to present clinically as a nodule. Goldberg and Harvey report instances of small benign cysts lined entirely by squamous epithelium, and postulate that their origin may be from metaplasia, thyroglossal duct remnants, remnants of the fourth branchial pouch complex, or from remnants of the ultimo-branchial body. Dermoid cysts are rare (Noteboom and Everts-Suarez).

### References

Goldberg, H. M., and Harvey, P. Squamous-cell cysts of thyroid with special reference to aetiology of squamous epithelium in human thyroid. Brit. J. Surg. 43:565–569, 1956.

Noteboom, G., and Everts-Suarez, E. A. Dermoid cyst of thyroid gland in an adult. U. S. Armed Forces M. J. 10:722–726, 1959.

**ADENOMATOUS GOITER** (Figures 21–29; plate I–A)

SYNONYMS AND RELATED TERMS: Nontoxic nodular goiter; endemic goiter; adenomatoid goiter; multiple colloid adenomatous goiter; nodular hyperplasia. The following related terms are used sometimes as synonyms, but more correctly designate earlier stages in development: congenital goiter; nontoxic hyperplasia; colloid goiter; simple goiter.

DEFINITION. Enlargement, eventually nodular, of the thyroid due to repeated or continuous hyperplasia, usually in response to a deficiency of thyroid hormone.

GROSS. The gross appearance varies considerably with the stage of the development of the goiter. In the earlier stages when the changes are predominantly hyperplastic, the gland is symmetrically enlarged, smooth, and non-nodular. When hyperplasia is extreme, the gland may be many times its normal weight. With further development of the lesion, there is excessive accumulation of colloid and the gland, still non-nodular, is enlarged and shows a glistening cut surface due to the colloid. The later stages in the development of the process show numerous nodules which are glossy, translucent brown or tan, and scattered throughout the entire gland (figs. 21, 22). The nodules vary from less than a millimeter to several centimeters in diameter. Some are poorly circumscribed; others are well demarcated, but do not have a true capsule.

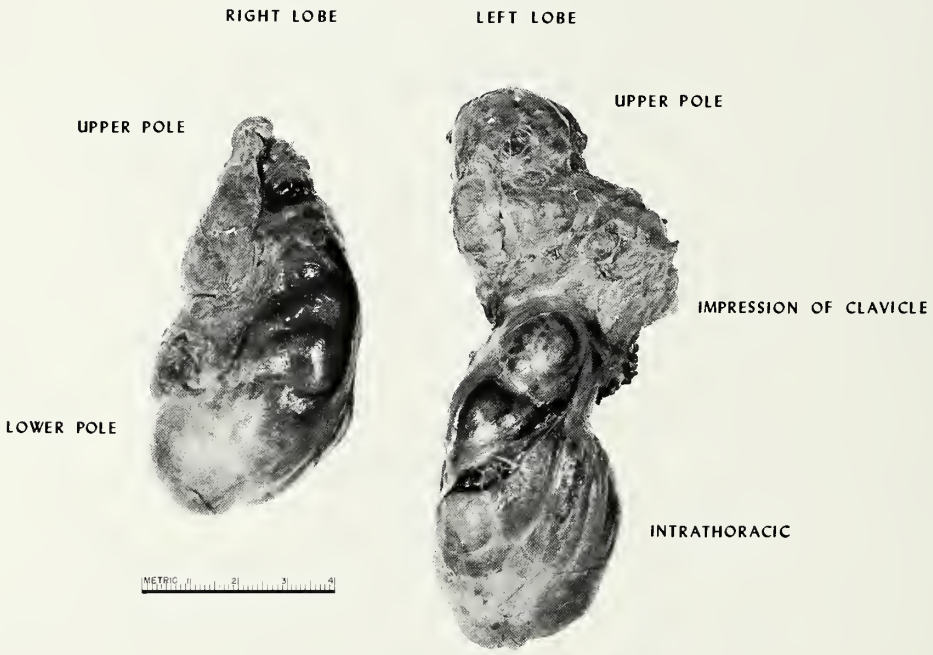


ADENOMATOUS GOITER

Figure 21. This adenomatous goiter shows intrathoracic extension and characteristic bilateral nodularity. Asymmetrical enlargement is frequent. (This is reproduced in part from figure 7 in Lahey, F. H. Intrathoracic goiter. J.A.M.A. 113:1098–1105, 1939.) A.F.I.P. Acc. No. 219764–4.

Fig. 22

ADENOMATOUS GOITER

Figure 22. The cut surface of an adenomatous goiter contains numerous typical, poorly circumscribed nodules of varying sizes. A.F.I.P. Acc. No. 219764–5.

Although the process involves all portions of the gland, one nodule is often much larger or more prominent than the others (pl. I–A). Retrogressive changes in the nodules are extremely common—cyst formation (fig. 23), softening, old and recent hemorrhage, and calcification (fig. 24). In its later stages, adenomatous goiter may reach a tremendous size; the largest personally seen weighed over 2,000 gm. Occasionally changes of adenomatous goiter may be found in a gland within the normal weight range; this makes the term goiter, or enlarged thyroid, inappropriate.

ADENOMATOUS GOITER

Figure 23. This adenomatous goiter in a more advanced stage shows the cyst formation and fibrosis which are common complications. Hemorrhage into such cysts may cause a sudden increase in size. A.F.I.P. Acc. No. 219764–6.

ADENOMATOUS GOITER

Figure 24. The roentgenogram shows the lateral view of a large adenomatous goiter with central calcification secondary to retrogressive changes. A.F.I.P. Acc. No. 219764–7.

MICROSCOPIC. The microscopic appearance varies with the stage of development of the process. In the earlier stages there is hyperplasia which may vary from a degree that is scarcely discernible to one that is intense (figs. 25, 26), with every cell in the gland participating. As the process continues, some follicles become overdistended with colloid, and the epithelium is only focally hyperplastic. In the well developed stage, many follicles are so distended with colloid that they measure 250 micra or more in diameter (fig. 27). Other follicles may be small and devoid of colloid. The gross nodules are surprisingly indistinct microscopically with poor demarcation from the adjacent glands. Fibrosis of stroma, varying from small scattered foci to large scars, and retrogressive changes, such as hemorrhage and necrosis, give the gland a variegated appearance (fig. 28).

ETIOLOGY AND HISTOGENESIS. With a deficient output of thyroid hormone, the thyroid gland is stimulated by TSH to become more active, and the hyperplasia continues as long as there is excessive stimulation or until the thyroid epithelium, perhaps through exhaustion, ceases to hyperfunction.

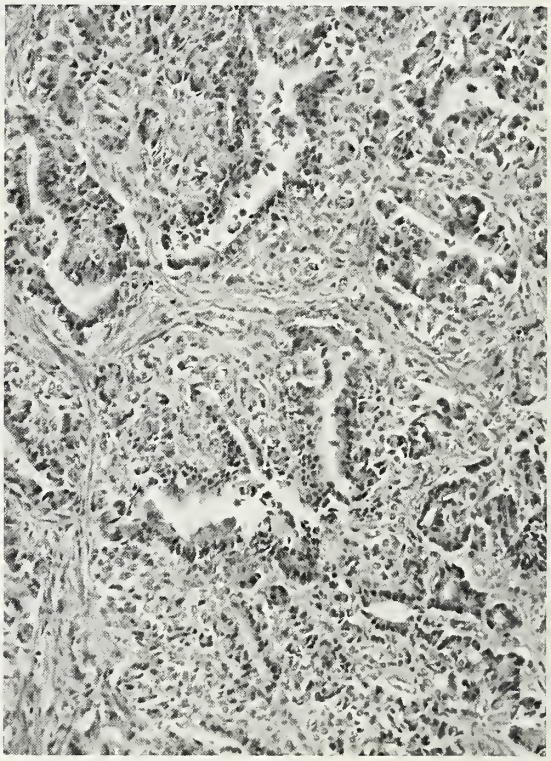

CONGENITAL GOITER

(Figures 25 and 26 are from the same case)

Figure 25. This illustrates extreme hyperplasia of the thyroid in a congenital goiter of an infant. × 125. A.F.I.P. Atlas No. 67-3-20.

The compensatory hyperplasia in most instances is adequate to maintain the patient in a euthyroid condition. There are numerous causes for deficient output of thyroid hormone; the most common is due to insufficient iodine in food or drinking water (endemic goiter). Other causes include inborn errors of thyroid metabolism and either dietary or chemical goitrogens.

The pathologic changes depend on the severity and chronicity of the hyperactivity of the gland. When need for compensatory hyperactivity is extreme, the gland may become intensely hyperplastic and may be confused with carcinoma. Such a state might be brought about, for example, by a combination of an inborn error of metabolism and a dietary goitrogen. Such severe hyperplasia is more likely to be seen in infants (Lincoln) than in adults (Bell and Eisenbeis); death from asphyxiation may result from enlargement of the gland.

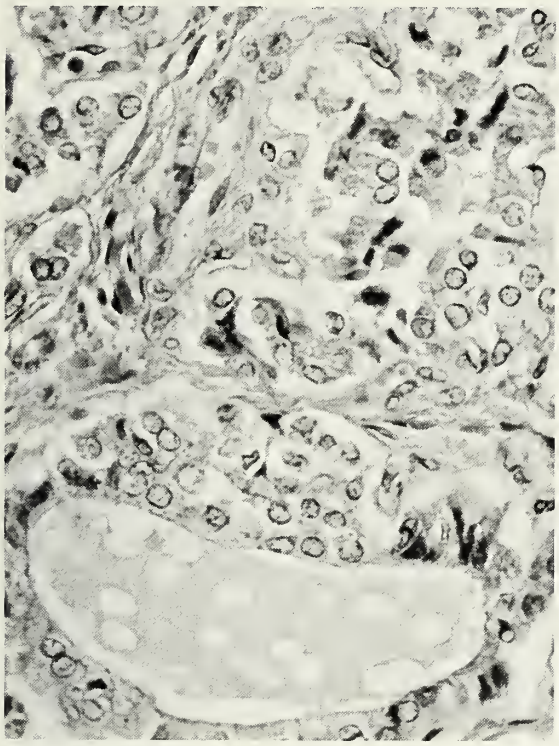

CONGENITAL GOITER

(Figures 25 and 26 are from the same case)

Figure 26. This higher magnification of a congenital goiter reveals the intense hyperplasia which may be confused with cancer. × 400. A.F.I.P. Atlas No. 67-3-21.

Usually the compensatory hyperplasia from a diminished output of thyroid hormone is low grade and chronic, as in the typical endemic goiter. In such an event there is gradual progression from a mild hyperplastic state, which is often focal, to an excessive accumulation of colloid. In this stage the gland is often called colloid goiter, since nodularity has not yet developed and the hyperplasia is relatively inconspicuous. As the process continues, follicles or groups of follicles become increasingly distended with colloid and various retrogressive changes set in, many of which are on a vascular basis. The end result is a multinodular gland with extensive hemorrhage, fibrosis, infarction, and calcification.

When studied by scintiscan technics, the hyperplasia in adenomatous goiter may be focal or nodular. A hyperactive nodule, as evidenced by excessive iodine uptake, is called "hot"; for a time some hot nodules may be autonomous and suppress the activity of the remainder of the gland. The autonomy and the hyperactivity of the nodule gradually disappear, but then may be taken over by one or several nodules in other parts of the gland. In addition to such autonomous hot nodules, which usually do not produce hyperthyroidism, patients with well developed adenomatous goiter may develop multiple foci of hyperplasia and hyperthyroidism (fig. 29).

Fig. 27

## COLLOID GOITER

Figure 27. Excessive accumulation of colloid and oversized follicles are shown. This stage in the development of adenomatous goiter is often called colloid goiter. × 25. A.F.I.P. Acc. No. 219764–8.

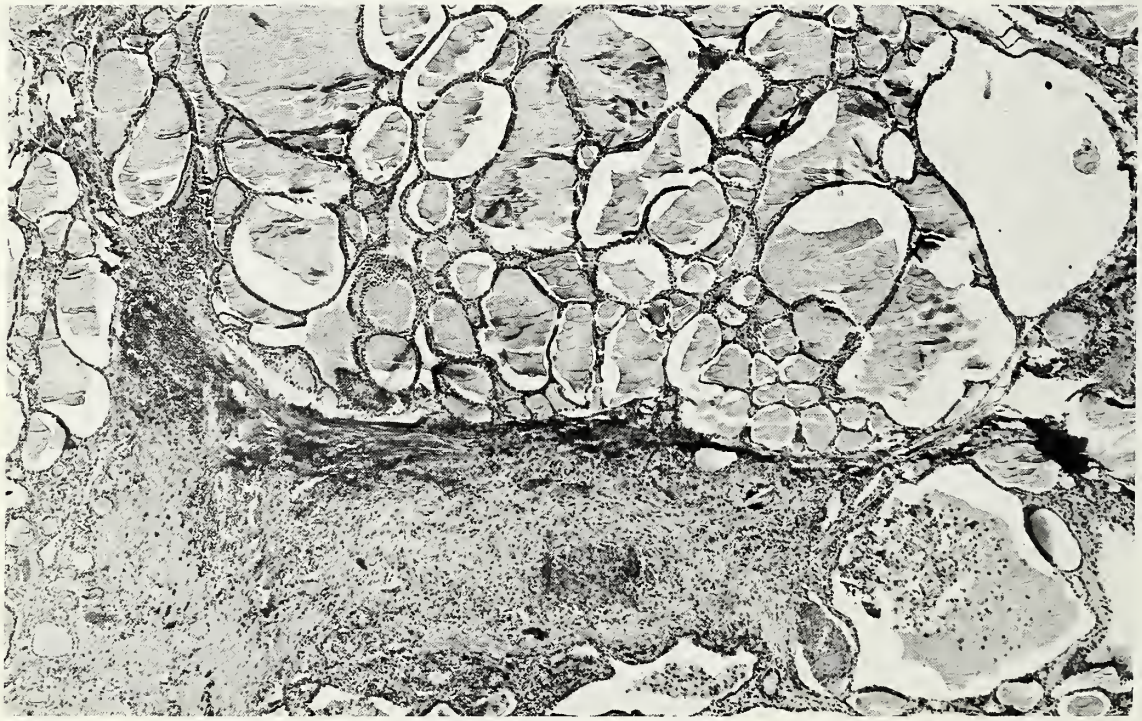

## ADENOMATOUS GOITER

Figure 28. This adenomatous goiter shows considerable variation in follicular size, interfollicular hemorrhage, and focal stromal fibrosis. × 50. A.F.I.P. Acc. No. 219764–9.

ADENOMATOUS GOITER WITH HYPERPLASIA

Figure 29. The numerous hyperplastic papillae of this adenomatous goiter project into the enlarged follicles and may be confused with papillary neoplasia. Secondary follicles in the papillae are more likely to be found in adenomatous goiter than in neoplasia. Compare this with figure 70. × 50. A.F.I.P. Acc. No. 219764–10.

DIFFERENTIAL DIAGNOSIS. Adenomatous goiter is the condition most commonly mistaken for thyroid neoplasm. The hyperplastic stage of development may resemble carcinoma microscopically, but can be distinguished because it is diffuse, whereas carcinoma is nodular or focal. As the name implies, the nodules are easily confused with true adenomas, and differentiation from actual tumor, benign or malignant, may be difficult pathologically as well as clinically. Hyperthyroidism, if present, may help with the clinical diagnosis since well developed adenomatous goiter frequently (and tumor rarely) gives rise to thyroid toxicity. Hot nodules rarely are tumor; cold nodules also may be benign (fig. 30). The comparison presented in Table I on page 50 assists in making the distinction pathologically between adenomatous goiter and adenoma.

TREATMENT. In endemic areas most adenomatous goiters can be prevented by the addition of iodine to water or food. Treatment with thyroxin overcomes the deficiency of thyroid hormone and reduces the overstimulation by TSH. Surgical excision is the accepted treatment if the goiter becomes large enough to be disfiguring or to cause pressure on adjacent structures or if hyperthyroidism results. Surgical removal of adenomatous goiter solely as a prophylactic measure against subsequent development of thyroid cancer seems unwarranted.

COLD NODULE

Figure 30. This scintiscan shows a cold nodule in the left lobe. Although cold solitary nodules create suspicion of tumor, in this instance, the cold nodule was a benign cyst. A.F.I.P. Atlas No. 67-3-22.

## References

Bell, G. O., and Eisenbeis, C. H., Jr. The nontoxic nodular hyperplastic goiter. New Eng. J. Med. 253:812–814, 1955.

Kline, B. S. The origin of adenomatous goitre. Amer. J. Path. 1:235–239, 1925.

Lincoln, A. F. Congenital hyperplasia of thyroid gland: Report of case with necropsy. Amer. J. Clin. Path. 23:1019–1023, 1953.

Louw, J. H. Congenital goitre. A review with a report of three cases of suffocative goitre in the newborn. S. Afr. Med. J. 37:976–983, 1963.

Means, J. H., DeGroot, L. J., and Stanbury, J. B. The Thyroid and Its Diseases, 3d ed. New York, Toronto, London: The Blakiston Division, McGraw-Hill Book Company, Inc., 1963.

Miller, J. M., Horn, R. C., and Block, M. A. The evolution of toxic nodular goiter. Arch. Intern. Med. 113: 72–88, 1964.

Stanbury, J. B. Familial goiter. In: Stanbury, J. B., Wyngaarden, J. B., and Fredrickson, D. S. (eds.) The Metabolic Basis of Inherited Disease, 2d ed., pp. 215–257. New York, Toronto, London: The Blakiston Division, McGraw-Hill Book Company, Inc., 1966.

Studer, H., and Greer, M. A. A study of the mechanisms involved in the production of iodine-deficiency goiter. Acta. Endocr. 49:610–628, 1965.

Taylor, S. Genesis of the thyroid nodule. Brit. Med. Bull. 16:102–105, 1960.

Welch, C. E. Therapy for multinodular goiter. J.A.M.A. 195:339–341, 1966.

**GRAVES' DISEASE** (Figure 31)

SYNONYMS AND RELATED TERMS: Primary hyperplasia; primary hyperthyroidism; exophthalmic goiter.

Graves' disease is characterized by a diffuse hyperplasia of the thyroid associated with clinical hyperthyroidism. In addition, there is often an exophthalmos which may occur independently of the hyperplasia or hyperthyroidism, a lymphocytic infiltrate in the gland, and an enlargement of lymph nodes and the thymus.

The hyperplasia of Graves' disease is diffuse. The gland is enlarged two or three times its usual size and is not nodular. Contrary to the hyperplasia seen in the development of adenomatous goiter, it is not caused by TSH stimulation, but by another substance or substances such as the long-acting thyroid stimulator.

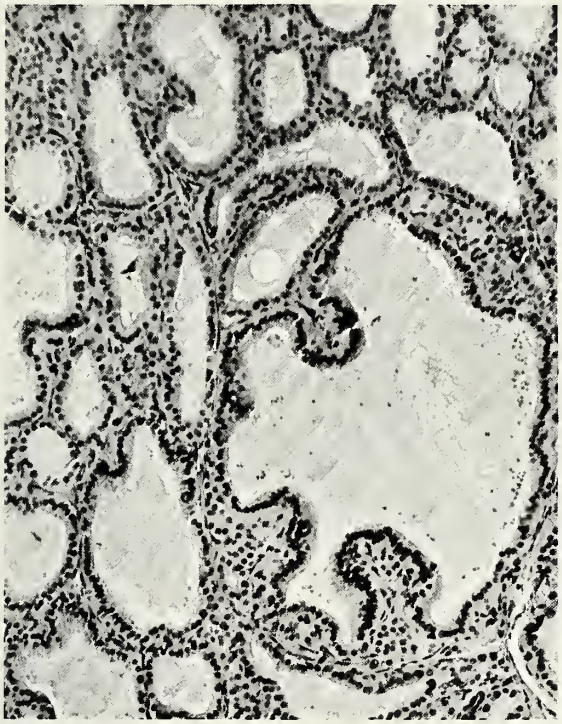

PRIMARY HYPERPLASIA

Graves' Disease

Figure 31. Intrafollicular papillae covered with hyperplastic epithelium are common in thyroid hyperplasias. Compare this case with the cystic papillary carcinoma illustrated in figure 71. × 150. A.F.I.P. Atlas No. 67-3-101.

Since the hyperplastic thyroid gland of Graves' disease is associated with clinical hyperthyroidism, there is rarely confusion of Graves' disease with tumor. However, the intense hyperplasia that occurs in Graves' disease occasionally may mimic carcinoma microscopically (fig. 31). With recurrent attacks, changes of adenomatous goiter develop. Sometimes hyperplastic follicles extend outside the gland itself into the adjacent striated muscle and soft tissues (fig. 16); the extensions may remain after involution has taken place and be mistaken for carcinomatous extension. The possible precancerous nature of the hyperplasia of Graves' disease is discussed on page 60.

### References

Means, J. H., DeGroot, L. J., and Stanbury, J. B. The Thyroid and Its Diseases, 3d ed. New York, Toronto, London: The Blakiston Division, McGraw-Hill Book Company, Inc., 1963.

Werner, S. C. (ed.) The Thyroid. New York: Paul B. Hoeber Inc., Medical Book Dept. of Harper & Bros., 1955.

**THYROIDITIS** (Figures 32–36; plate III–C)

All types of thyroiditis may be mistaken for tumor. Clinical and gross features such as rapid asymmetrical enlargement, nodularity, firmness, and fixation to adjacent structures are common to both inflammation and neoplasm. While the diagnosis usually can be made without difficulty by histologic examination, if adequate material is available, the distinction between thyroiditis and tumor may be difficult or impossible clinically.

**Subacute thyroiditis** (granulomatous thyroiditis; viral thyroiditis; pseudotuberculous thyroiditis; de Quervain's thyroiditis) is a form of thyroiditis commonly confused clinically with tumor (fig. 32). It is thought to be of viral origin. In most instances the disease runs a subacute course of weeks or a few months, although occasionally it runs a more chronic course. Characteristically, only one portion of the gland is involved, producing an asymmetric nodular enlargement. A high sedimentation rate and a low iodine uptake are characteristic. A needle biopsy is an excellent method of confirming a clinical impression. The characteristic microscopic appearance easily distinguishes the process from tumor. Follicular epithelium is destroyed, and foreign body giant cells cluster around degenerated colloid in a pseudotubercle arrangement. The intervening stroma shows fibrosis and inflammatory cells.

**Struma lymphomatosa** (Hashimoto's disease; lymphadenoid goiter) produces symmetric involvement of both lobes without fixation to the perithyroid tissues (figs. 33–35; pl. III–C). The gland has a rubbery consistency and the homogeneous, pale tan cut surface resembles lymphoma. Microscopically the follicles tend to be small and lined with acidophilic epithelium. The stroma contains numerous lymphocytes and plasma cells. Diffuseness of the process with involvement of both lobes and lack of extension beyond the thyroid capsule are helpful in differentiating struma lymphomatosa from cancer. Prominent lymphatic nodules may suggest lymphoma. The rather frequent plasma cells help distinguish the process from lymphosarcoma. Auto-antibody titers are characteristically high in this disease.

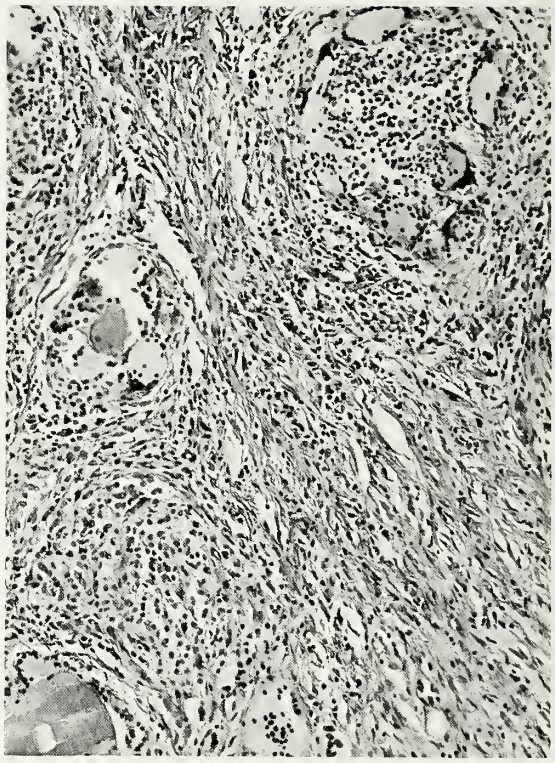

SUBACUTE THYROIDITIS

Figure 32. In this subacute thyroiditis, small granulomas contain inflammatory cells and foreign body giant cells ingesting colloid. Between the granulomas, the thyroid tissue is fibrotic. × 150. A.F.I.P. Atlas No. 67-3-23.

**Riedel's struma** (invasive fibrous thyroiditis) is a rare type of thyroiditis which, because of the firmness and the fixation of the process to structures adjacent to the thyroid, is easily mistaken for cancer. The process is asymmetric. Biopsy is necessary for the definitive diagnosis. Microscopically the follicles are destroyed and replaced by dense fibrosis and an inflammatory infiltrate. Both the fibrosis and the inflammation extend through the thyroid capsule into the adjacent tissues.

## STRUMA LYMPHOMATOSA

(Figures 33 and 34 are from the same case)

Figure 33. An example of struma lymphomatosa shows characteristic large germinal centers and small thyroid follicles with scant colloid. The patient was a 49-year-old woman who complained of a fullness in the neck for one year. The homogeneous tan thyroid weighed 42 gm. × 125. A.F.I.P. Atlas No. 67-3-24.

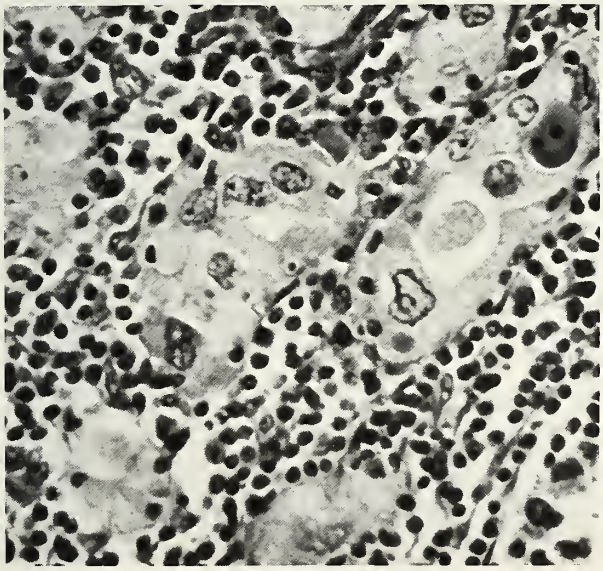

Fig. 34

Figure 34. This higher magnification of struma lymphomatosa shows large follicular cells which are often oxyphilic. The interfollicular cellular infiltrate consists of both lymphocytes and plasma cells. × 500. A.F.I.P. Atlas No. 67-3-25.

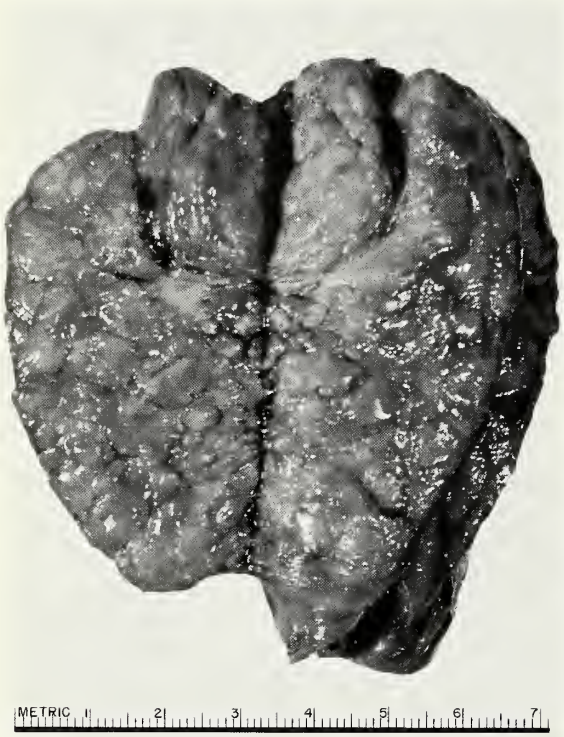


STRUMA LYMPHOMATOSA

Figure 35. This case of struma lymphomatosa shows the lobular cut surface which grossly resembles that of lymphosarcoma and is characteristic of Hashimoto's thyroiditis. (This is figure 5 from Marshall, S. F., Meissner, W. A., and Smith, D. C. Chronic thyroiditis. New Eng. J. Med. 238:758–766, 1948.) A.F.I.P. Acc. No. 219764–14.

Focal infiltrations of lymphocytes often associated with fibrosis are common in the thyroid. When such changes are more extensive, tumor may be suspected because of the induration or nodularity. Histologically, the distinction between **nonspecific chronic thyroiditis** (fig. 36) and tumor usually is not a problem if an adequate and representative sample of the lesion is available. Occasionally, squamous metaplasia of the thyroid epithelium occurs in thyroiditis and must not be confused with squamous cell carcinoma.

CHRONIC THYROIDITIS

Figure 36. Diffuse chronic thyroiditis of fibrotic type is illustrated. A.F.I.P. Acc. No. 219764–13.

Occasionally, a diffuse nonspecific thyroiditis may also be confused with small cell carcinoma or lymphoma, especially if only a few foci are examined. Chronic inflammatory changes are common adjacent to, as well as within, both benign and malignant tumors.

### References

Hawk, W. A., Crile, G., Jr., Hazard, J. B., and Barrett, D. L. Needle biopsy of the thyroid gland. Surg. Gynec. Obstet. 122:1053–1065, 1966.

Hazard, J. B. Thyroiditis: A review. Amer. J. Clin. Path. Part I, 25:289–298; Part II, 25:399–426, 1955.

Woolner, L. B., McConahey, W. M., and Beahrs, O. H. Invasive fibrous thyroiditis (Riedel's struma). J. Clin. Endocr. 17:201–220, 1957.

**HAMARTOMATOUS ADIPOSITY** (Figure 37)

Deposits of fatty tissue may be found within the thyroid and occasionally the deposits are of considerable size. Chesky and associates reported a congenital goiter in a 15-year-old boy whose thyroid weighed 253 gm. and was composed largely of fat. Fatty tissue is presumably included in the embryonic thyroid similar to the way in which striated muscle is sometimes included. Such hamartomatous congenital anomalies may include lymphoid deposits in addition to the fat, and some show amyloidosis of the stroma (Fuller). Some circumscribed or encapsulated nodules of admixtures of fat and thyroid tissue possibly represent true neoplasm and have been called adenolipoma.

**AMYLOID GOITER** (Figure 38)

Walker reviewed 58 cases of amyloidosis of the thyroid and found that the condition may be of the primary or secondary type. In either case, it is almost always associated with amyloid infiltration in another organ or organs. The thyroid may be enlarged and firm because of the amyloid deposition which may result in suspicion of cancer and surgical intervention. Hypothyroidism is surprisingly rare. Infiltration of fatty tissue may be associated with the amyloidosis. Amyloid goiter should not be confused with the amyloid deposits associated with medullary carcinoma or the amyloid deposits sometimes seen in the stroma of follicular adenomas.

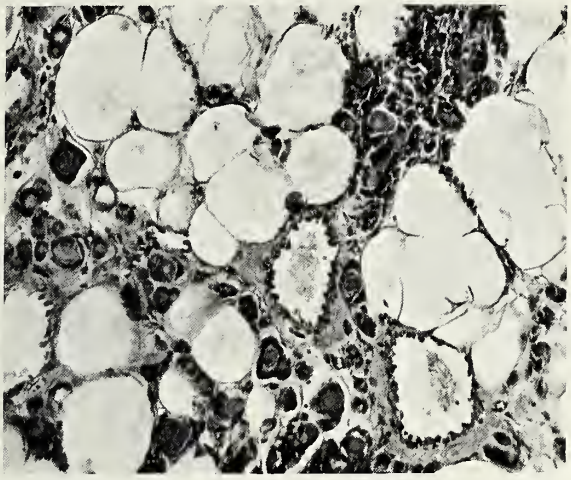

HAMARTOMATOUS ADIPOSITY

Figure 37. An incidental finding of hamartomatous adiposity or adenolipoma was revealed in the autopsy of a 78-year-old man who died from plasma cell myeloma. The 160 gm. thyroid was largely composed of a nodule of fat interspersed with small thyroid follicles. There was no amyloid present. × 125. A.F.I.P. Atlas No. 67-3-26.

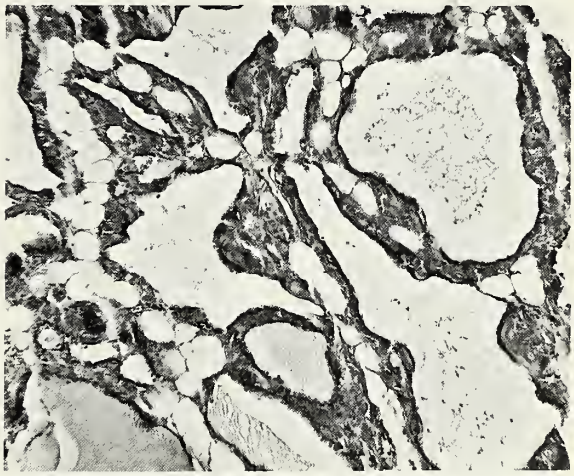

AMYLOID GOITER

Figure 38. A nodule was removed from the thyroid of a 38-year-old woman. There was no neoplasm, but many of the follicular walls were thickened by deposits of amyloid and globules of fatty tissue. The patient had amyloidosis secondary to chronic respiratory infection. × 80. A.F.I.P. Atlas No. 67-3-27.

## References

Chesky, V. E., Dreese, W. C., and Hellwig, C. A. Adenolipomatosis of the thyroid: A new type of goiter. Surgery 34:38–45, 1953.

Fuller, R. H. Hamartomatous adiposity with superimposed amyloidosis of thyroid gland. Amer. J. Clin. Path. 20:188–189, 1950.

Walker, G. A. Amyloid goiter. Surg. Gynec. Obstet. 75:374–378, 1942.

**SQUAMOUS METAPLASIA** (Figures 39, 40)

Groups of squamous cells occur in the thyroid gland of many mammals (fig. 39). In the young rat they may be induced by a diet deficient in vitamin A and arise, according to Van Dyke, at the precise site occupied by the ultimo-branchial tissue component of the gland.

In man, squamous cells are seen in a variety of pathologic states; in most cases, they seem to be the result of metaplasia of either non-neoplastic or neoplastic follicular epithelium rather than fetal rests (Klinçk and Menk). They are not localized to one part of the gland. They occur most frequently in association with papillary carcinoma, chronic nonspecific thyroiditis (fig. 40), adenomatous goiter, and struma lymphomatosa. Islands of metaplastic squamous cells may be confused with squamous cell carcinoma (Bullock et al.).

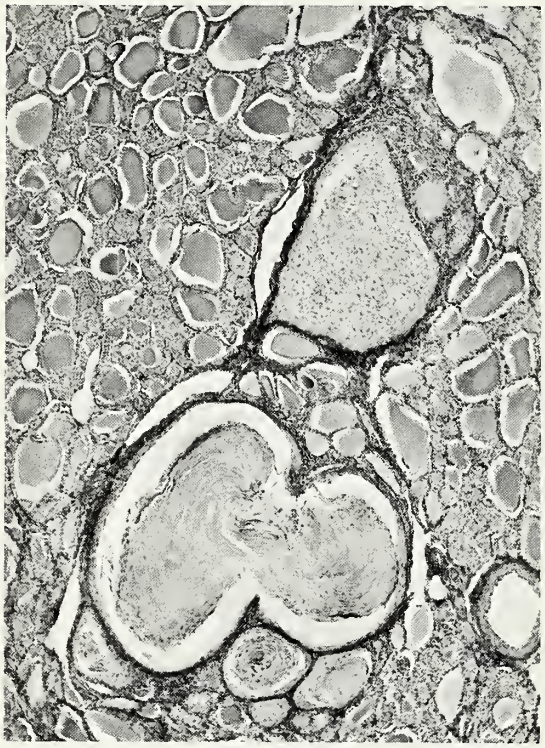

SQUAMOUS METAPLASIA

Figure 39. This squamous metaplasia in the thyroid of a sheep, which is common in many animals, is thought to arise from congenital rests. × 100. A.F.I.P. Atlas No. 67-3-28.

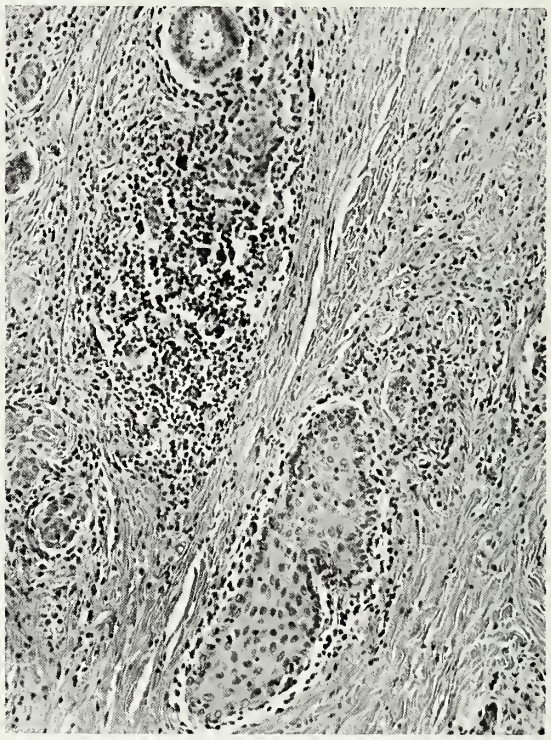

SQUAMOUS METAPLASIA

Figure 40. An example of squamous metaplasia associated with thyroiditis was found in a human thyroid. Squamous metaplasia in man is usually associated with other thyroid disease such as thyroiditis, adenomatous goiter, or tumor. × 150. A.F.I.P. Atlas No. 67-3-29.

## References

Bullock, W. K., Hummer, G. J., and Kahler, J. E. Squamous metaplasia of thyroid gland. Cancer 5:966–974, 1952.

Klinck, G. H., and Menk, K. F. Squamous cells in the human thyroid. Mil. Surgeon 109:406–414, 1951.

Van Dyke, J. H. Experimental thyroid metaplasia in the rat; preliminary report. Arch. Path. 59:73–81, 1955.

## BENIGN TUMORS

### ADENOMA

Practically all benign thyroid tumors are adenomas arising from follicular epithelium. Adenomas may be classed as follicular or papillary, the former being by far more common. The development of extensive subclassifications, particularly of follicular adenomas, has resulted in complex terminology, but there is little evidence that such subclassifications serve a useful purpose.

### FOLLICULAR ADENOMA (Figures 41–52; plate I–B)

SYNONYMS AND RELATED TERMS*: *Adenoma;* alveolar adenoma; solitary nodule or adenoma; discrete nodule or adenoma. The following related terms are sometimes used as synonyms, more often to indicate a subtype of follicular adenoma: trabecular adenoma; embryonal adenoma; fetal adenoma; microfollicular adenoma; macrofollicular adenoma; simple adenoma; colloid adenoma; oxyphil adenoma; Hürthle cell adenoma; atypical adenoma.

DEFINITION. A benign epithelial neoplasm with cells and growth patterns similar to those seen in adult or embryonic thyroid gland. A tendency to form follicles is usually present.

GROSS. The typical follicular adenoma is solitary, round or oval, rubbery-firm, and has a capsule that is well developed (pl. I–B). When it arises in an otherwise normal gland, the encapsulation and contrast in texture to the adjacent compressed gland are striking (fig. 41). There is no predilection for one lobe or portion of a lobe as the site of origin. Surgical specimens usually weigh only a few grams, but may be several hundred grams.

The gross appearance varies somewhat with the amount of colloid which gives the cut surface a brown, translucent aspect. The gross appearance varies more, however, with retrogressive changes. These changes result from interference in blood supply rather than infection and include softening, cyst formation, hemorrhage, and infarction; subsequent fibrosis and calcification, usually central, are frequent and cancer may be suspected from the firmness (figs. 42, 43). The tumor, because of such inflammatory changes, may be adherent to the tissues adjacent to the thyroid, but there is never adherence in an uncomplicated adenoma. Atypical adenomas, which are fleshy and more solid, resemble malignant tumors more than other adenomas.

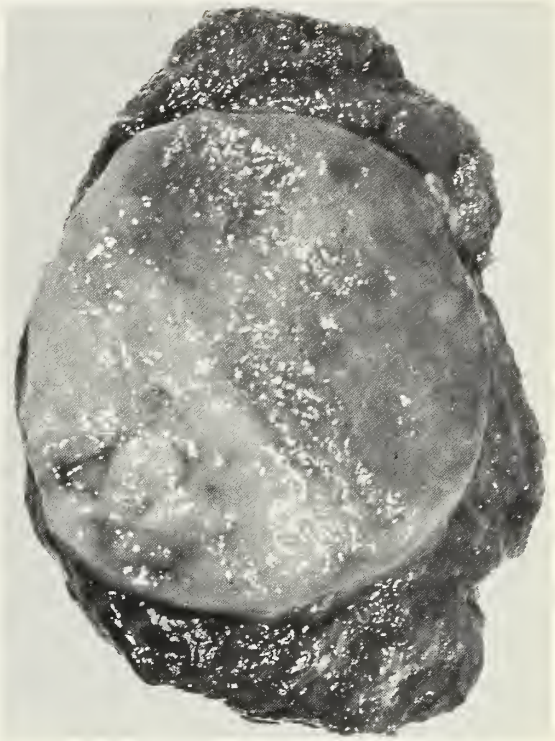

FOLLICULAR ADENOMA

Figure 41. This follicular adenoma is well delineated from the adjacent normal thyroid. The adenoma, uncomplicated by retrogressive changes, is homogeneous. A.F.I.P. Acc. No. 219764–16.

* Italics will be used for the preferred terminology of the Committee on Tumor Nomenclature and Statistics of the International Union Against Cancer. Springer-Verlag, Berlin, Heidelberg, New York, 1965.

## FOLLICULAR ADENOMA

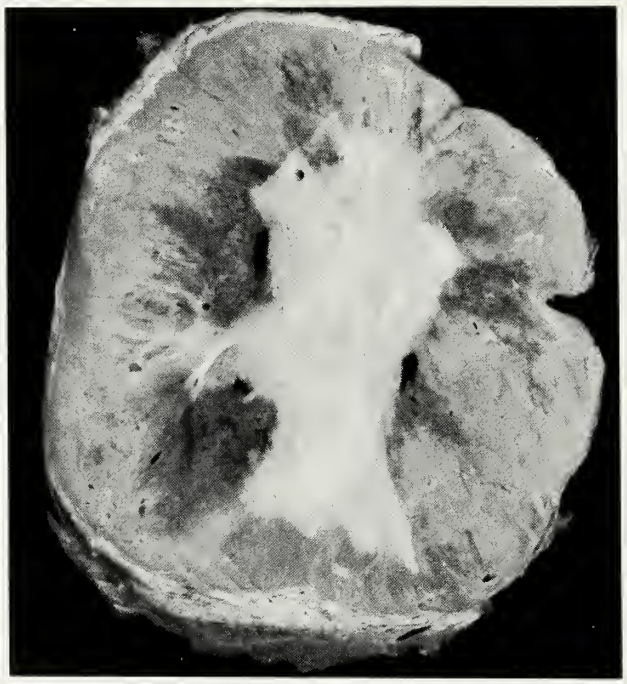

Figure 42. This shows follicular adenoma with central fibrosis secondary to retrogressive changes. A.F.I.P. Acc. No. 219764–17.

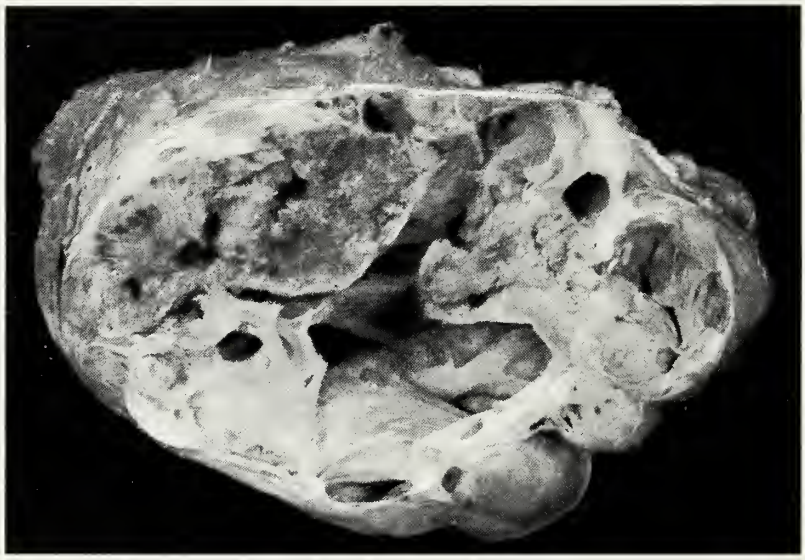

Figure 43. Multilocular cysts secondary to retrogressive changes are frequent in follicular adenomas and may be hemorrhagic. A.F.I.P. Acc. No. 219764–18.

MICROSCOPIC. Each individual follicular adenoma tends to have a consistent microscopic pattern within itself. For purposes of description only, there are six (possibly more) growth patterns: embryonal, fetal, simple, colloid, oxyphil, and "atypical."

**Embryonal adenomas** *(trabecular adenomas)**are the most poorly differentiated of the follicular group (figs. 44, 45). They are composed of columns of small, closely packed thyroid cells often embedded in a considerable amount of edematous, fibrous stroma. There is little follicle formation; if follicles are formed at all, they are small and rarely contain colloid.

FOLLICULAR ADENOMA, EMBRYONAL TYPE

Figure 44. Follicles are poorly formed and rarely contain colloid in embryonal (trabecular) type adenoma. × 48. A.F.I.P. Acc. No. 219764–19.

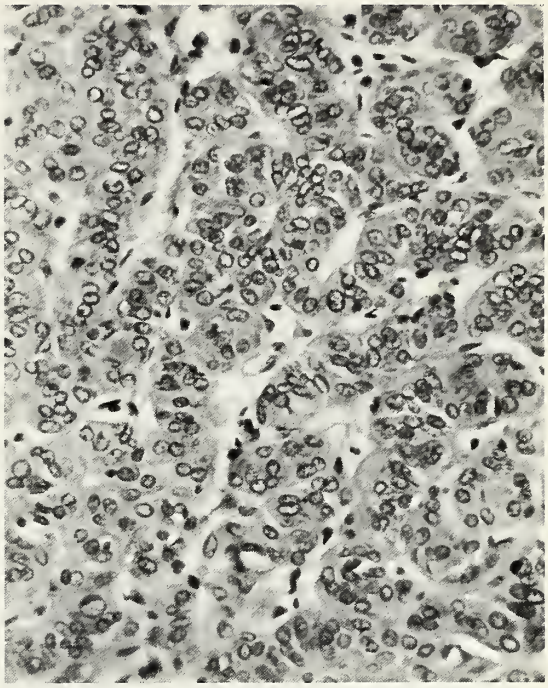

FOLLICULAR ADENOMA, EMBRYONAL TYPE

(Figures 45 and 51 are from the same case)

Figure 45. This higher magnification depicts an embryonal adenoma (trabecular) type. The cells and nuclei are of uniform size. Mitoses are rare and stroma is scanty. × 275. (From the Armed Forces Institute of Pathology. This is the same case as slide 9 in Friedman, N. B. Pathology of the Thyroid Gland. Washington, D. C.: Army Institute of Pathology, 1944, pp. 18, 19; and also figure 403 in Moore, R. A. A Textbook of Pathology, 2d ed. Philadelphia: W. B. Saunders Co., 1951.) A.F.I.P. Acc. No. 87134–2.

**Fetal adenomas** *(microfollicular adenomas)**are slightly more differentiated and show miniature follicle formation (fig. 46). The numerous small follicles are of a primitive or "fetal" type and often contain only a small amount of colloid or no colloid at all. The follicles frequently are sparsely sprinkled through an edematous stroma. Cyst formation and hemorrhage are most common in this type of follicular adenoma.

*Preferred International Nomenclature

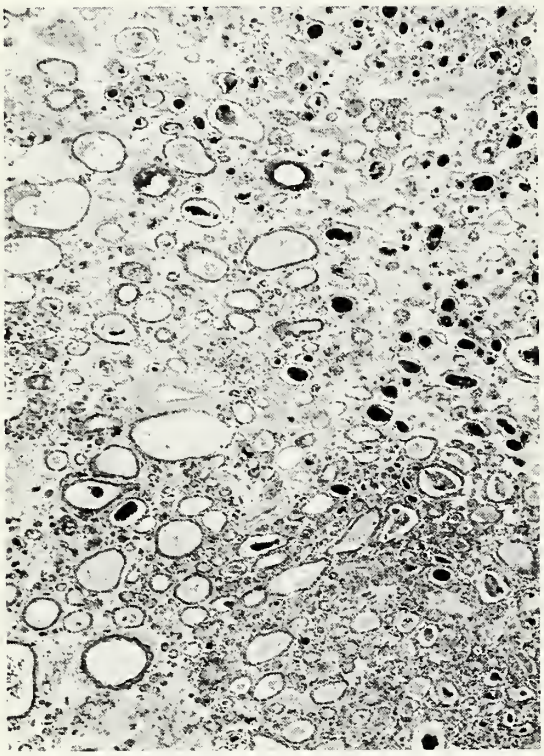

FOLLICULAR ADENOMA, FETAL TYPE

Figure 46. In fetal type of adenoma, follicles are partially developed and often contain small amounts of colloid. × 48. A.F.I.P. Acc. No. 219764-20.

FOLLICULAR ADENOMA, SIMPLE TYPE

Figure 47. The follicles of this simple type of follicular adenoma are similar in size and colloid content to those of a normal thyroid gland. × 48. A.F.I.P. Acc. No. 219764-21.

**Simple adenomas** are made up of well differentiated thyroid tissue, with follicles and colloid content more or less comparable to that of a normal gland (fig. 47). They are, however, definitely encapsulated and separated from the remainder of the gland.

**Colloid adenomas** *(macrofollicular adenomas)** contain excessive colloid within greatly distended follicles (fig. 48), which have less uniformity in size than those of adenomas of other types.

**Oxyphil adenomas** *(oxyphilic adenomas*;* oncocytic adenomas; Hürthle cell adenomas) are composed predominantly or entirely of large cells with a granular acidophilic cytoplasm (fig. 49). The nuclei are vesicular, usually only a little larger than the nuclei of normal thyroid cells, but sometimes quite large and irregular. This type of adenoma shows poor or absent follicular development and contains little or no colloid. In addition to relatively pure oxyphil adenomas, it is common to find oxyphils, scattered singly or in clumps, in any type of adenoma.

**Atypical adenomas** show a microscopic appearance quite different from any of the variants previously described (fig. 50). There is more cellularity than in other adenomas, and both the cells and the cellular architecture are bizarre. Individual cells may be elongated or even spindle shaped; nuclei occasionally are irregular and may

*Preferred International Nomenclature

have mitoses. The pattern tends to be compact and solid, suggesting sarcoma, with only abortive follicles or no follicles at all. It is important to examine the capsular areas carefully to exclude either capsular or vascular invasion. If no invasion is found with adequate sampling, which, according to Hazard, means the study of eight or more sections, one may conclude that the tumor is benign, even though the atypical pattern may suggest cancer. Perhaps these tumors are actually a completely encapsulated adenocarcinoma, but from the practical point of view, if no invasion is found, they are clinically benign.

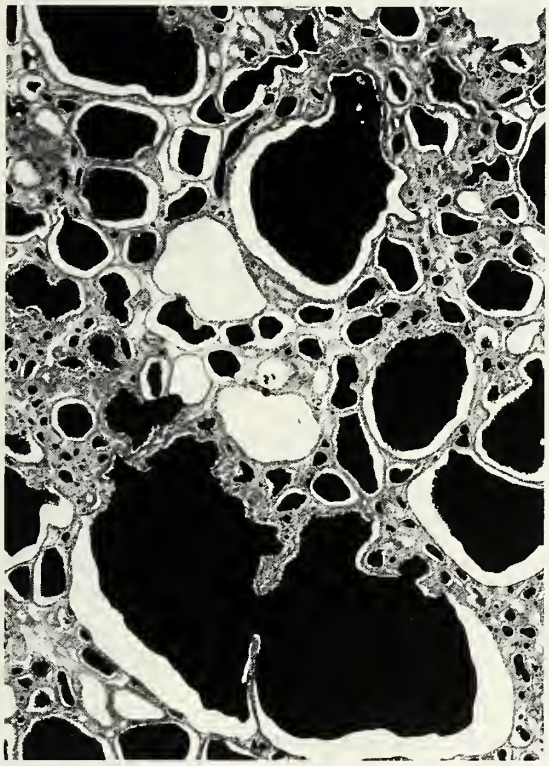

FOLLICULAR ADENOMA, COLLOID (MACROFOLLICULAR) TYPE

Figure 48. In this follicular adenoma, colloid (macrofollicular) type, many follicles are larger than normal and are distended with colloid, similar to the early stage of adenomatous goiter. × 48. A.F.I.P. Acc. No. 219764-22.

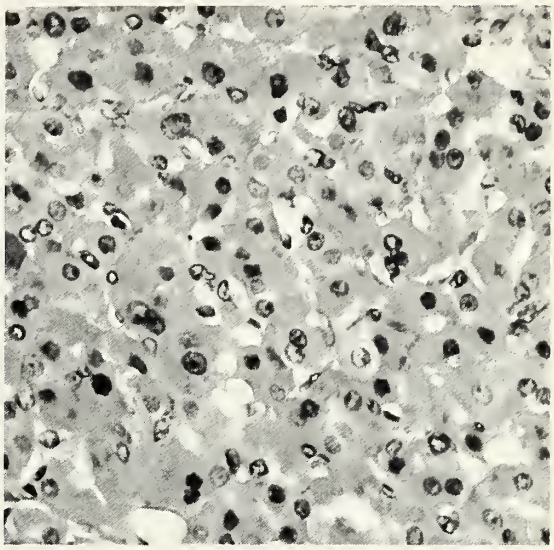

FOLLICULAR ADENOMA, OXYPHIL TYPE

Figure 49. In this follicular adenoma, oxyphil type, the cells are pale and have considerably more cytoplasm than those of normal thyroid epithelium. Follicle formation and colloid are often absent. × 400. (From the Armed Forces Institute of Pathology.) A.F.I.P. Acc. No. 218889.

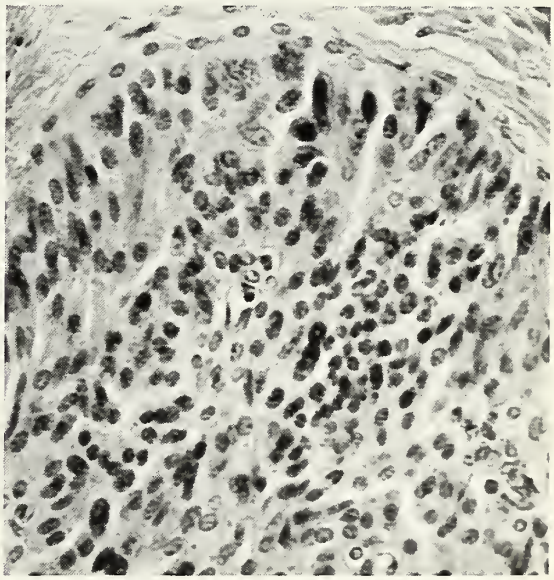

ATYPICAL ADENOMA

Figure 50. There is pleomorphism of both cells and nuclei in this atypical adenoma. Some cells and nuclei are elongate. There is no extension into the capsule. × 400. A.F.I.P. Atlas No. 67-3-30.

While the subgrouping of follicular adenomas is merely descriptive and of little or no clinical value, it is of course important to appreciate that the "atypical" adenomas and the more cellular adenomas should be examined more carefully than others for capsular or vascular invasion. Some investigators believe adenomas with less colloid have a greater precancerous significance.

Regardless of subclassifications, all follicular adenomas have certain microscopic features in common:

1. They are relatively uniform in structure; for example, it is unusual for an embryonal type to show foci of colloid type. If such a mixture is present, the nodule is more likely to be adenomatous goiter than true adenoma.
2. They have an expansile growth which develops their capsule and compresses the adjacent thyroid tissue (fig. 51). Such expansile growth is a characteristic common to most benign tumors, but is uncommon in processes of hypertrophy and repair (adenomatous goiter). In addition to compression, the thyroid tissue adjacent to a follicular adenoma often shows an infiltration with lymphocytes and plasma cells; lymph follicles may be present.
3. Growth rate is slow, as evidenced by (a) maturity—follicle and colloid formation, (b) lack of pleomorphism of cells and nuclei, and (c) rarity of mitoses.
4. Retrogressive changes due to vascular disturbances are frequent and are most conspicuous centrally; i. e., focal necrosis, recent hemorrhage, edema, infarction, hemosiderin and cholesterol accumulations, fibrosis, and calcification (figs. 42, 43). Such changes are not specific for follicular adenomas, since identical ones may be seen in adenomatous goiter and in some carcinomas.
5. Stroma, except for that resulting from retrogressive changes (fig. 52), is scanty; blood and lymphatic vascular supply is abundant, especially at the periphery.

FOLLICULAR ADENOMA

(Figures 45 and 51 are from the same case)

Figure 51. This follicular adenoma shows typical distinct encapsulation and demarcation from adjacent thyroid. × 48. (From the Armed Forces Institute of Pathology. This is the same case as slide 9 in Friedman, N. B. Pathology of the Thyroid Gland. Washington, D. C.: Army Institute of Pathology, 1944, pp. 18, 19; and also figure 403 in Moore, R. A. A Textbook of Pathology, 2d ed. Philadelphia: W. B. Saunders Co., 1951.) A.F.I.P. Acc. No. 87134-1.

Follicular adenomas of the fetal or simple types may have tall columnar epithelium lining some follicles, similar to the epithelium seen in toxic goiters. However, such microscopic evidence of activity can seldom be correlated with clinical hyperthyroidism.

ETIOLOGY. The etiology of follicular adenoma is obscure. Chronic irritation and inflammation are unlikely as etiologic factors; the frequent mild thyroiditis surrounding the tumor is a secondary change. There is little evidence to support the theory that some follicular adenomas develop from embryonic rests.

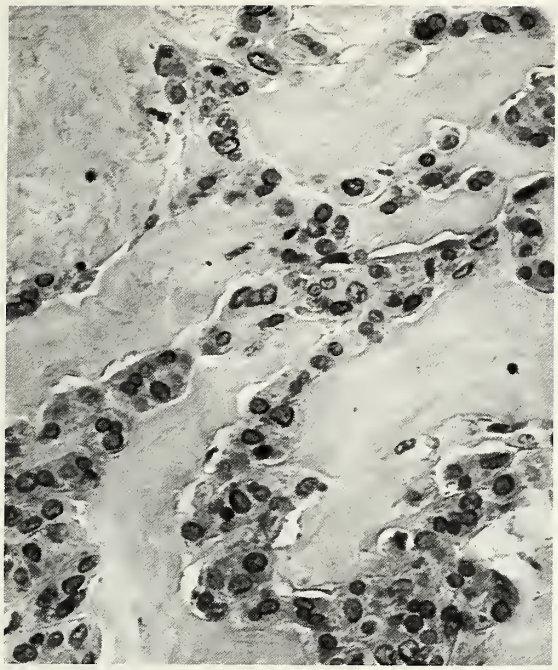

FOLLICULAR ADENOMA

Figure 52. A higher magnification of a follicular adenoma demonstrates fibrosis and hyalinization between strands of epithelium. The stroma did not stain for amyloid. × 250. A.F.I.P. Acc. No. 219764–23.

Follicular adenomas may arise in foci of regenerative hyperplasia. Experimentally, adenomas are induced by the same methods that produce carcinoma and often are preceded by hyperplasia. Since criteria for the sharp distinction between hyperplasia and neoplasia are no more, and perhaps less, satisfactory in the thyroid than elsewhere in the body, a differentiation between the two conditions is not always possible. The proponents of the theory of origin from hyperplasia rely partly on the great similarity of some nodules of an endemic goiter to true neoplastic adenomas. Those who have studied material in nonendemic goiter regions, on the other hand, are impressed by how often the true adenoma is solitary in an otherwise normal gland.

NATURAL HISTORY. Follicular adenomas may appear in any age group but are most common during middle age. They are several times more common in females than in males.

The tumor may follow any of several possible courses:

1. It may remain stationary in size, and produce no symptoms or signs other than a palpable mass.
2. It may slowly increase in size, gradually producing pressure on adjacent structures or becoming disfiguring.
3. It may undergo retrogressive changes, usually vascular in origin. These are often acute, with hemorrhage into the tumor resulting in such an alarming increase in its size that the patient seeks immediate medical advice.
4. It may become hyperfunctioning. While many follicular adenomas function sufficiently to take up radioiodine, only about 1 per cent of true adenomas are active enough to produce clinical hyperthyroidism. Most "toxic adenomas," when examined pathologically, are found to be a nodule of an adenomatous goiter.
5. It may become malignant. This infrequent occurrence is discussed elsewhere under relationship of carcinoma to adenoma on page 61.

DIFFERENTIAL DIAGNOSIS. Clinical differentiation from adenomatous goiter may be aided by the knowledge that the true adenoma is usually solitary. When the adenoma arises in a gland already nodular from endemic goiter, this criterion of course is of little value. Confusion with adenomatous goiter is amplified if the adenoma has undergone retrogressive changes comparable to those seen in adenomatous goiter. Table I shows the major criteria for pathologic differentiation from adenomatous goiter.

Table I

COMPARISON OF ADENOMATOUS GOITER NODULE AND TRUE ADENOMA

| Adenomatous Goiter Nodule | True Adenoma |
|---|---|
| Multiple nodules | Solitary nodule |
| Poor encapsulation | Good encapsulation |
| Variable structure | Uniform structure |
| Comparable growth pattern in adjacent gland | Different growth pattern from adjacent gland |
| No compression of adjacent gland | Compression of adjacent gland |

The distinction between follicular adenoma and carcinoma in an early stage can be made only by histologic examination. The capsular areas of all adenomas, particularly those that are cellular or atypical, must be examined carefully to exclude carcinomatous invasion. (See discussion of follicular carcinoma on page 84).

TREATMENT. Excision of a discrete nodule should be carried out with the understanding that the nodule may be benign or may be malignant; the excision, therefore, should include an adequate margin of adjacent normal thyroid. Complete removal of the involved lobe has been advocated, particularly for the larger tumors. Rapid or frozen sectioning of the tumor is of value in excluding carcinoma. Surgical estimates of the incidence of cancer in "discrete nodules" run as much as 20 per cent. Such a high figure cannot be confirmed by pathologic observation, since a clinically solitary nodule usually proves pathologically to be merely one of multiple nodules of an adenomatous goiter.

**PAPILLARY ADENOMA*** (Figure 53)

SYNONYMS AND RELATED TERMS: Papillary adenocystoma; cystadenoma.

DEFINITION. A benign epithelial neoplasm producing papillae and having a tendency to cyst formation.

GROSS. Papillary adenomas show many gross features in common with follicular adenomas. In contrast, however, to the follicular adenomas which are always solid unless degenerative changes have begun, the papillary adenomas are often cystic (adenocystoma). Typical cysts, filled with brown watery fluid, vary from a few millimeters to a centimeter or more in diameter. Lining walls of the cysts present papilliferous processes growing in fronds or grape-like clusters, closely resembling the gross appearance of the papillary adenocystomas of the ovary. Cut surfaces, where not cystic, may show a shaggy appearance due to the innumerable small papillae.

While cysts are an inherent part of many papillary adenomas, all retrogressive changes seen in follicular adenomas may occur as well.

MICROSCOPIC. The typical cell is cuboidal or columnar, often resembling resting thyroid epithelium; cellular and nuclear pleomorphism is slight and mitoses are rare. The individual cells are arranged in single layers about thin, vascular, connective tissue stalks that project into the lumens of various sized cystic spaces. Fine, irregular deposits of calcium are common in the centers of cell clusters. Frequently some of the cells form a follicle which may contain colloid; there may even be foci within a papillary adenoma that resemble follicular adenoma or normal thyroid tissue.

*Preferred International Nomenclature

PAPILLARY ADENOMA

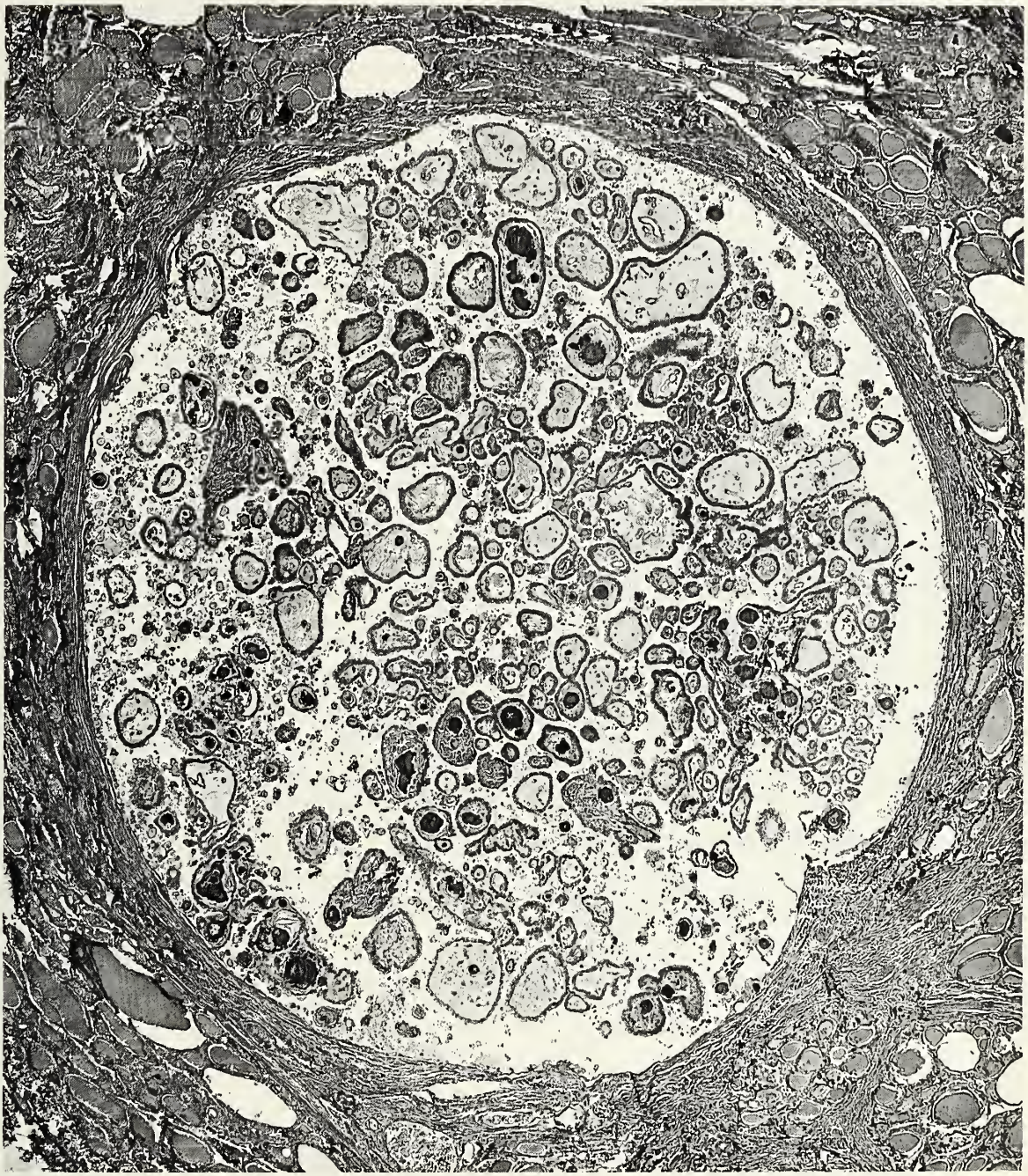

Figure 53. This papillary adenoma illustrates distinct encapsulation and typical structure. There are numerous psammoma bodies. × 46. A.F.I.P. Acc. No. 219764-24.

The tendency to cyst formation is variable; many cysts are microscopic. Larger cysts are often multiloculated and contain hemosiderin from old or recent hemorrhage.

ETIOLOGY AND NATURAL HISTORY. The etiology is obscure, with theories of origin similar to those suggested for follicular adenoma. Resemblance of some of the tumor growth patterns to those seen in hyperplasia is often striking. Papillary adenomas have been observed among experimentally induced thyroid tumors (Potter et al.).

The course of these tumors is similar to that of the follicular adenomas, and it is quite possible that the distinction between the papillary and follicular adenomas is unnecessary, particularly since the papillary adenomas often show foci of the follicular pattern.

DIFFERENTIAL DIAGNOSIS. This is essentially the same as in follicular adenoma. It should be noted, however, that benign papillary tumors of the thyroid are extremely rare even though malignant papillary tumors are the most common type of thyroid cancer. The diagnosis of papillary adenoma, therefore, should be made only after meticulous study of the tumor to exclude evidences of cancer such as invasion of capsule, adjacent thyroid, or vessels. The similarity of growth patterns in hyperplasia and in tumor may cause confusion, particularly in the differentiation of the individual papillae of hyperplasia in adenomatous goiter from the papillae of neoplasia. The formation of papillae is not in itself an indication of tumor, either benign or malignant.

TREATMENT. The treatment is the same as for follicular adenoma.

## References

Cope, O., Dobyns, B. M., Hamlin, E., Jr., and Hopkirk, J. What thyroid nodules are to be feared? J. Clin. Endocr. 9:1012–1022, 1949.

———, Rawson, R. W., and McArthur, J. W. The hyperfunctioning single adenoma of the thyroid. Surg. Gynec. Obstet. 84:415–426, 1947.

Hamperl, H. Onkocytes and the so-called Hürthle cell tumor. Arch. Path. 49:563–567, 1950.

Hazard, J. B., and Kenyon, R. Atypical adenoma of the thyroid. Arch. Path. 58:554–563, 1954.

Liechty, R. D., Graham, M., and Freemeyer, P. Benign solitary thyroid nodules. Surg. Gynec. Obstet. 121:571–573, 1965.

Meissner, W. A., and McManus, R. G. A comparison of the histologic pattern of benign and malignant thyroid tumors. J. Clin. Endocr. 12:1474–1479, 1952.

Murphy, W. B., and Ahnquist, G. Origin of fetal adenoma in the thyroid gland. Arch. Surg. 35:211–233, 1937.

Potter, G. D., Lindsay, S., and Chaikoff, I. L. Induction of neoplasms in rat thyroid glands by low doses of radioiodine. Arch. Path. 69:257–269, 1960.

Zondek, H., and Leszynsky, H. The genesis of thyroid adenomas. Lancet 1:77–78, 1956.

## BENIGN TERATOMA OF THE THYROID AND THYROID REGION (Figure 54)

Teratomas occasionally arise in the thyroid gland and adjacent tissues of the neck. Some merely displace the thyroid, apparently arising external to it; others, located within the gland itself, replace thyroid tissue and are supplied by one of the thyroid arteries. They are found almost exclusively in newborn babies and infants. Because of their large size, they may produce dystocia. Hydramnios is frequently associated. Although surgical excision is often necessary as an emergency procedure to alleviate pressure symptoms, the prognosis is surprisingly good. Teratomas usually are composed of a large mixture of tissues with an emphasis on neural components. Some contain thyroid tissue within them as part of the tumor.

Newstedt and Shirkey reviewed the literature and found 82 teratomas in infants and 4 in adults. Of the 82 teratomas in infants, 81 were benign clinically and 1 was questionably malignant. However, 3 of the 4 teratomas in adults were malignant.

The differential diagnosis of teratoma in the region of the thyroid includes cystic hygroma, congenital goiter, and branchial cyst. X-rays of the tumor may demonstrate calcification which, according to Goodwin and Gay, is virtually diagnostic of teratoma.

### References

Goodwin, B. D., and Gay, B. B., Jr. The roentgen diagnosis of teratoma of the thyroid region. A review of the literature. Amer. J. Roentgen. 95:25–31, 1965.

Newstedt, J. R., and Shirkey, H. C. Teratoma of the thyroid region. Report of a case with seven-year follow-up. Amer. J. Dis. Child. 107:88–95, 1964.

Silberman, R., and Mendelson, I. R. Teratoma of the neck: Report of two cases and review of the literature. Arch. Dis. Child. 35:159–170, 1960.

TERATOMA OF THYROID

Figure 54. This is a teratoma of thyroid from a newborn infant. At the bottom of the field, there are a few follicles of the normal thyroid compressed by the large benign tumor. The teratoma contains cartilage, several types of epithelium, and neural tissue. × 50. A.F.I.P. Atlas No. 67-3-31.

## OTHER BENIGN TUMORS

Benign tumors of the thyroid other than adenoma and teratoma are extremely rare. Their gross and microscopic features are the same as comparable tumors arising elsewhere. Hemangiomas occasionally arise in the thyroid. Hendrick reported a leiomyoma of the thyroid in a 3-year-old girl.

### References

Hendrick, J. W. Leiomyoma of the thyroid gland. Report of case. Surgery 42:597–599, 1957.

## MALIGNANT TUMORS, GENERAL DISCUSSION

The pathologic diagnosis of cancer of the thyroid is made by using the same criteria as those used for the diagnosis of cancer of other tissues of the body. It is true that some thyroid cancers grow very slowly and represent a low grade of malignancy. It is also true that some cancers of the thyroid are so well differentiated that the diagnosis of cancer must be based on their invasive nature, rather than on cellular morphology alone. All tumors showing the pathologic criteria of cancer must be called malignant, however, whether they are differentiated or undifferentiated, whether they are growing slowly or rapidly, or whether they show minimal invasion or widespread extension. Neither the slow growth of some thyroid cancers nor the fact that well localized cancers may be cured by simple excision disproves the fact that they are malignant tumors.

### CLASSIFICATION

With the exception of lymphomas and a few types of rare tumors, malignant neoplasms of the thyroid are of glandular epithelial origin—carcinomas. While the classification of carcinomas is not really difficult, it has been complicated by innumerable synonyms and subgroupings. The classification used here in Table II is similar to that used in the previous fascicle on thyroid tumors and to that used by many pathologists. It is designed to be helpful not only to the pathologist but to the surgeon and clinician as well, since thyroid cancers are predominantly a problem of surgical rather than postmortem pathology.

Table II

CLASSIFICATION OF CANCER OF THYROID

- Carcinoma
  - Papillary adenocarcinoma
  - Follicular carcinoma
    - Clear cell carcinoma
    - Oxyphil carcinoma
  - Medullary carcinoma
  - Undifferentiated carcinoma
    - Small cell carcinoma
    - Giant cell carcinoma
  - Epidermoid carcinoma
- Other malignant tumors
  - Lymphoma
  - Sarcoma
  - Malignant teratoma
  - Secondary tumor

### GRADING

Numerical grading is not as common a practice with thyroid carcinomas as it is for tumors in some other parts of the body, but the grade is implied by the name used for its classification. In Table II the tumors are listed more or less according to their degree of malignancy; papillary carcinoma is the least malignant and giant cell carcinoma is the most malignant. Even within the group of undifferentiated cancers, there are tumors of varying grades of malignancy. This is not surprising because differentiation is only one of the criteria used to evaluate the degree of malignancy of a tumor. Some persons make a distinction between undifferentiated

and anaplastic (words that are actually synonyms, the former being of Latin and the latter of Greek derivation), and consider anaplastic to be a synonym for highly malignant rather than for undifferentiated. The two terms will be used here as synonyms.

## STAGING

It has been acknowledged for many years, based largely on the studies initiated by Graham, that some thyroid cancers are grossly and microscopically identical with benign adenomas except for one feature: they show microscopic *invasion* of blood vessels, of lymphatic vessels, or of their capsule. Whether such tumors represent a transition stage from adenoma to fully developed carcinoma or whether they represent a carcinoma with only slight invasive tendencies is unclear. There is no question, however, that they do represent malignant tumors and occasionally metastasize. The prognosis for such tumors is so good that radical treatment often used for other more extensive thyroid carcinomas has proved clinically to be unnecessary. Although it is of clinical importance to distinguish tumors of this type from more fully developed carcinomas, it has been extremely difficult to find a suitable name for them. A wide variety of terms has been suggested and used: adenoma with invasion, malignant adenoma, angioinvasive adenoma, potentially malignant tumor, benign metastasizing goiter, early cancer, and low grade cancer. None of these terms is really accurate or satisfactory. Unfortunately, as yet, there is no generally accepted system of staging for thyroid carcinoma. If there were such a system, these tumors certainly would be classified as stage I.

With tumors showing more extensive growth and spread, dissemination within the gland is very common. In addition, metastasis by way of both lymphatic and blood vessels may occur with all types of thyroid cancer. But one of the most important criteria that determines prognosis of thyroid carcinoma is spread by direct extension into adjacent tissues of the neck. Such extension seems to be of more significance in determining the prognosis of an individual case than the presence of metastases in cervical lymph nodes.

In the past, there have been cumbersome attempts to include the stage, the grade, and the histologic appearance of a tumor all into a single nomenclature. As with tumors in other parts of the body, however, the grade and the stage of a tumor are not synonymous and not necessarily even related, so the two evaluations should be reported separately. Table III illustrates a method of staging thyroid carcinomas (Smedal et al.).

Table III

SURGICAL AND PATHOLOGIC STAGING IN THYROID CARCINOMA

Stage I
- A—Confined to one lobe
- B—Bilateral, multicentric, or in isthmus

Stage II
- —Primary as in Stage I–A or Stage I–B with metastases in lymph nodes
- A—Unilateral lymph nodes
- B—Bilateral lymph nodes, lymph nodes in mediastinum, or midline lymph nodes

Stage III
- Invasion of other tissues or structures in neck or adjacent mediastinum with or without lymph nodes

Stage IV
- Distant metastases

### References

Graham, A. Malignant epithelial tumors of thyroid; invasion of blood vessels. Surg. Gynec. Obstet. 39:781–790, 1924.

Smedal, M. I., Salzman, F. A., and Meissner, W. A. The value of 3 mv. roentgen-ray therapy in differentiated thyroid carcinoma. Amer. J. Roentgen. 99:352–364, 1967.

## ETIOLOGY AND HISTOGENESIS

### EPIDEMIOLOGY

Recent studies suggest that there has been an increased incidence of thyroid carcinoma in some parts of the world during the past 20 years. For example, Carroll and associates state that, according to figures of the New York State Cancer Registry, thyroid cancer incidence rates more than doubled from 1941 to 1962. Increased incidence may result not only from better recognition, but other factors such as thymic irradiation in infants and increased exposure to radioiodine and to goitrogens must also be considered.

The attack rate of thyroid cancer has been compiled from many countries and averages around 2 to 3 per 100,000; figures from different countries vary widely, but often are based on relatively few cases so evaluations are difficult. One can state with statistical certainty, however, that cancer of the thyroid in all countries is more common in women than in men and it is more frequent in older individuals; the latter is particularly true of the more highly malignant tumors. Mustacchi and Cutler observed that the incidence rate of papillary carcinoma changes very little with advancing age, whereas the incidence of other histologic types of thyroid cancer increases progressively with age.

It has often been said that cancer of the thyroid is more frequent in endemic goiter areas of the world. While there is some experimental evidence to support such a belief, it is difficult to prove statistically. In areas where vital statistics are most likely to be accurate, endemic goiter has largely been eradicated by dietary use of iodine. Conversely, where endemic goiter is still a common finding, complete vital statistics tend to be less available.

Innumerable attempts have been made to assess the incidence of cancer of the thyroid in surgical material, but the value of such evaluations is questionable. Particularly unfortunate are statements sometimes made that the incidence of thyroid cancer is increasing merely because a higher proportion of thyroid carcinoma in surgical thyroid specimens has been found. This higher proportion is usually the result of patient selection.

The true incidence of thyroid carcinoma can be determined only at autopsy and only then after a meticulous study of the thyroid gland. Silverberg and Vidone recently have performed such a study and give an excellent review of the problems involved. They found, after careful examination of the thyroid gland at autopsy, that the incidence of thyroid carcinoma was 1.79 per cent in unselected cases. The carcinomas were usually unsuspected clinically.

Death from thyroid cancer is not common. The American Cancer Society estimates 1100 deaths from thyroid cancer in the United States during 1968–about 0.35 per cent of total cancer deaths. Willis states that thyroid cancer accounted for 0.6 per cent of cancer deaths in Northern Ireland in the years 1955 to 1957.

### References

Carroll, R. E., Haddon, W., Jr., Handy, V. H., and Wieben, E. E. Thyroid cancer: Cohort analysis of increasing incidence in New York State, 1941–1962. J. Nat. Cancer Inst. 33: 277–283, 1964.

Doll, R., Payne, P., and Waterhouse, J. (eds.) Cancer Incidence in Five Continents. A Technical Report. International Union Against Cancer. Berlin, Heidelberg, New York: Springer-Verlag, 1966.

Estimated cancer deaths by sex and site. In: 1968 Cancer Facts and Figures, p. 6. New York: American Cancer Society, Inc., 1967.

Mustacchi, P., and Cutler, S. J. Some observations on the incidence of thyroid cancer in the United States. New Eng. J. Med. 255:889–893, 1956.

Silverberg, S. G., and Vidone, R. A. Carcinoma of the thyroid in surgical and postmortem material. Analysis of 300 cases at autopsy and literature review. Ann. Surg. 164:291–299, 1966.

Willis, J. Incidence and aetiology of thyroid carcinoma. Brit. Med. J. 1:1646–1649, 1961.

**SPONTANEOUS TUMORS IN THE THYROID OF ANIMALS** (Figures 55, 56)

Adenomas and, more frequently, carcinomas have been reported in fishes, birds, and mammals (Schlumberger). The highest incidence of carcinoma is in species that frequently exhibit goiter, suggesting that hyperplasia, perhaps secondary to iodine deficiency, may be the precursor of the cancer.

There are many case reports and reviews of carcinoma of the thyroid in dogs. The histology is usually that of a poorly differentiated adenocarcinoma (figs. 55, 56). Occasionally there is a spindle cell carcinoma, resembling a sarcoma, comparable in histologic appearance to some of the spindle cell carcinomas of the human thyroid. Williams believes that the parafollicular cell tumors of the dog and rat resemble the medullary carcinoma of the human thyroid. A few adenomas and a rare adenocarcinoma have been reported in cats. Adenocarcinoma also occurs in sheep, horses, cattle, and swine.

Among wild animals, carcinoma of the thyroid is most common in relatives of the dog such as the fox and wolf. Carcinomas of the thyroid have been found in bears, lions, tigers, raccoons, and many other animals.

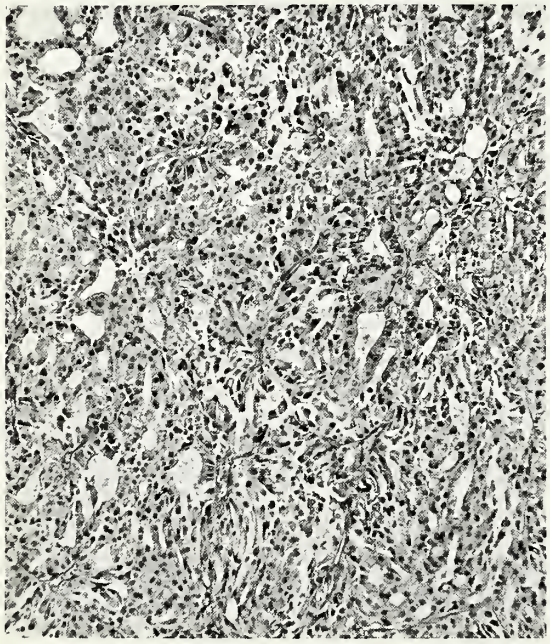

SPONTANEOUS CARCINOMA IN DOG

Figure 55. This is a spontaneous carcinoma of the thyroid from a 10-year-old male dachshund. The tumor is primarily follicular and contains many oxyphilic cells. × 100. (Courtesy of Dr. Charles Gilmore, Boston, Mass.) A.F.I.P. Atlas No. 67-3-32.

SPONTANEOUS CARCINOMA IN DOG

Figure 56. This spontaneous carcinoma of the thyroid is from a 7½-year-old male beagle. The carcinoma has a more solid pattern than that of figure 55. × 100. (Courtesy of Dr. Charles Gilmore, Boston, Mass.) A.F.I.P. Atlas No. 67-3-33.

## References

Schlumberger, H. G. Spontaneous hyperplasia and neoplasia in the thyroid of animals. Pp. 169–191. In: The Thyroid. Upton, N. Y.: Biology Dept., Brookhaven National Laboratory Symposia in Biology No. 7, 1954.

Williams, E. D. Histogenesis of medullary carcinoma of the thyroid. J. Clin. Path. 19:114–118, 1966.

## EXPERIMENTAL TUMORS

Spontaneous tumors of the thyroid gland in rats and mice are rare, but induction of tumors experimentally in these and other laboratory animals is quite easily achieved in a number of different ways. Technics used for tumor induction include single (Goldberg et al.) or multiple (Potter et al.) exposures to radioiodine, external irradiation (Lindsay et al.), low iodine diets (Axelrad and Leblond), chronic ingestion of goitrogens (Money et al.), partial thyroidectomy (Doniach and Williams), and various combinations of these technics. Money and Rawson were unable to induce cancer by intrathyroidal local application of chemical carcinogens in the rat.

Since many methods of producing experimental tumors initially bring about hyperplasia of the follicular epithelium, it has been postulated that the factor in the production of experimental thyroid tumors is a persistent high blood level of the thyrotropic hormone. In fact, thyrotropic hormone has been used to induce thyroid tumors directly (Sinha et al.). Following the initiation of a hyperplastic stage, local areas of proliferation of altered cells develop, then adenomas and finally carcinomas result. There is quite a variation in the induction periods. The tumors have a variety of patterns, including papillary and spindle cell, but often they are follicular carcinomas. Fortner and associates found that induced tumors in the hamster were follicular and associated with hyperplasia, while spontaneous tumors were not associated with hyperplasia and were papillary, follicular, or spindle cell. The follicular carcinomas may or may not form colloid. According to Money and associates, some thiouracil-induced tumors have the capacity to concentrate radioiodine and to produce monoiodotyrosine, diiodotyrosine, triiodothyronine, and thyroxine. The carcinomas show progressive growth and kill the host either by invasion of surrounding tissues or by disseminated metastases. Goitrogen-induced tumors are initially dependent on a deficiency of thyroid hormone for their continued growth; with serial transplants, however, many of the tumors become hormonally independent.

Furth and his co-workers have shown that ablation of the thyroid leads to sustained stimulation of the pituitary thyrotropes and consequent pituitary tumors. The tumors, at first dependent in that they will not grow in the presence of thyroxine, may become autonomous after continued transplantation.

Psammoma bodies, similar to those seen in many papillary carcinomas of the human thyroid, were noted by Follis in hyperplastic thyroid glands of rats which were fed on iodine-deficient diets. The psammoma bodies were not observed in hamsters, mice, or monkeys on similar diets.

### References

Axelrad, A. A., and Leblond, C. P. Induction of thyroid tumors in rats by a low iodine diet. Cancer 8:339–367, 1955.

Doniach, I., and Williams, E. D. The development of thyroid and pituitary tumours in the rat two years after partial thyroidectomy. Brit. J. Cancer 16:222–231, 1962.

Follis, R. H., Jr. Psammoma bodies associated with experimental thyroid hyperplasia in the rat. Proc. Soc. Exp. Biol. Med. 119:931–934, 1965.

Fortner, J. G., George, P. A., and Sternberg, S. S. Induced and spontaneous thyroid cancer in the Syrian (golden) hamster. Endocrinology 66:364–376, 1960.

Furth, J., Kim, U., and Clifton, K. H. On evolution of the neoplastic state; progression from dependence to autonomy. Nat. Cancer Inst. Monogr. 2:149–177, 1960.

Goldberg, R. C., Lindsay, S., Nichols, C. W., Jr., and Chaikoff, I. L. Induction of neoplasms in thyroid

glands of rats by subtotal thyroidectomy and the injection of one microcurie of $I^{131}$. Cancer Res. 24:35–43, 1964.

Lindsay, S., Sheline, G. E., Potter, G. D., and Chaikoff, I. L. Induction of neoplasms in the thyroid gland of the rat by x-irradiation of the gland. Cancer Res. 21:9–16, 1961.

Money, W. L., and Rawson, R. W. Intrathyroid implantation of chemical carcinogens in the rat. Arch. Path. 79:470–474, 1965.

———, Typond, P., and Rawson, R. W. The growth and function of thiouracil-induced thyroid tumors transplanted into non-inbred rats thymectomized at birth. Cancer Res. 25:423–431, 1965.

Potter, G. D., Lindsay, S., and Chaikoff, I. L. Induction of neoplasms in rat thyroid glands by low doses of radioiodine. Arch. Path. 69:257–269, 1960.

Sinha, D., Pascal, R., and Furth, J. Transplantable thyroid carcinoma induced by thyrotropin: Its similarity to human Hürthle cell tumors. Arch. Path. 79:192–198, 1965.

## RELATIONSHIP TO OTHER THYROID DISEASE

(Figures 57–60)

In experimental tumor induction, **hyperplasia** of the thyroid epithelium often precedes the development of benign or malignant tumors; therefore, it is reasonable to postulate that hyperplasia of the human thyroid epithelium may be related to neoplasia. The possibility is particularly suggestive in the development of papillary carcinoma, since the tumor papillae and even individual tumor cells show a great resemblance to papillary hyperplastic processes and cells seen, for example, in Graves' disease. Meissner and Adler, in studying 226 surgical specimens of papillary thyroid carcinoma, noted that 5 were in glands with coexistent hyperplasia of Graves' disease. Other studies, such as that of Pemberton and Black, also have suggested a relationship between hyperplasia in the human gland and neoplasia. Olen and Klinck reviewed over 2,000 thyroid glands in patients exhibiting hyperthyroidism and found 53 instances of associated cancer (2.5 per cent). It seems likely that hyperplasia, particularly that of Graves' disease, occasionally has precancerous significance.

### References

Meissner, W. A., and Adler, A. Papillary carcinoma of the thyroid: A study of the pathology of two hundred twenty-six cases. Arch. Path. 66:518–525, 1958.

Olen, E., and Klinck, G. H. Hyperthyroidism and thyroid cancer. Arch. Path. 81:531–535, 1966.

Pemberton, J. deJ., and Black, B. M. The association of carcinoma of the thyroid gland and exophthalmic goiter. In: Transactions of the American Goiter Association, pp. 163–178. Springfield, Ill.: Charles C. Thomas, 1948.

Several observations suggest a relationship between **adenomatous goiter** and thyroid cancer. First, spontaneous tumors of animals are said to be more common in endemic goiter regions. Second, both experimental thyroid tumors and adenomatous goiter may be induced by low iodine diets. Third, in the early stages of the development of adenomatous goiter, the hyperplasia is similar to that seen in the early stages of the development of experimental thyroid tumors. Fourth, some clinicians feel that adenomatous goiter precedes cancer in a significant number of cases. In 1928, Wegelin found that the incidence of cancer at autopsy in Berne (then a high goitrous area) was 1.04 per cent, while in Berlin (a nongoitrous area) it was only 0.09 per cent.

In spite of suggestions that adenomatous goiter may be a precancerous lesion, recent studies from various areas of the world disagree. For example, a comparison of the geographic distribution of goiter with the geographic pattern of mortality from thyroid cancer does not show a convincing association between the two diseases either in the United States (Pendergast et al.) or in Australia (Clements). In statistics reported by

Dorn and Cutler, the age-adjusted incidence of thyroid carcinoma is no greater in Chicago and Detroit, both of which are in endemic goiter areas, than it is in 10 other large cities in the United States located in nongoitrous areas.

### References

Clements, F. W. The relationship of thyrotoxicosis and carcinoma of the thyroid to endemic goiter. Med. J. Aust. 2:894–897, 1954.

Cole, W. H., Majarakis, J. D., and Slaughter, D. P. Incidence of carcinoma of the thyroid in nodular goiter. J. Clin. Endocr. 9:1007–1011, 1949.

Dorn, H. F., and Cutler, S. J. Morbidity from cancer in the United States, Washington, D. C. Public Health Monogr. No. 56, 1959.

Pendergast, W. J., Milmore, B. K., and Marcus, S. C. Thyroid cancer and thyrotoxicosis in the United States: Their relation to endemic goiter. J. Chronic Dis. 13:22–38, 1961.

Wegelin, C. Malignant disease of the thyroid gland and its relations to goitre in man and animals. The Cancer Review 3:297–313, 1928.

**Thyroiditis** is a common accompaniment of thyroid cancer. The association of the two conditions has led some to believe there was a causal relationship, the thyroiditis preceding the carcinoma. Most observers, however, agree that thyroiditis associated with thyroid cancers is secondary to the neoplasm and represents either the inflammatory reaction common around all tumors or a reaction induced by an antigen from the neoplasm itself (Hirabayashi and Lindsay). In a careful, long term follow-up of patients with struma lymphomatosa, Crile and Hazard concluded that it was not a premalignant lesion. From available evidence, the same may be said for all forms of thyroiditis. One exception, still to be evaluated, is the etiologic relationship of thyroiditis, particularly struma lymphomatosa, to primary lymphoma of the thyroid.

### References

Crile, G., Jr., and Hazard, J. B. Incidence of cancer in struma lymphomatosa. Surg. Gynec. Obstet. 115:101–103, 1962.

Hirabayashi, R. N., and Lindsay, S. The relation of thyroid carcinoma and chronic thyroiditis. Surg. Gynec. Obstet. 121:243–252, 1965.

The frequency with which thyroid carcinoma arises in a pre-existing benign **adenoma** is unknown. From evaluation of available data, it is unlikely that very many thyroid cancers arise from adenomas. In the past, it was thought that most carcinomas of the thyroid arose from benign tumors. This belief was promoted by the tendency of many clinicians, and even some pathologists, to refer to any fairly circumscribed nodule in the thyroid as an adenoma; if the nodule proved to be a carcinoma after excision, the confusion was compounded by mistakenly designating the cancer as carcinoma arising in an adenoma. Since the diagnosis of either adenoma or carcinoma is best made after pathologic examination, it is preferable that clinicians refer to nodules of the thyroid as "nodules" rather than adenomas.

Papillary adenomas are rare in the thyroid and papillary carcinoma is the most frequent single type of cancer so one may conclude that most papillary carcinomas are malignant from inception, rather than having arisen from a pre-existing benign tumor. The average age of the patient at the time of removal of either a follicular adenoma or a follicular carcinoma is approximately the same (Meissner and McManus). If follicular carcinomas arose from adenomas, one might well expect the average patient to be older at the time of the removal of the carcinoma.

There are, however, a few reasons for suspecting that some carcinomas do arise from pre-existing benign adenomas. In some experimentally induced tumors of the

thyroid, such a transition seems to take place (Doniach). Many thyroid cancers have a history of slow growth for many years, suggesting adenoma, and then suddenly grow rather rapidly suggesting transition to cancer (fig. 57). Occasionally in the center of cancers there is an outline of, or remnants of, a capsule of a nodule, possibly an adenoma (figs. 58–60). Giant cell carcinomas particularly are likely to show such foci. A common clinical history in patients with giant cell carcinoma is of a nodule, stationary in size for 15 or more years, which suddenly has begun to grow rapidly (Hare and Salzman).

## References

Doniach, I. The effect of radioactive iodine alone and in combination with methylthiouracil upon tumour production in the rat's thyroid gland. Brit. J. Cancer 7:181–202, 1953.

Hare, H. F., and Salzman, F. A. Cancer of thyroid; 10 to 20-year follow-up. Amer. J. Roentgen. 63: 881–888, 1950.

Meissner, W. A., and McManus, R. G. A comparison of the histologic pattern of benign and malignant thyroid tumors. J. Clin. Endocr. 12:1474–1479, 1952.

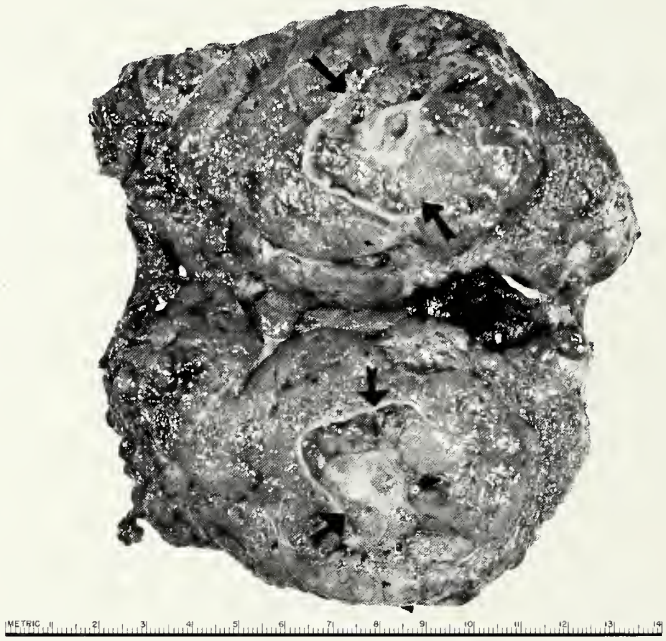

CARCINOMA ARISING FROM ADENOMA

Figure 57. While most of the specimen consists of undifferentiated carcinoma, giant cell type, the remnants of the preexisting adenoma, centrally calcified, can be seen in the center of the tumor. According to the case history, a thyroid "nodule" had been present for 15 years, but just before surgical excision it had increased rapidly in size. A.F.I.P. Acc. No. 219764–25.

CARCINOMA ARISING FROM ADENOMA

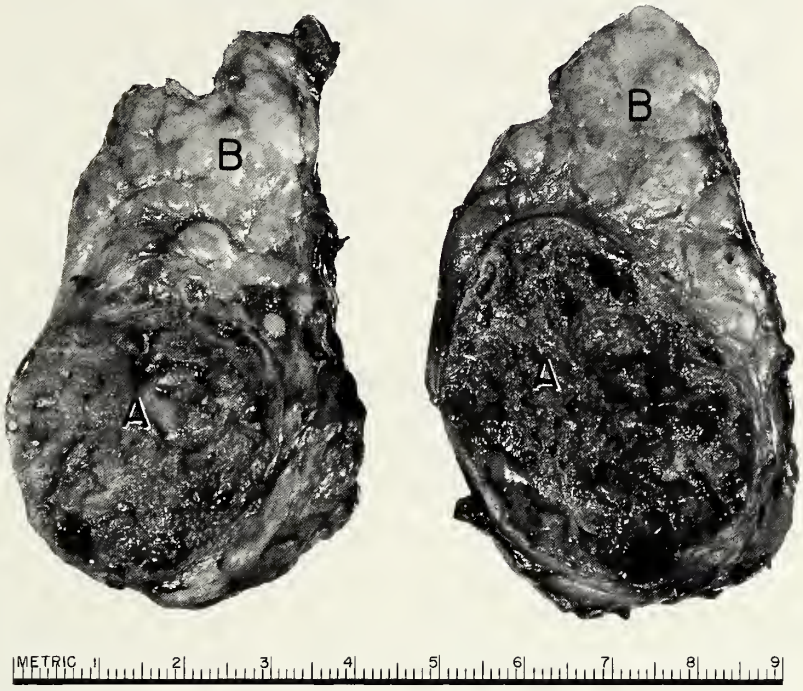


Figure 58. This illustrates another carcinoma apparently arising from an adenoma. Remnants of the adenoma (A) are almost completely surrounded by anaplastic carcinoma (B). A.F.I.P. Acc. No. 219764–26.

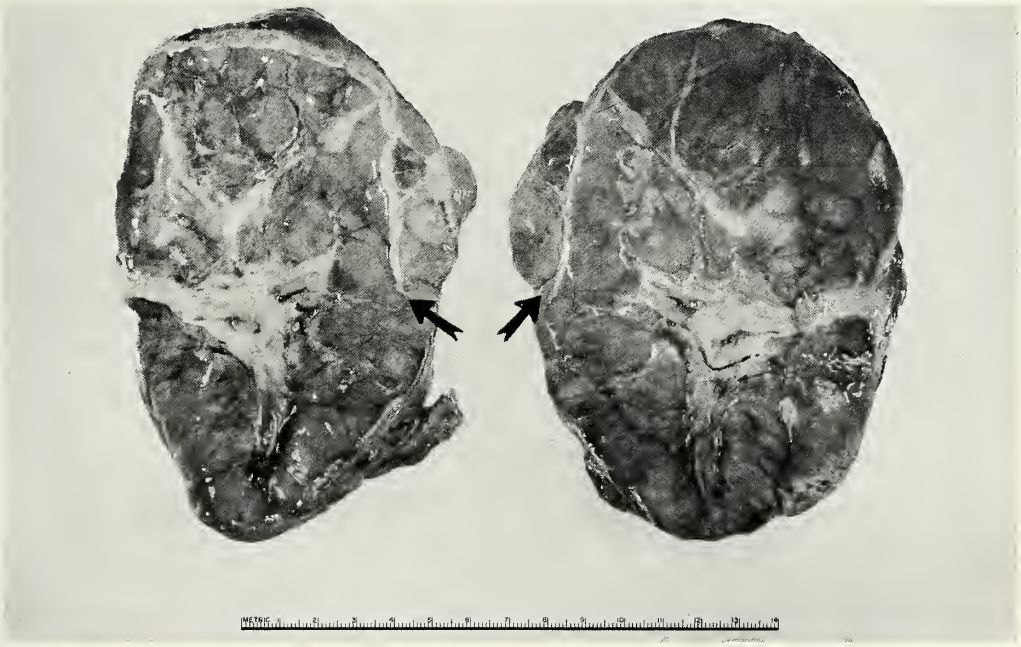

Figure 59. A gross photograph of a carcinoma arising from adenoma shows the capsule of the adenoma broken at one point. The tumor extending outside the capsule is undifferentiated carcinoma. A.F.I.P. Acc. No. 219764–27.

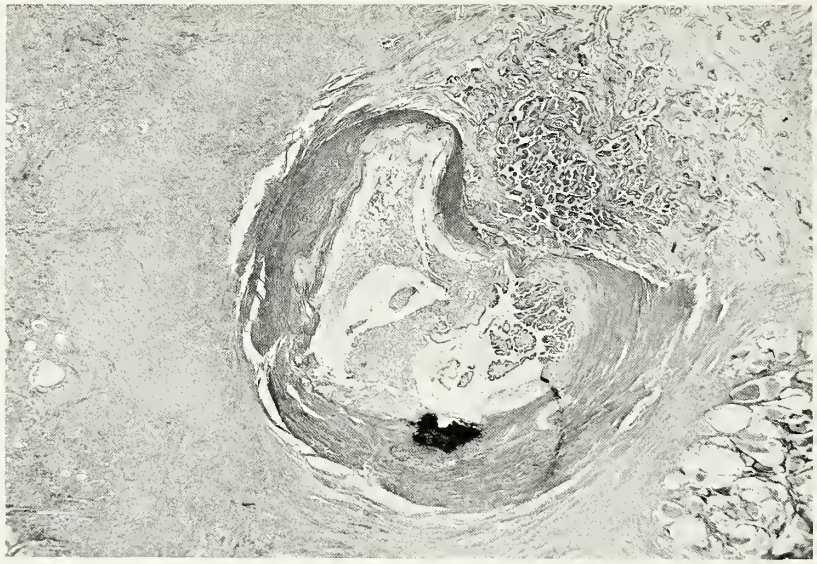

PAPILLARY ADENOCARCINOMA, SUGGESTING ORIGIN FROM ADENOMA

Figure 60. In this papillary adenocarcinoma, suggesting origin from adenoma, the central hyalinized and partly calcified focus contains papillary tumor which seems to be extending outward into the adjacent thyroid. Very few papillary adenocarcinomas suggest transition from a pre-existing benign tumor. × 15. A.F.I.P. Atlas No. 67-3-36.

## RELATIONSHIP TO OTHER ENDOCRINE DISEASE

Carcinoma or adenoma of the thyroid is not usually considered a component of the "multiple endocrine adenoma" syndrome although some surveys would include thyroid disease. Ballard and associates reviewed 85 cases of familial multiple endocrine adenoma-peptic ulcer complex and found 15 patients had thyroid disease, as follows: thyrotoxicosis, 2; thyroid carcinoma, 1; nonfunctioning adenoma, 8; colloid goiter, 3; struma lymphomatosa, 1. There is a distinct relationship between thyroid cancer and some types of endocrine disease. Pheochromocytoma occurring with medullary carcinoma of the thyroid is discussed on page 100; in the same syndrome there is an apparent association with parathyroid adenoma. Moreover, it has been said that a relationship exists between hyperparathyroidism and carcinoma of the thyroid even in the absence of the medullary carcinoma-pheochromocytoma combination. Ogburn and Black studied 230 cases of primary hyperparathyroidism and found that 4 were associated with papillary adenocarcinoma of the thyroid. Ellenberg and associates found an incidence of 7.5 per cent of carcinoma of the thyroid in 93 cases of hypercalcemia with calcium acting as a goitrogen. A few cases of Cushing's disease associated with, or produced by, anaplastic carcinoma of the thyroid have been reported (Anderson and Glenn). A relationship between the occurrence of carcinoma of the thyroid and carcinoma of the breast has been suggested by the authors' material, but has been difficult to prove. The development of pituitary tumors after ablation of the thyroid has been discussed under experimental tumors on page 59. Recently Albores-Saavedra and Durán have described an association of thyroid carcinoma of papillary or follicular type and chemodectoma.

### References

Albores-Saavedra, J., and Durán, M. E. Association of thyroid carcinoma and chemodectoma. Amer. J. Surg. (To be published)

Anderson, J. E., and Glenn, J. F. Cushing's syndrome associated with anaplastic carcinoma of the thyroid gland. J. Urol. 95:1–4, 1966.

Ballard, H. S., Fame, B., and Hartsock, R. J. Familial multiple endocrine adenoma-peptic ulcer complex. Medicine 43:481–516, 1964.

Ellenberg, A. H., Goldman, L., Gordon, G. S., and Lindsay, S. Thyroid carcinoma in patients with hyperparathyroidism. Surgery 51:708–717, 1962.

Ogburn, P. L., and Black, B. M. Primary hyperparathyroidism and papillary adenocarcinoma of thyroid: report of 4 cases. Mayo Clin. Proc. 31:295–298, 1956.

## GOITROGENS

Although both chemical and dietary goitrogens produce cancer experimentally, it is difficult to assess their possible role in the etiology of human thyroid cancer. There is no question, of course, that goitrogens cause a TSH-induced hyperplasia in the human thyroid, just as in experimental animals, and the hyperplasia is sometimes extreme. Russfield found increased amphophils in the hypophysis in patients with thyroid carcinoma, suggesting an increased production of thyrotropic hormone. A great many foods, drugs, minerals, and chemicals are goitrogenic, at least to a mild degree. With increasing possibilities of exposure to goitrogenic drugs and to goitrogenic air and food contaminants, it is quite likely that the role of such materials in the production of human thyroid cancer may become both more recognizable and more significant.

### References

Astwood, E. B. The natural occurrence of antithyroid compounds as a cause of simple goiter. Ann. Intern. Med. 30:1087–1103, 1949.

Means, J. H., DeGroot, L. J., and Stanbury, J. B. The Thyroid and Its Diseases. 3d ed. New York: McGraw-Hill Book Company, Inc., 1963.

Russfield, A. B. Histology of human hypophysis in thyroid disease–hypothyroidism, hyperthyroidism, and cancer. J. Clin. Endocr. 15:1393–1408, 1955.

## IONIZING RADIATION (Figures 61, 62)

Therapeutic irradiation of the neck in infants and children, for treatment of supposedly enlarged thymic glands or other conditions such as tuberculous adenitis (Cade) or medulloblastoma (Raventos and Duszynski), has led to a small but significant increased incidence of thyroid cancer (Pifer and Hempelmann). Doses ranged from 100 r to 600 r, or even more, and cancers appeared at adolescence or early adult life. While many of the lesions were papillary adenocarcinoma, other types of thyroid cancers occurred as well. Similar and even larger doses of irradiation to the thyroid of adults have not significantly increased the cancer incidence. In the past, thousands of cases of hyperthyroidism in adults have been treated with doses of x-irradiation up to several thousand roentgens, but carcinoma of the thyroid from this source is either extremely rare or nonexistent. Similarly, large doses of x-irradiation or radioiodine to ablate the thyroid in cardiac patients have failed to produce cancer of the thyroid.

Among survivors of the bombing in Hiroshima and Nagasaki who received radiation to the thyroid, there has been a slightly increased incidence of carcinoma of the thyroid (Socolow et al.).

Exposure to radioactive iodine for diagnosis has not been known to produce thyroid cancer. There is as yet no clear evidence that thyroid cancer is induced by therapeutic use of $I^{131}$ even though the doses at times have delivered many thousands of rads to the thyroid. On the other hand, following exposure to $I^{131}$ and other radioiodine isotopes as components of radioactive fall-out,

a population of Rongelap and Utrecht Islands showed nodules in the thyroid after about 10 years (Conard et al.) (fig. 61). The dose was about 300 r to the thyroid in adults and from 700 to 1400 r to the thyroid in children. Practically all the nodules have been in children, but not one of the children has as yet developed a malignant tumor. One papillary adenocarcinoma of the thyroid has developed in an adult Marshallese woman exposed to radioactivity.

According to Vickery, atypical and giant nuclei are the most striking feature of the late stage of radiation reaction in the thyroid (fig. 62), and they may be the only structural abnormality recognizable. Such bizarre nuclei may persist for many years after exposure to irradiation. Other possible chronic histologic alterations include a generalized tendency for the formation of smaller follicles, interstitial fibrosis, cytoplasmic swelling with vacuolation, and eosinophilic granularity.

Although irradiation to the adult gland may produce atypical cellular changes, cancer rarely has been reported. Wegmann reports 2 cases of sarcoma of the thyroid occurring 5 and 12 years after irradiation for follicular carcinoma; he found only 20 cases of thyroid cancer following radiation in adults.

HYPERPLASIA INDUCED BY RADIOIODINE

Figure 61. These hyperplastic foci were found in an adenomatous goiter excised from a child from the Marshall Islands who was exposed to about 1000 rads 10 years previously. × 40. A.F.I.P. Atlas No. 67-3-37.

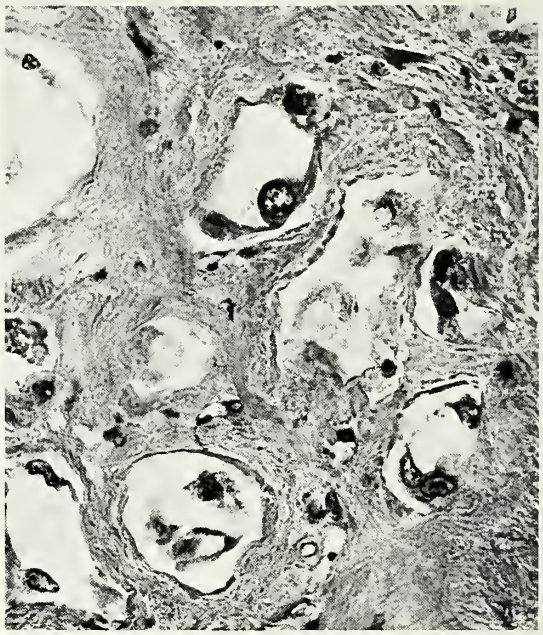

RADIATION REACTION IN THE THYROID

Figure 62. A 59-year-old diabetic with severe angina pectoris was treated with $I^{131}$ to produce hypothyroidism. He received 30 millicuries one year before death and 29 millicuries six months before death. At autopsy the 6 gm. thyroid was firm and adherent to the trachea. The stroma is fibrotic. The follicles are distorted, atrophic, and lined with bizarre cells. × 300. A.F.I.P. Atlas No. 67-3-102.

## References


Cade, S. Radiation induced cancer in man. Brit. J. Radiol. 30:393–402, 1957.

Conard, R. A., Rall, J. E., and Sutow, W. W. Thyroid nodules as a late sequela of radioactive fallout, in a Marshall Island population exposed in 1954. New Eng. J. Med. 274:1391–1399, 1966.

DeLawter, D. S., and Winship, T. Follow-up study of adults treated with roentgen rays for thyroid disease. Cancer 16:1028–1031, 1963.

Hanford, J. M., Quimby, E. H., and Frantz, V. K. Cancer arising many years after radiation therapy. Incidence after irradiation of benign lesions in the neck. J.A.M.A. 181:404–410, 1962.

Hempelmann, L. H., Pifer, J. W., Burke, G. J., Terry, R., and Ames, W. R. Neoplasms in persons treated with x-rays in infancy for thymic enlargement. A report of the third follow-up survey. J. Nat. Cancer Inst. 38:317–341, 1967.

Pifer, J. W., and Hempelmann, L. H. Radiation-induced thyroid carcinoma. Ann. N. Y. Acad. Sci. 114:838–848, 1964.

Raventos, A., and Duszynski, D. O. Thyroid cancer following irradiation for medulloblastoma. Amer. J. Roentgen. 89:175–181, 1963.

Socolow, E. L., Hashizume, A., Neriishi, S., and Niitani, R. Thyroid carcinoma in man after exposure to ionizing radiation. A summary of the findings in Hiroshima and Nagasaki. New Eng. J. Med. 268:406–410, 1963.

Vickery, A. L. Histologic effects of therapeutic doses of radioactive iodine. Bull. Path. (NRC) Wash. 8:8, 1967.

Wegmann, W. Zwei fälle von schilddrüsensarkom nach bestrahlung im erwachsenenalter. Schweiz. Med. Wschr. 92:39–48, 1962.


## RADIOIODINE UPTAKE IN THYROID CARCINOMA (Figures 63–65)

Fitzgerald studied 150 cases of thyroid cancer by autoradiography and found that 40 per cent of the cases showed organically bound radioiodine in the cancer. About two thirds of the follicular (fig. 64), one third of the solid, and one fourth of the papillary carcinomas gave positive autographs. In no case did the cancer concentrate more radioiodine than the normal thyroid (fig. 63).

Eleven of 12 adenomas showed spotty minimal concentration of the radioiodine which was always less than in the normal thyroid.

In general, the closer the follicles, cells, and colloid resemble the normal, the higher the percentage of positive autoradiographs (Fitzgerald et al.). Abnormal cellular rates are probably more significant in the formation of radioactive colloid in human pathologic processes than such factors as surface area, follicle diameter, number of follicle cells, or follicle cell height. Many thyroid

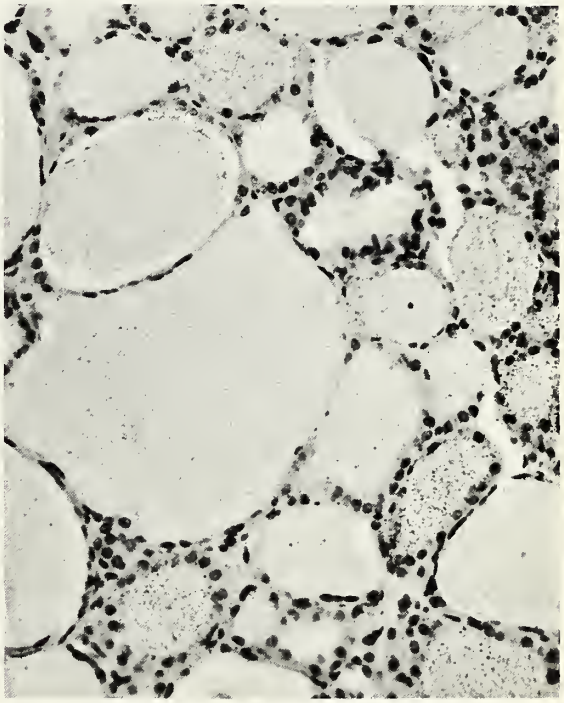

NORMAL THYROID

Figure 63. This autoradiograph shows the concentration of radioiodine in the colloid. Not all follicles have taken up the radioiodine to the same degree. × 250. A.F.I.P. Atlas No. 67-3-38.

carcinomas, including papillary, may be stimulated to take up additional radioiodine by use of TSH (Pochin).

Study of uptake of radioiodine by scintiscan, while useful in demonstrating metastases (fig. 65) and thyroid nodules, does not solve the problem of differentiating between benign and malignant nodules. While it is true that "cold" nodules are looked upon with greater suspicion, the fact that they are cold is not in itself diagnostic of cancer (fig. 30).

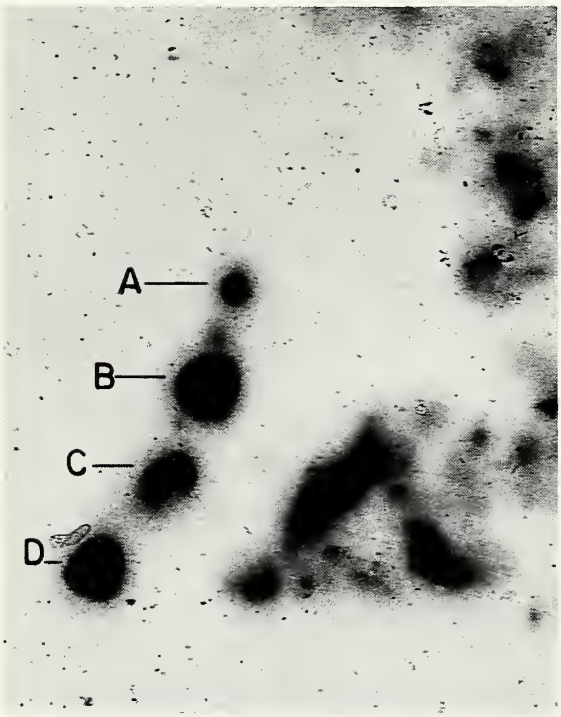


FOLLICULAR CARCINOMA

Figure 64. Another autoradiograph shows the uptake of radioiodine by follicular carcinoma of the thyroid. The autoradiograph was exposed for a longer time than the section in figure 63. Foci of follicular carcinoma are labeled A, B, C, and D. × 8. (This is figure 2 from De Amicis, E., Haley, K. H., and Cowing, R. F. Measurement and localization of an unknown dose of radioactive iodine in thyroid tissue. Amer. J. Clin. Path. 20:443–445, 1950.) A.F.I.P. Acc. No. 219764–29.

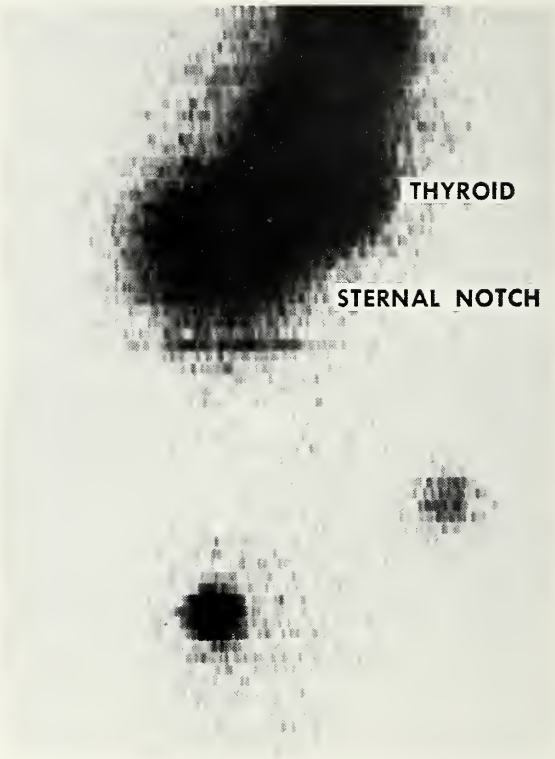


CARCINOMA

Figure 65. This scintiscan of a large carcinoma of the thyroid illustrates two metastases in the lung fields in the lower part of the scan. The tumor is a follicular carcinoma. A.F.I.P. Atlas No. 67-3–39.

## References

Fitzgerald, P. J. $I^{131}$ concentration and thyroid morphology, pp. 220–249. In: The Thyroid. Upton, N. Y.: Biology Department, Brookhaven National Laboratory Symposia in Biology No. 7, 1954.

———, Foote, F. W., Jr., and Hill, R. F. Concentration of $I^{131}$ in thyroid cancer, shown by radioautography. A study of 100 consecutive cases showing the relation of histological structure to the function of thyroid carcinoma. Cancer 3:86–105, 1950.

Pochin, E. E. Prospects from the treatment of thyroid carcinoma with radioiodine. Clin. Radiol. 18:113–125, 1967.

Shimaoka, K., and Sokal, J. E. Differentiation of benign and malignant thyroid nodules by scintiscan. Arch. Intern. Med. 114:36–39, 1964.

## CARCINOMA OF THE THYROID IN CHILDREN

Thyroid carcinoma in children is of particular interest for three reasons: (1) There has been a great recent increase in childhood carcinoma of the thyroid; (2) The clinical course of thyroid carcinoma is different from that in older individuals; and (3) Many of the carcinomas are related to previous irradiation. Numerous individual series have been reported, but the most comprehensive is that of Winship and Rosvoll who, for the past 20 years, have been tabulating and studying cases of thyroid carcinoma in children. Their cases were accumulated from all over the world. In 1961 they reported data on 562 collected cases of thyroid cancer in patients less than 15 years of age.

In those cases with adequate histories available, Winship and Rosvoll stated that 80 per cent had received irradiation to the region of the thyroid, usually in infancy. The radiation was most commonly administered for so-called enlarged thymus; other patients were treated with radiation for hypertrophied tonsils and adenoids, hemangiomas, nevi, eczema, medulloblastoma and other conditions, usually benign. The dose varied from 180 to 6000 roentgens, the average about 600 roentgens. The average interval between radiation and diagnosis of cancer was 8.7 years, with a range of 3.6 to 14 years.

Cancer of the thyroid is about twice as common in girls as in boys. The presenting symptom is either a mass in the thyroid or in a cervical lymph node. About three fourths of the cases have lymph node or more distant metastases at the time of the original diagnosis. The distant metastases are usually pulmonary. Although a few cases have been reported in which carcinoma was present at birth, most childhood carcinomas are found in older children and adolescents.

For the most part, the cancers are differentiated; about three fourths of them are papillary. Less than 10 per cent are undifferentiated carcinoma; spindle cell and giant cell carcinomas are rare.

Characteristically, thyroid carcinoma either in children or in young adults tends to run a slow clinical course even with metastases to lymph nodes or the lungs. A long survival may be expected for young patients with thyroid cancer, and a 5-year follow-up period is insufficient to determine the overall prognosis because in spite of the slow course, many of the young patients eventually die of the tumor. Winship and Rosvoll found that 18 per cent of the patients in their collected cases died from the thyroid cancer. The causes of death, as determined by autopsy, were usually extension of the carcinoma into the neck and involvement of the thorax.

Treatment for thyroid cancer in children must be based on the knowledge that the majority have metastases at the time the diagnosis is first made; also, consideration must be given to the low grade nature of the tumor in most instances. Although radical surgical excision is often impossible because of extension or metastasis, many of the patients seem to do well for a number of years with less than radical surgery, often combined with radiation or sometimes even with radiation alone. Regression of some metastases has occasionally been noted after treatment with thyroid hormone.

Rosvoll and Winship followed the cases of 69 women who had thyroid carcinoma in childhood and who subsequently became pregnant. They found that the thyroid cancer was not influenced by pregnancy and

stated that neither the history nor the presence of thyroid carcinoma is a cause for prevention of pregnancy or therapeutic abortion.

In a study of 70 women with cancer of the thyroid, Hill and associates agreed that neither pregnancy nor lactation seem to affect the course of the disease.

### References

Hill, C. S., Jr., Clark, R. L., and Wolf, M. The effect of subsequent pregnancy on patients with thyroid carcinoma. Surg. Gynec. Obstet. 122:1219–1222, 1966.

Rosvoll, R. V., and Winship, T. Thyroid carcinoma and pregnancy. Surg. Gynec. Obstet. 121:1039–1042, 1965.

Winship, T., and Rosvoll, R. V. Childhood thyroid carcinoma. Cancer 14:734–743, 1961.

## CARCINOMA

### PAPILLARY ADENOCARCINOMA*

(Figures 66–82; plates II–A, B, C; IV–A, B)

SYNONYMS AND RELATED TERMS: Papillary carcinoma; papillary cystadenocarcinoma; occult sclerosing carcinoma.

DEFINITION. A glandular carcinoma forming papillae.

GROSS. The gross appearance of papillary carcinoma varies with the size. Small tumors, often called occult sclerosing carcinomas (fig. 66), may be indistinguishable from a minute scar and only recognized as carcinoma by microscopic examination. Larger tumors typically have ill-defined borders, although some show partial encapsulation (figs. 67, 68). Cysts of varying size are rather common in the large tumors; some of the cysts reach 3 to 4 cm. in diameter. Unless hemorrhage has occurred into the cysts, they are filled only with thin, brown, watery fluid. Papillae project from the inner lining of the cysts. Papillae in the more solid portions of the tumors give the cut surface the appearance of the nap of a rug. Fibrosis is common and a central, irregular, dense scar is frequent. Calcium may deposit in the fibrotic areas, and calcification is sometimes so extensive that it is impossible to cut through the tumor until it has been decalcified. It may be recognizable radiologically. Ossification may also occur. While the relationship to a scar is very common and particularly evident in smaller tumors, only rarely is there a suggestion that the papillary cancer has arisen from what might have been remnants of a pre-existing benign adenoma (fig. 60).

NONENCAPSULATED SCLEROSING PAPILLARY CARCINOMA

Figure 66. A variant of papillary adenocarcinoma shows the sclerosis, the papillary foci, and the puckered appearance which are characteristic. × 15. (This is figure 4b from Hazard, J. B., Crile, G., Jr., and Dempsey, W. S. Nonencapsulated sclerosing tumors of the thyroid. J. Clin. Endocr. 9:1216–1231, 1949; also in Tr. Am. Goiter A. 281–296, 1949.) A.F.I.P. Acc. No. 219764–40.

*Preferred International Nomenclature

# PAPILLARY ADENOCARCINOMA

Figure 67. In this papillary adenocarcinoma, the cut surface shows the characteristic roughened appearance due to numerous papilliferous projections. A.F.I.P. Acc. No. 219764–49.

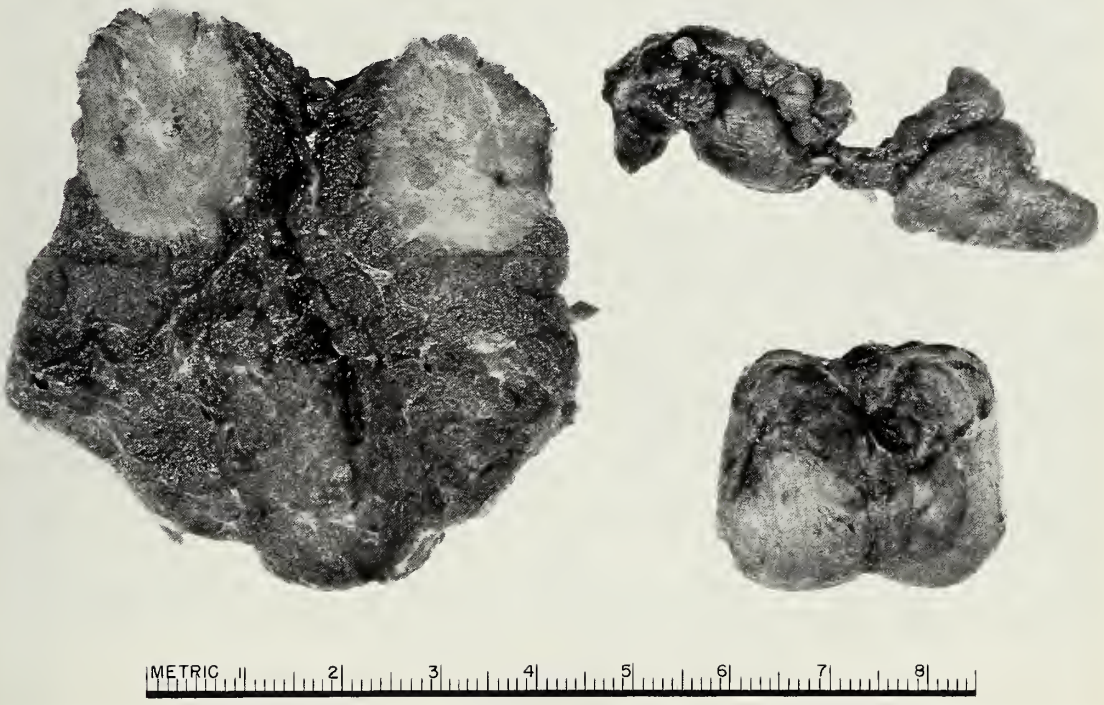


Figure 68. This papillary adenocarcinoma in the upper portion of a thyroid lobe metastasized to the cervical lymph nodes. Some of the lymph nodes were larger than the primary tumor. A.F.I.P. Acc. No. 219764–50.

MICROSCOPIC. The tumor epithelium is arranged on fibrovascular stalks which often project into cystic spaces (figs. 69–71; pl. II–A). Typically, the epithelium is single layered, but multilayering does occur. The tumor cells are cuboidal with a homogeneous, amphophilic cytoplasm surrounding a central ovoid nucleus (fig. 72). The nuclei often have the chromatin dispersed in fine grains giving a ground-glass appearance. Mitoses are extremely rare. There are many variations in the tumor pattern and in the individual cells. For example, there may be foci of more solid cell clusters or foci with follicle formation. Oxyphilic cells may be found in variable numbers, and small nests of tumor cells with clear cytoplasm are present in about one third of the cases. Of 226 cases of papillary carcinoma reviewed in our laboratory, 45 per cent showed squamous metaplasia (fig. 73; pl. IV–B), usually presenting as whorled nests of keratinized epithelium with infrequent distinct epithelial pearls. Squamous metaplasia is not apparently related to stromal inflammation.

About 40 per cent of papillary carcinomas contain laminated, calcific spherules, called psammoma bodies, calcospherites, or microliths (figs. 71, 74–77). They are basophilic, nonbirefringent, and measure from 5 to 100 micra in diameter. The spherules seem to arise between epithelial cells and often are found in the hyalinized stroma at the tip of a papilla (fig. 75). Psammoma bodies without surrounding tumor cells may be found in the thyroid tissue adjacent to, or even distant

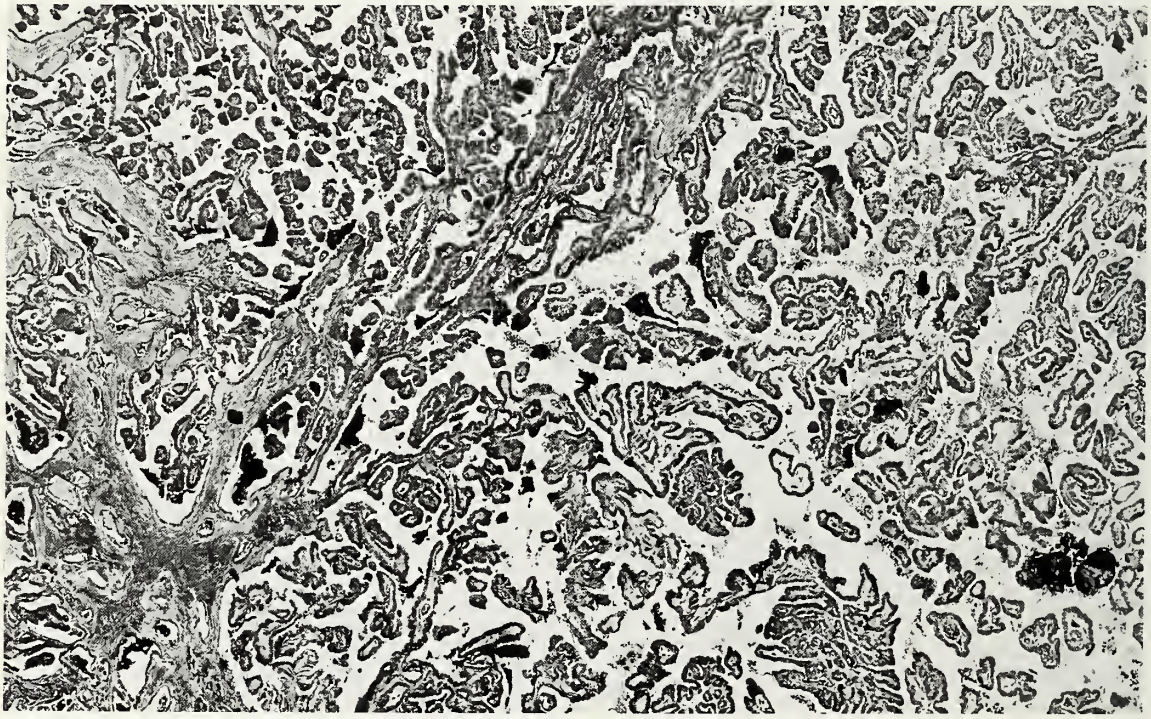

PAPILLARY ADENOCARCINOMA

Figure 69. A typical growth pattern is shown in this papillary adenocarcinoma. × 50. (This is figure 3 from Meissner, W. A., and Lahey, F. H. Cancer of the thyroid in a thyroid clinic. J. Clin. Endocr. 8:749–765, 1948; also in Tr. Am. Goiter A. 137–149, 1948.) A.F.I.P. Acc. No. 219764–51.

from, the cancer and in cervical lymph nodes. Such "naked" psammoma bodies probably represent foci of tumor dissemination with death of the cancer cells leaving only the fossil remains as evidence of the metastasis (fig. 77).

Lymphatic invasion was found in 75 per cent of our cases. If present at all, it usually occurs in multiple foci throughout the tumor and thus is a characteristic of the tumor rather than a chance finding. In contrast to follicular carcinoma in which blood vessel invasion is frequent, venous invasion was found in only 10 per cent of our cases and it was not always associated with lymphatic invasion. Multiple intraglandular foci of tumor are very common and should not be interpreted as multicentric origin, but rather as multiple foci of metastases, probably through lymphatic vessels.

NATURAL HISTORY. Papillary adenocarcinoma is the most common type of thyroid cancer. The majority of cases are rather evenly distributed from the third to the seventh decade. Papillary carcinoma is also relatively more frequent in young people as compared to undifferentiated carcinoma which is rare. As with most thyroid cancers, papillary carcinoma is several times more common in women than in men.

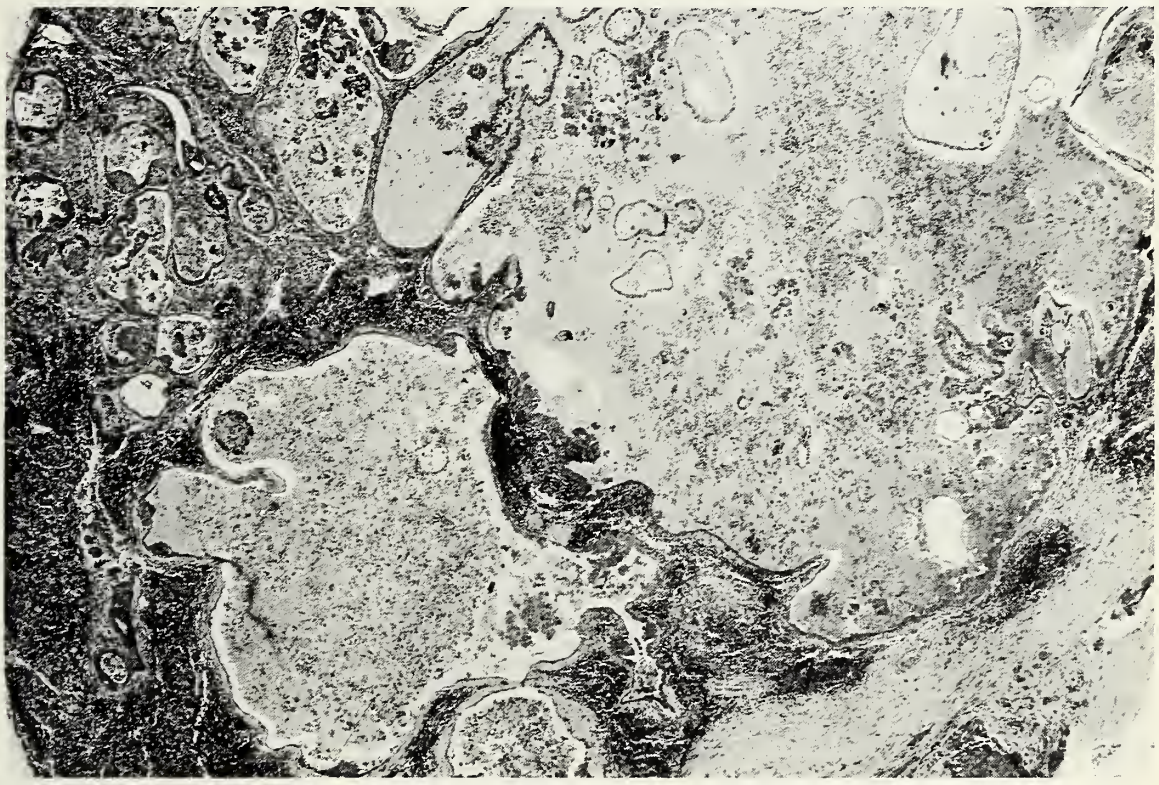

PAPILLARY ADENOCARCINOMA WITH CYSTIC FOCI

Figure 70. Papillary adenocarcinoma with cystic foci is often called papillary cystadenocarcinoma. Note the papilliferous extensions into cystic spaces. Compare this case with the adenomatous goiter with hyperplasia shown in figure 29. × 48. A.F.I.P. Acc. No. 219764–52.

Only a few papillary adenocarcinomas suggest an origin from a pre-existing benign tumor (fig. 60) and, as has been mentioned, papillary adenomas are quite rare. Many papillary adenocarcinomas do have an association with a focus of scarring or hyperplasia. The relationship of papillary adenocarcinoma to Graves' disease has been noted on numerous occasions; both the morphology of the tumor papillae and the individual tumor cells show considerable resemblance to papillary hyperplastic processes. There is no obvious relationship between papillary carcinoma and adenomatous goiter or chronic thyroiditis. Neither is there any evidence that papillary adenocarcinomas arise from remnants of thyroglossal duct or other primitive epithelium. Squamous metaplasia is rather common in both papillary carcinomas and thyroglossal duct epithelium, but true cilia, as are commonly seen in the thyroglossal duct cells, have not been found in the tumors. There is no predilection for the carcinoma to localize within the midline pyramidal lobe or isthmic regions of the gland. However, most carcinomas arising in thyroglossal duct remnants are papillary.

PAPILLARY ADENOCARCINOMA

Figure 71. This papillary adenocarcinoma has a typical cystic focus containing numerous psammoma bodies. × 50. A.F.I.P. Atlas No. 67-3-40.

## PAPILLARY ADENOCARCINOMA

Figure 72. Higher magnification of a papillary adenocarcinoma shows typical cells and frond. The individual cells usually are well differentiated and rarely show mitoses. × 300. A.F.I.P. Acc. No. 219764–56.

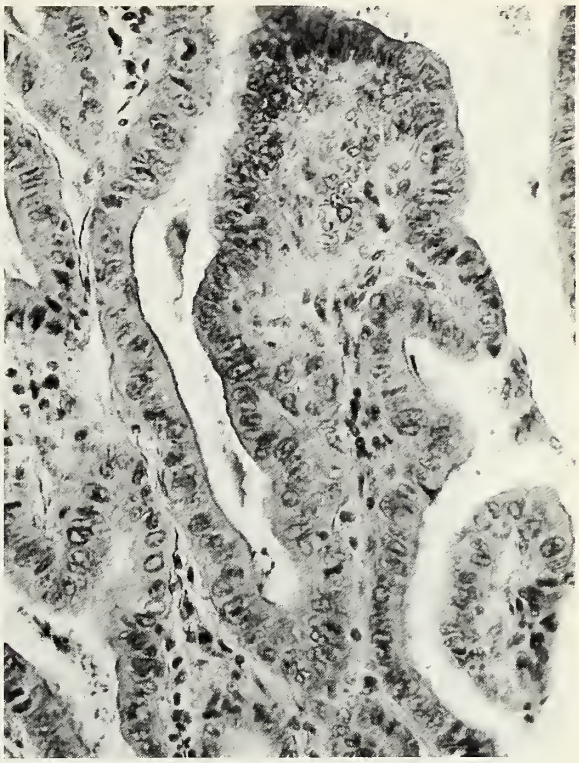

Fig. 72

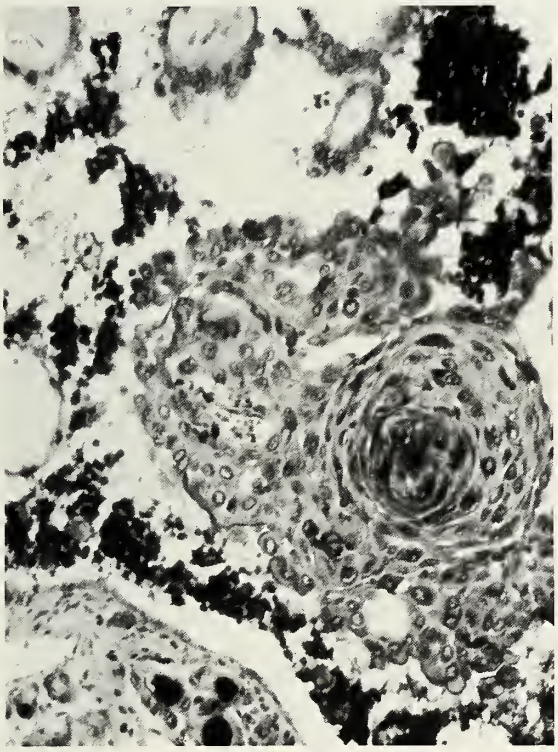

Fig. 73

## SQUAMOUS METAPLASIA

Figure 73. Foci of squamous metaplasia, sometimes with pearl formation, may be found in papillary adenocarcinoma. × 200. (This is figure 10 from Warren, S., and Feldman, J. D. The nature of lateral "aberrant" thyroid tumors. Surg. Gynec. Obstet. 88:31–44, 1949.) A.F.I.P. Acc. No. 219764–61.

## PAPILLARY ADENOCARCINOMA

Figure 74. In this junction of papillary adenocarcinoma with the adjacent gland, note the psammoma bodies both within the tumor and in the stroma of the adjacent gland. × 50. A.F.I.P. Atlas No. 67-3-41.

Fig. 75

Figure 75. Higher magnification of the fronds of a papillary adenocarcinoma shows the stroma of some of the fronds containing fibrosis. In other fronds there are calcifications and psammoma bodies. × 100. A.F.I.P. Atlas No. 67-3-42.

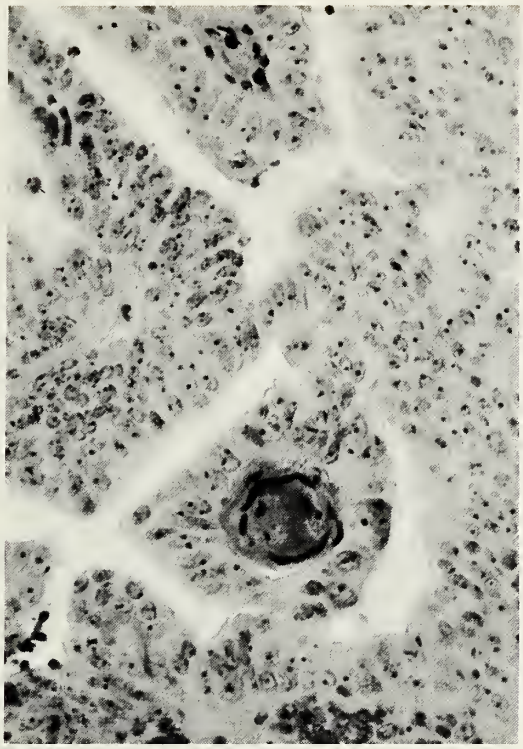

Fig. 76

## PSAMMOMA BODY OF PAPILLARY ADENOCARCINOMA

Figure 76. This psammoma body is lying in the middle of a nest of tumor cells. × 300. A.F.I.P. Acc. No. 219764–60.

## PSAMMOMA BODY OF PAPILLARY ADENOCARCINOMA

Figure 77. These psammoma bodies are lying in stroma in the gland adjacent to the tumor. The tumor cells surrounding these "naked" psammoma bodies presumably have died and have been removed. × 100. A.F.I.P. Atlas No. 67-3–44.

Fig. 77

While some papillary adenocarcinomas invade through the thyroid capsule (figs. 78–80) into the soft tissues (pl. II–B), muscles, or viscera of the neck, this method of extension is not as prominent as in more malignant tumors. Intraglandular metastases, in both the same lobe as the primary tumor and in the opposite lobe, are extremely common as demonstrated in whole section mounts of resected glands by Russell and associates.

Metastasis to cervical lymph nodes is so frequent that a large percentage of patients have involvement of the nodes at the time of the original diagnosis. Frazell and Foote, in a study of 393 cases, found that 50 per cent had metastases in cervical lymph nodes on initial admission, with bilateral involvement in 11 per cent. In our own laboratory, an analysis of 62 cases of radical neck dissection for papillary carcinoma showed that 76 per cent had metastatic tumor in one or more lymph nodes. Cervical lymph node metastases are often the presenting complaint, and the primary thyroid tumor from which the metastases arose may be so small that it can be identified only after studying multiple sections of the gland (pl. II–C).

Metastases by blood stream are less frequent, but do occur. Frazell and Foote found that 8.6 per cent of their cases had distant metastases on admission. In the series of Woolner and associates, 4 per cent showed pulmonary metastases (pl. IV–A).

The slow growth of both the primary tumor and its metastases—so slow that calcification and even ossification may occur—may raise doubts clinically concerning the accuracy of the diagnosis. A striking feature of papillary adenocarcinoma is the fact that sometimes both the primary tumor and the metastases remain stationary for long periods or even spontaneously regress for a time to reappear later. Starr reports a case in which pulmonary metastases of papillary cancer of the thyroid regressed after nine years of observation. It is not unusual for a tumor with many metastases to persist for years without causing death. Usually such persistent tumors retain the same morphologic pattern throughout their natural history; a few, however, after years of persistence change to a more malignant type of cancer, such as the giant cell carcinoma.

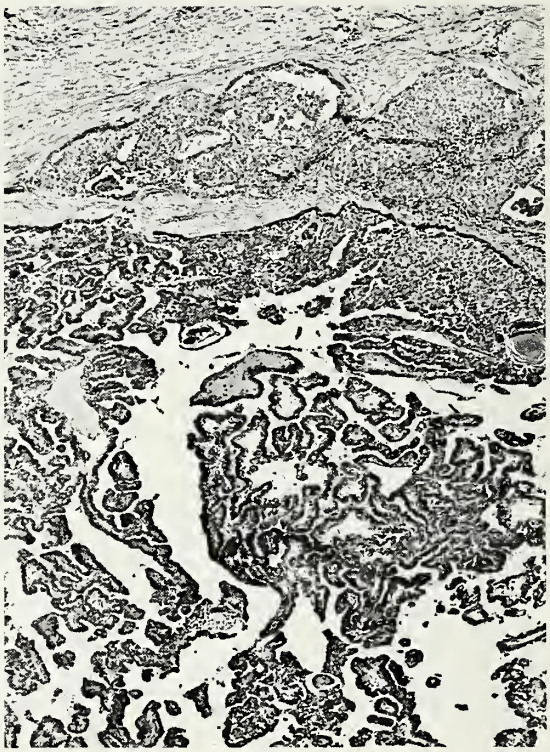

STROMAL INVASION BY PAPILLARY ADENOCARCINOMA

Figure 78. Direct stromal invasion by papillary adenocarcinoma may be the only evidence of malignant change. × 50. (This is figure 1 from Meissner, W. A., and Lahey, F. H. Cancer of the thyroid in a thyroid clinic. J. Clin. Endocr. 8: 749–765, 1948; also in Tr. Am. Goiter A. 137–149, 1948.) A.F.I.P. Acc. No. 219764–32.

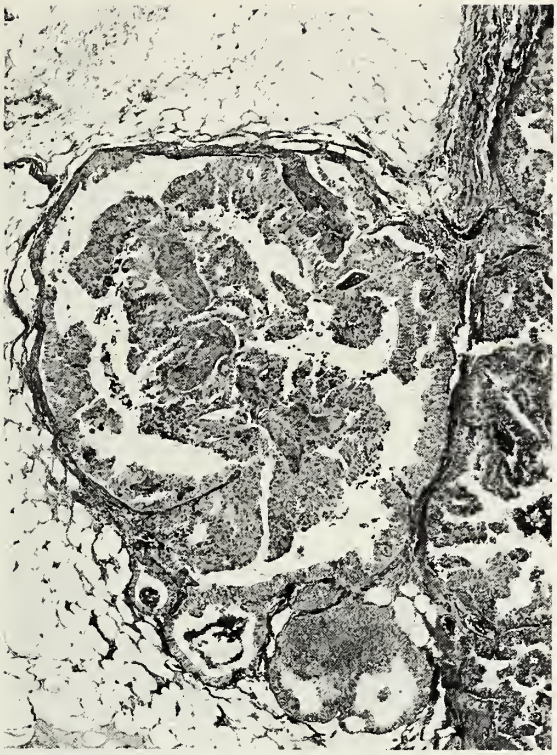

INVASION INTO FAT BY PAPILLARY ADENOCARCINOMA

Figure 79. A papillary adenocarcinoma may invade through the capsule of the thyroid into adjacent fat and other structures of the neck. × 50. (This is figure 7 from Lahey, F. H., Hare, H. F., and Warren, S. Carcinoma of the thyroid. Ann. Surg. 112:977–1005, 1940.) A.F.I.P. Acc. No. 219764–33.

PERINEURAL INVASION BY PAPILLARY ADENOCARCINOMA

Figure 80. This papillary adenocarcinoma infiltrated the nerve and perineural tissues. × 100. (This is figure 5c from Hazard, J. B., Crile, G., Jr., and Dempsey, W. S. Nonencapsulated sclerosing tumors of the thyroid. J. Clin. Endocr. 9:1216–1231, 1949; also in Tr. Am. Goiter A. 281–296, 1949.) A.F.I.P. Acc. No. 219764–41.

DIFFERENTIAL DIAGNOSIS. The clinical differential diagnosis includes benign tumor, thyroiditis, adenomatous goiter, and other types of cancer, primary or metastatic. In addition, since metastasis in cervical lymph nodes may be the presenting complaint, there may be confusion with various causes of cervical lymphadenopathy, branchial cleft cyst, and neurofibroma. Pathologic examination with frozen section readily excludes the majority of the possibilities.

Grossly, the occult sclerosing variant (fig. 66) may resemble a small scar in an otherwise uniform gland; such scars should always be examined carefully.

The main problem in the microscopic differential diagnosis is with papillary hyperplasia. Horn emphasizes very wisely the importance of a knowledge of the clinical history and gross pathologic description in recognizing extremes of hyperplasia that may resemble cancer. Differentiation of papillary carcinoma from diffuse hyperplasia, as in Graves' disease, is not usually difficult, but some nodules of adenomatous goiter are cystic and have hyperplastic papillary foci

closely resembling tumor. Since papillary adenocarcinomas show very little cellular or nuclear pleomorphism and only rare mitoses, the best evidence of cancer is invasion—of stroma, of capsule, of lymphatic vessels, or of blood vessels. Invasion is most easily identified at the periphery of the tumor, so sections should be taken from these areas rather than centrally. Another helpful finding is the presence of psammoma bodies. Batsakis found psammoma bodies in 1.6 per cent of non-neoplastic thyroids, while Klinck and Winship found them in only 1 of 2,153 noncancerous glands. Certainly the finding of even a single psammoma body should initiate a careful search for papillary carcinoma. Psammoma bodies occur in other types of thyroid cancer, but less frequently than in the papillary type. Holtz and Powers state that calcifications typical of psammoma bodies may be recognizable by x-ray examination and that they may be diagnostic of papillary thyroid cancer.

Fisher and Hellstrom discuss the occasional problem of the differential diagnosis of papillary carcinomas of the thyroid and salivary gland origin. They state that the ferric ferricyanide staining reaction is positive in the thyroid and in some of its tumors, but is negative in salivary glands and their tumors.

The rare nest of non-neoplastic follicles in cervical lymph nodes has been discussed on page 26. It cannot be overemphasized that such inclusions are rare and are *non-papillary*. A cluster of papillary epithelium in cervical lymph nodes must be considered to be metastatic cancer until proved otherwise.

PROGNOSIS. The microscopic appearance of papillary carcinoma is of little value in prognosis nor is the presence or number of psammoma bodies. Of most importance in determining prognosis is the stage of the tumor at the time of the initial diagnosis. If the tumor is small and fibrotic (occult sclerosing carcinoma), the prognosis usually is excellent since metastases are infrequent and local excision generally is curative. With larger tumors however, the probability of extension into the tissues adjacent to the thyroid, as well as into other portions of the thyroid itself, is greater. The probability of lymph node and distant metastasis also becomes greater. Since the tumor is characteristically slow growing, 5-year survival rates are insufficient for evaluation and 10 or 15-year survival rates may not show the true prognosis. Even in the presence of untreatable metastases, the clinical course is often prolonged and many patients have been known to live with the disease for 20 or more years.

Woolner and associates have emphasized that the more local extension, the worse the prognosis, and they found the 10-year survival rate of all patients with papillary carcinoma to be 82 per cent. The prognosis is better in patients under 40 years of age than in those over 40 years of age. With extrathyroidal extension, the 10-year survival rate dropped to 54 per cent. Of Woolner's series of 541 cases of papillary carcinoma, 31 patients were known to have died with and from the tumor. Usually, deaths were in patients with extrathyroidal extension. In the 70 fatal cases studied by Tollefsen and associates, death was caused by: local recurrence in the neck, 40 per cent; pulmonary metastases, 31 per cent; brain metastases, 10 per cent; bone metastases, 10 per cent; local recurrence plus pulmonary metastases, 7 per cent; and hepatic metastases, 1 per cent. Patients rarely die from lymph node metastases alone.

TREATMENT. The usual initial treatment is surgery, but there is no general agreement on further treatment. Crile believes that radical neck dissection and total thyroidectomy need not be employed routinely because conservative operations and thyroid feeding give such good results. Black and associates advocate removal of all thyroid tissue except a remnant because of frequent multicentricity of the tumor, and Beahrs and associates state that radical resection of the neck is not indicated in the absence of enlarged nodes. Tollefsen and associates insist a general relationship exists between inadequate initial treatment of the thyroid gland and cervical lymph nodes and subsequent death from thyroid cancer.

Postoperative roentgen ray therapy may be of considerable value if the tumor cannot be completely excised surgically or if it recurs (figs. 81, 82). As a rule, it has been felt that radioiodine has little value in the treatment of papillary carcinoma. Pochin, however, has shown that by stimulating the tumors to greater activity with TSH, both the primary tumor and metastases can be induced to take up sufficient radioiodine to be of therapeutic value; he believes his results are comparable to those obtained by surgical treatment.

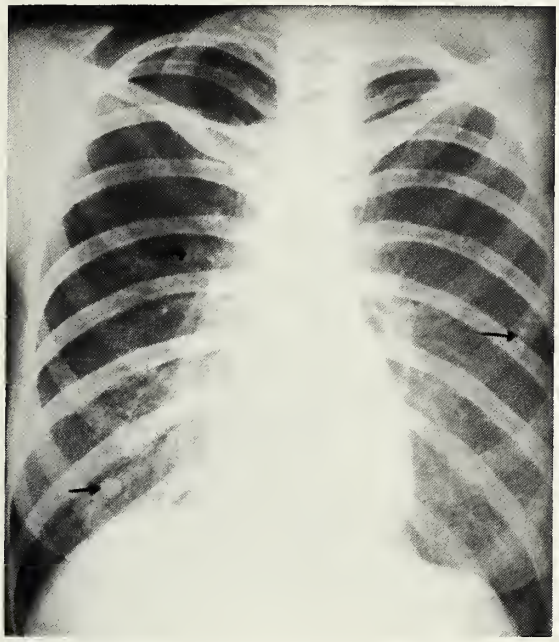

METASTATIC PAPILLARY ADENOCARCINOMA WITH REGRESSION

(Figures 81 and 82 are from the same case)

Figure 81. This roentgenogram shows lung metastases from a papillary adenocarcinoma of the thyroid. Arrows point to tumor nodules which appeared before radiation therapy. (This is figure 3a from Hare, H. F., and Newcomb, R. V. Carcinoma of the thyroid in children. Radiology 54:401–407, 1950.) A.F.I.P. Acc. No. 219764–62.

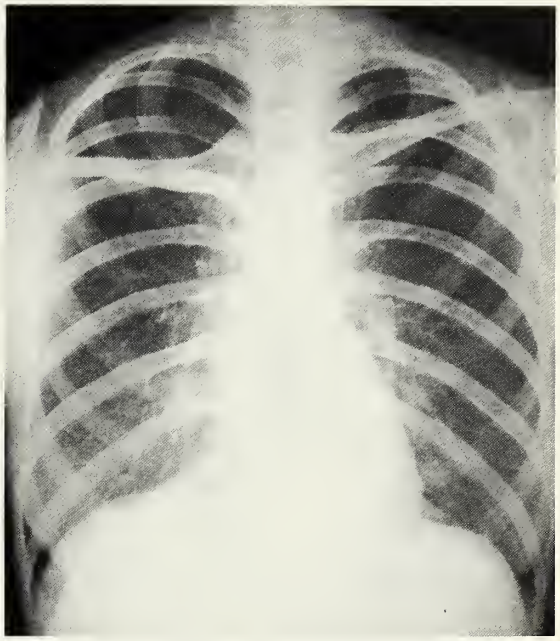

METASTATIC PAPILLARY ADENOCARCINOMA WITH REGRESSION

Figure 82. Another roentgenogram of the same patient as shown in figure 81 was taken seven years later and after radiation therapy. Metastases are no longer visible. In some instances, similar metastases apparently have disappeared without radiation therapy. (This is similar to figure 3b from Hare, H. F., and Newcomb, R. V. Carcinoma of the thyroid in children. Radiology 54:401–407, 1950.) A.F.I.P. Acc. No. 219764–63.

Because of the possibility of hormone dependence of the tumor, most patients with papillary carcinoma are given continuous suppressive doses of thyroid hormone.

Most well differentiated carcinomas of the thyroid are neither purely papillary nor purely follicular, but an admixture of both elements in varying proportions. In studying any series of differentiated carcinomas, one is impressed that there are all degrees of transition from purely papillary tumors to purely follicular carcinomas. This is not surprising since both tumors arise from the same follicular cells. In the series of Russell and associates, only 2.5 per cent of the differentiated carcinomas were purely follicular and only about 22 per cent were purely papillary. The term **mixed papillary and follicular carcinoma** (figs. 83–85) has been used frequently in recent years and could well be applied to the majority of differentiated thyroid carcinomas. Some investigators have felt that all carcinomas with any mixture of papillary and follicular elements should be classified as papillary, since they believe that the behavior will be that of papillary cancer. Others do not agree with such an all-inclusive concept and, in fact, there is no general agreement about which tumors should be placed in the "mixed" category. It is the authors' feeling that the tumors should be classified according to the predominant pattern, with a mention of the minority component. Any thyroid cancer

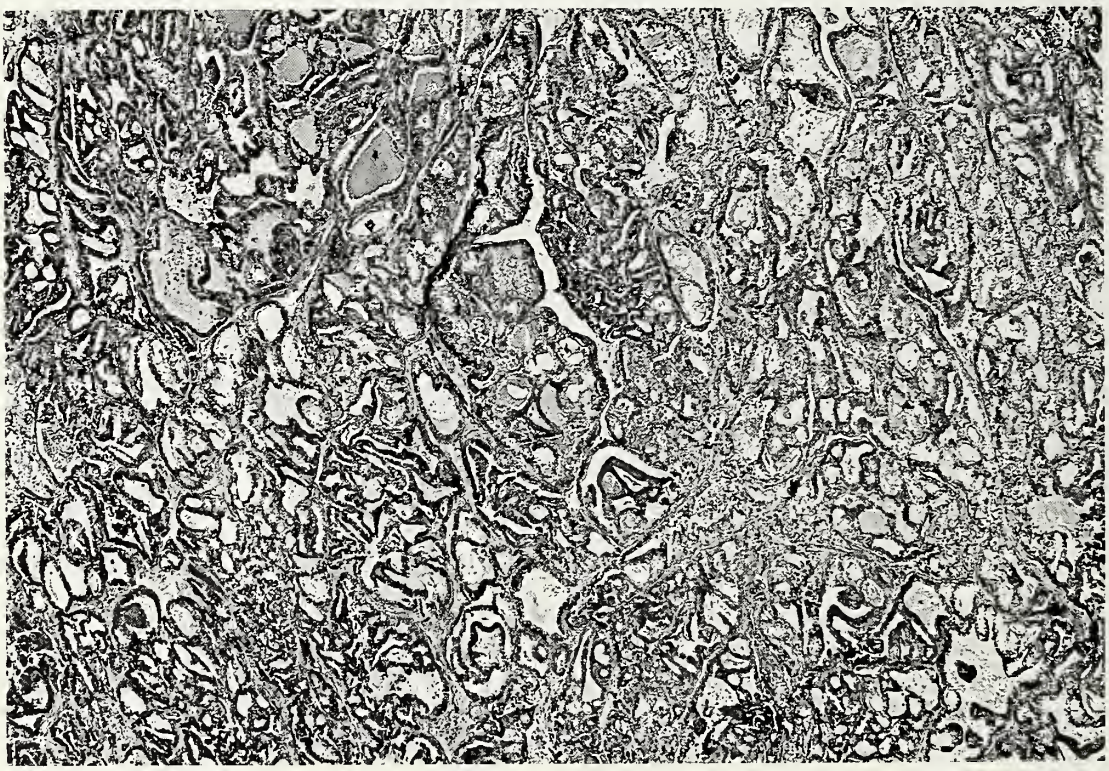

MIXED PAPILLARY AND FOLLICULAR CARCINOMA

Figure 83. A combination of mixed papillary and follicular carcinoma has a predominance of follicular elements. × 50. (This is figure 4 from Meissner, W. A., and Lahey, F. H. Cancer of the thyroid in a thyroid clinic. J. Clin. Endocr. 8:749–765, 1948; also in Tr. Am. Goiter A. 137–149, 1948.) A.F.I.P. Acc. No. 219764–44.

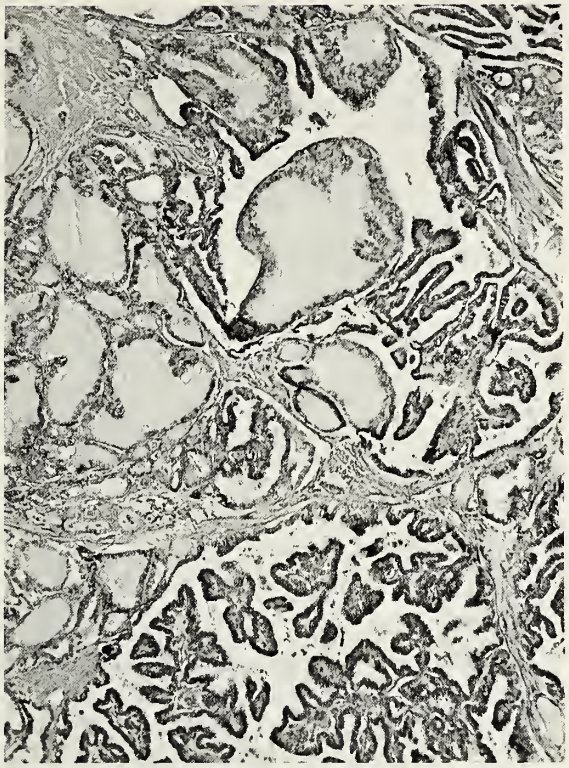

MIXED PAPILLARY AND FOLLICULAR CARCINOMA

Figure 84. This photomicrograph of mixed papillary and follicular carcinoma reveals a predominantly papillary pattern but has a few well defined follicular foci. × 50. A.F.I.P. Atlas No. 67-3-51.

MIXED PAPILLARY AND FOLLICULAR CARCINOMA

Figure 85. Another case of mixed papillary and follicular carcinoma shows a predominantly follicular pattern; nevertheless it contains a few foci of papillary carcinoma with psammoma bodies. × 50. A.F.I.P. Atlas No. 67-3-52.

containing follicular elements should have the feature noted, since the presence of the follicles indicates a greater likelihood that the tumor will take up radioiodine. The more purely papillary the tumor, the less aggressive, as a rule, whereas tumors that are predominantly follicular tend to show more aggression and greater frequency of blood vessel invasion.

## References

Batsakis, J. G., Nishiyama, R. H., and Rich, C. R. Microlithiasis (calcospherites) and carcinoma of the thyroid gland. Arch. Path. 69:493–498, 1960.

Beahrs, O. H., and Woolner, L. B. The treatment of papillary carcinoma of the thyroid gland. Surg. Gynec. Obstet. 108:43–48, 1959.

Black, B. M., Kirk, T. A., Jr., and Woolner, L. B. Multicentricity of papillary adenocarcinoma of the thyroid: influence on treatment. J. Clin. Endocr. 20:130–135, 1960.

Crile, G., Jr. Endocrine dependency of papillary carcinomas of the thyroid. J.A.M.A. 195:721–724, 1966.

———. Survival of patients with papillary carcinoma of the thyroid after conservative operations. Amer. J. Surg. 108:862–866, 1964.

Fisher, E. R., and Hellstrom, H. R. Differential diagnosis of papillary carcinomas of thyroid and salivary gland origin. Amer. J. Clin. Path. 37:633–638, 1962.

Frazell, E. L., and Foote, F. W., Jr. Papillary cancer of the thyroid; a review of 25 years of experience. Cancer 11:895–922, 1958.

Gricouroff, G. La thyroïdose métastatique bénigne et ses tumeurs. Bull. Ass. Franc. Cancer 49:300–311, 1962.

Hazard, J. B. Small papillary carcinoma of the thyroid. A study with special reference to so-called non-encapsulated sclerosing tumor. Lab. Invest. 9:86–97, 1960.

Holtz, S., and Powers, W. E. Calcification in papillary carcinoma of the thyroid. Amer. J. Roentgen. 80:997–1000, 1958.

Horn, R. C., Jr. Problems in the pathologic diagnosis of carcinoma of the thyroid. Arch. Path. 69:481–492, 1960.

Klinck, G. H., and Winship, T. Psammoma bodies and thyroid cancer. Cancer 12:656–662, 1959.

Meissner, W. A., and Adler, A. Papillary carcinoma of the thyroid. Arch. Path. 66:518–525, 1958.

———, and Legg, M. A. Persistent thyroid carcinoma. J. Clin. Endocr. 18:91–98, 1958.

———, Colcock, B. P., and Achenbach, H. The pathologic evaluation of radical neck dissection for carcinoma of the thyroid gland. J. Clin. Endocr. 15:1432–1436, 1955.

Pochin, E. E. Prospects from the treatment of thyroid carcinoma with radioiodine. Clin. Radiol. 18:113–125, 1967.

Russell, W. O., Ibanez, M. L., Clark, R. L., and White, E. C. Thyroid carcinoma. Classification, intraglandular dissemination, and clinicopathological study based upon whole organ sections of 80 glands. Cancer 16:1425–1460, 1963.

Smedal, M. I., Salzman, F. A., and Meissner, W. A. The value of 3 mv. roentgen-ray therapy in differentiated thyroid carcinoma. Amer. J. Roentgen. 99:352–364, 1967.

Starr, P. Pulmonary metastases of papillary cancer of the thyroid gland. Regression after nine years' observation. J.A.M.A. 180:978, 1962.

Tollefsen, H. R., DeCosse, J. J., and Hutter, R. V. Papillary carcinoma of the thyroid. A clinical and pathological study of 70 fatal cases. Cancer 17:1035–1044, 1964.

Woolner, L. B., Beahrs, O. H., Black, B. M., McConahey, W. M., and Keating, F. R., Jr. Classification and prognosis of thyroid carcinoma. A study of 885 cases observed in a thirty year period. Amer. J. Surg. 102:354–387, 1961.

———, Lemmon, M. L., Beahrs, O. H., Black, B. M., and Keating, F. R., Jr. Occult papillary carcinoma of the thyroid gland: a study of 140 cases observed in a 30-year period. J. Clin. Endocr. 20:89–105, 1960.

## FOLLICULAR CARCINOMA (Figures 86–100; plates I–D; II–D)

SYNONYMS AND RELATED TERMS: *Alveolar adenocarcinoma;* adenocarcinoma; alveolar carcinoma; trabecular carcinoma; malignant adenoma; metastasizing goiter; carcinoma arising in adenoma; angioinvasive adenoma; Langhans' wuchernde struma.

DEFINITION. A glandular carcinoma forming follicles.

GROSS. Some follicular carcinomas are indistinguishable grossly from follicular adenomas, since their invasive nature is not extensive enough to be seen grossly and is evident only on microscopic examination. With other follicular carcinomas, the invasion is evident grossly as well as microscopically (fig. 86). Local invasion may be limited to

FOLLICULAR CARCINOMA

Figure 86. This follicular carcinoma extended through the entire specimen. The gross appearance of follicular carcinoma is similiar to that of typical adenocarcinomas of many other organs. A.F.I.P. Acc. No. 219764–42.

the adjacent thyroid or it may be so extensive that structures beyond the thyroid such as the trachea are involved. As a rule, follicular carcinomas are fleshy with a fibrous, sometimes calcified, center often resembling a scar. Sometimes, there are remnants of a nodule within the carcinoma which suggest a pre-existing adenoma. In addition to central fibrosis, follicular carcinomas undergo the same range of retrogressive changes as described for follicular adenomas. With the larger tumors, hemorrhage and infarction are common. Surgical specimens of the tumors vary from 1 to 10 cm. or more in diameter. Blood vessel invasion may be obvious grossly.

MICROSCOPIC. The microscopic patterns of follicular carcinoma have a range comparable to that described for follicular adenomas. Some of the tumors are nearly solid and form only small or abortive follicles. At the other extreme, some of the carcinomas are so well differentiated that the neoplastic follicles are quite like those of the normal thyroid. The more the follicles resemble those of the normal thyroid, the more likely they are to contain colloid. A few follicular carcinomas form follicles that are larger than those of the normal thyroid and resemble adenomatous goiter. It is possible to subdivide follicular carcinomas into many categories based on the degree of follicle formation, just as may be done with follicular adenomas, but there is little advantage gained even though it seems that tumors with less well developed follicles tend to be slightly more aggressive and invasive. A microfollicular variant with small masses of rather tightly packed cells is sometimes called Langhans' wuchernde struma.

Admixtures of other patterns of thyroid carcinoma, such as papillary or undifferentiated, are common. In fact, if many sections of a follicular carcinoma are examined, what was thought to be pure follicular carcinoma frequently turns out to be mixed with other growth patterns. Pure follicular carcinomas are relatively rare, as shown by Russell and associates who found a consistently follicular pattern in the gland and in the tumor extensions and metastases in only 2.5 per cent of 80 thyroid cancers. Smedal and associates found a comparable low incidence of pure follicular carcinoma.

The epithelial cells of follicular carcinomas for the most part show relatively little pleomorphism and infrequent mitoses. Often the cells lining the neoplastic follicles are nearly identical to functioning thyroid epithelium; in fact, usually they can be shown to function by autoradiography in that they take up radioiodine (figs. 64, 65). Oxyphilic change of tumor cells is common and may be focal or diffuse. Psammoma bodies are sometimes present.

While all follicular carcinomas by definition must show some degree of invasiveness in order to be recognized as carcinoma, extent of the invasion may vary considerably (figs. 87–90). Some follicular carcinomas show no gross invasion and are similar to benign adenomas except for microscopic findings of invasion of the capsule, blood vessels, or lymphatics. Such tumors have been called malignant adenoma, adenoma with invasion, angioinvasive adenoma, or potentially malignant adenoma. None of these terms is entirely satisfactory; therefore, it seems more practical just to classify these tumors as follicular carcinomas with an early stage of invasion.

Blood vessel invasion is more prominent in follicular than in papillary carcinomas; it is usually, but not invariably, associated with capsular or lymphatic invasion.

FOLLICULAR CARCINOMA

Figure 87. This follicular carcinoma extended into the capsule. The relationship of the tumor to the numerous blood vessels is striking. × 30. (From Meissner, W. A. Abstract from Seminar on Tumors of the Neck, American Society of Clinical Pathologists, 1955.) A.F.I.P. Atlas No. 67-3-45.

BLOOD VESSEL INVASION

Figure 88. This follicular carcinoma depicts invasion of a blood vessel in the capsule. × 150. A.F.I.P. Acc. No. 219764-34.

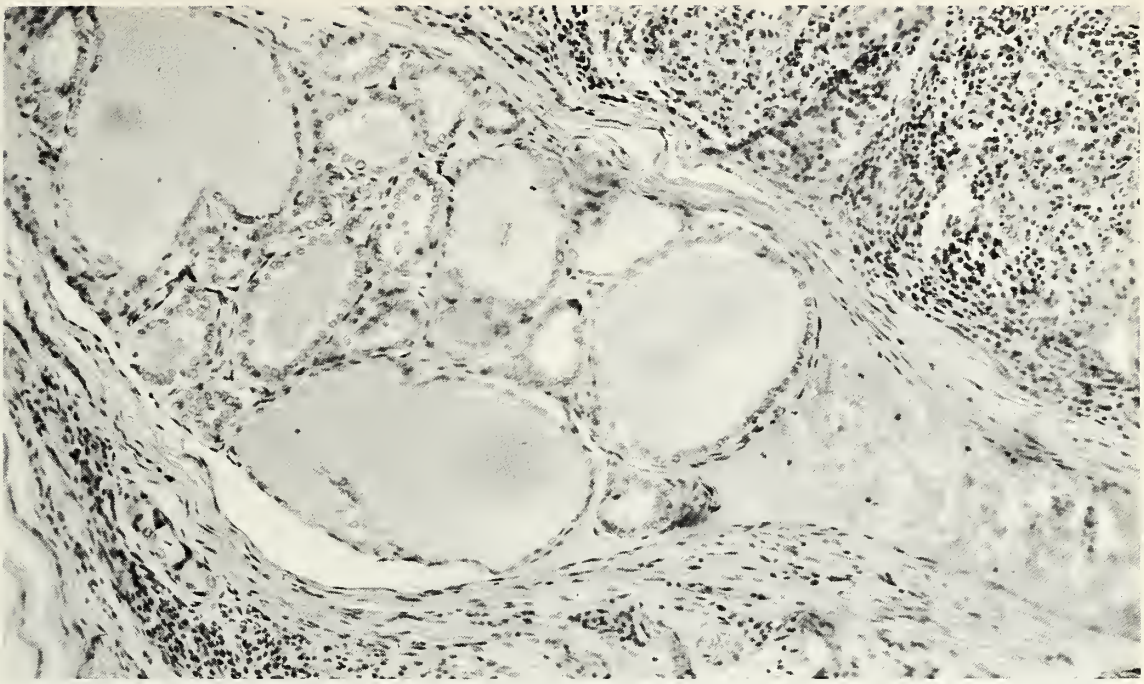

## BLOOD VESSEL INVASION

Figure 89. This shows blood vessel invasion by a well differentiated follicular carcinoma. × 125. (This is figure 12 from Warren, S., and Feldman, J. D. The nature of lateral "aberrant" thyroid tumors. Surg. Gynec. Obstet. 88: 31–44, 1949.) A.F.I.P. Acc. No. 219764–35.

## LYMPHATIC INVASION

Figure 90. A photomicrograph shows invasion of lymphatic vessels by a follicular carcinoma. × 300. (This is figure 14 from Warren, S., and Feldman, J. D. The nature of lateral "aberrant" thyroid tumors. Surg. Gynec. Obstet. 88:31–44, 1949.) A.F.I.P. Acc. No. 219764–39.

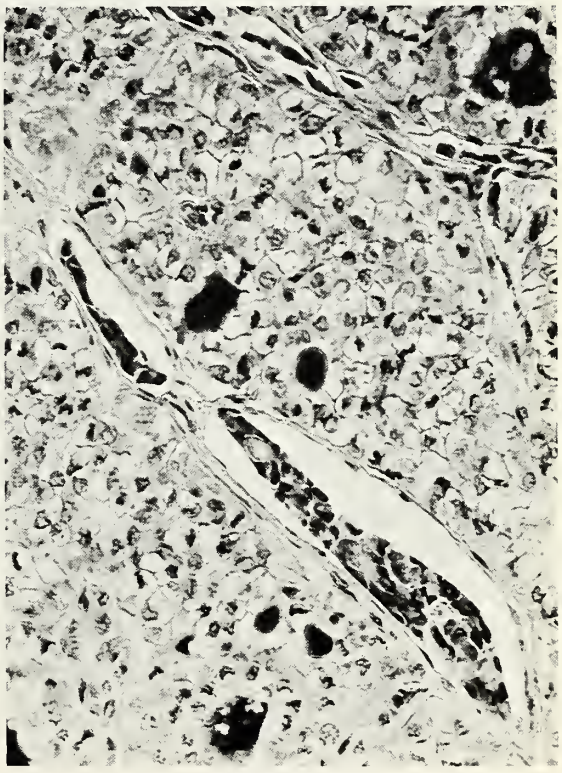

Fig. 90

NATURAL HISTORY. Follicular carcinoma is several times more common in females than in males. It occurs at any age although the incidence increases with age. A history of goiter for 10 or more years before surgery is frequent. From the clinical course, as well as from the gross and microscopic features, follicular carcinomas often seem to have originated from a pre-existing benign adenoma. Such a transition is very difficult to prove in an individual case however. While transition is quite possible, it certainly does not occur as frequently as was previously thought. The fact that there is a similar growth pattern in benign and malignant tumors is not in itself proof of transition from one to the other; nor is the fact that the tumor has been present for a considerable time conclusive evidence that it had once been benign. Surgical excision of thyroid nodules should be primarily for diagnostic purposes and only secondarily for the prevention of transition of a benign tumor to cancer at some future date.

Even though the growth rate of follicular carcinomas generally is slow, these tumors are quite capable of metastasizing by blood stream and lymphatics and may invade the local tissues extensively. Metastases to bone and lung may not be evident for a considerable time and, even when evident, may remain relatively dormant for long periods

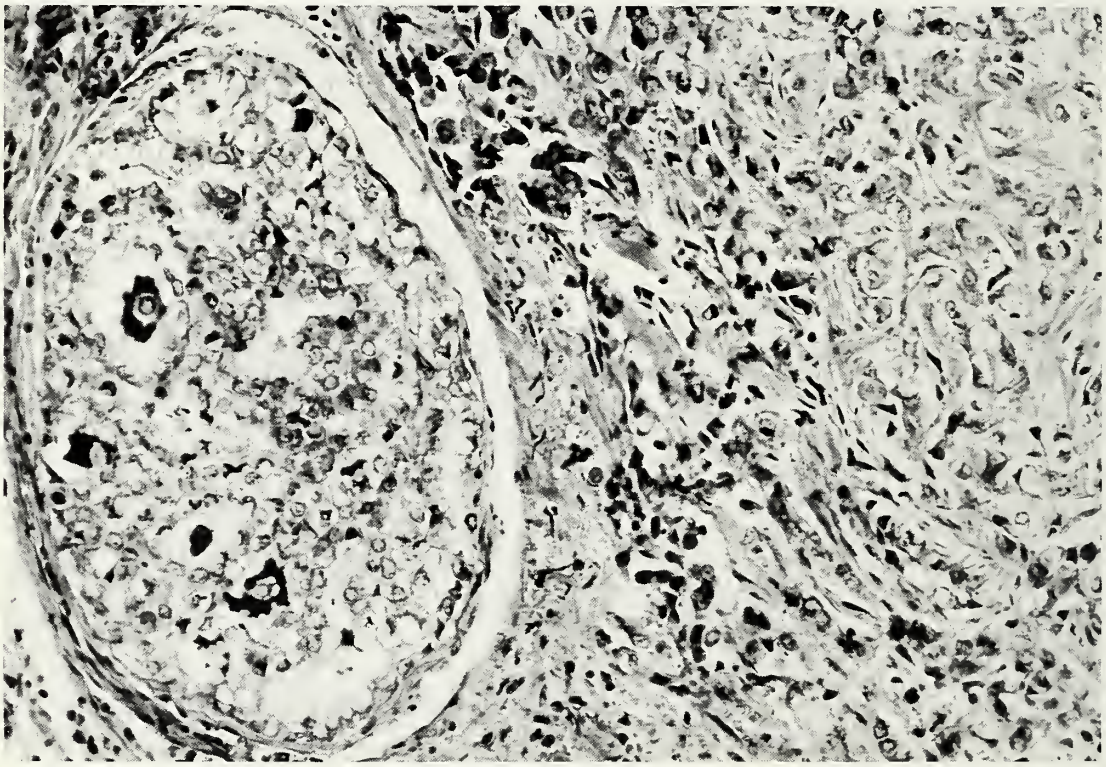

FOLLICULAR CARCINOMA WITH METASTASES

(Figures 91 and 92 are from the same case)

Figure 91. This specimen of follicular carcinoma with blood vessel invasion was removed from the thyroid gland of an 8-year-old girl in 1934. Five years later, lung metastases were noted in both lower lobes, although the local tumor of the thyroid apparently had been cured by surgery and irradiation. × 250. A.F.I.P. Acc. No. 219764–45.

(figs. 91, 92). Thyroid tissue, often normal appearing, discovered in bone and other parts of the body distant from the thyroid, represents a metastasis from a well differentiated follicular carcinoma ("benign metastasizing goiter") (fig. 93). Careful examination of the thyroid in such cases usually will reveal a cancer nodule—sometimes very small. Lymph node metastases are not so prominent as in papillary carcinomas, but certainly occur.

Silliphant and associates analyzed the sites of metastasis in 18 cases in which the patient died from follicular carcinoma of the thyroid and found that 56 per cent had lung metastases, 89 per cent had lymph node metastases, and 17 per cent had skeletal metastases, liver metastases, or brain metastases.

DIFFERENTIAL DIAGNOSIS. Follicular carcinoma clinically may be confused with any thyroid disease causing enlargement or nodularity. The decision to excise nodular enlargements because cancer is suspected should be made on the judgment and the experience of the clinician and surgeon. In

FOLLICULAR CARCINOMA WITH METASTASES

(Figures 91 and 92 are from the same case)

Figure 92. This carcinoma with metastases to the lung is from an autopsy specimen from the same case as illustrated in figure 91. The patient died in 1951, nearly 17 years after removal of the primary thyroid cancer. Metastases in the lower lobes of the lung were known to have been present for 12 years although the patient did not die from metastatic tumor. No metastases were found at autopsy except those in the lower lobes. × 35. A.F.I.P. Acc. No. 219764–47.

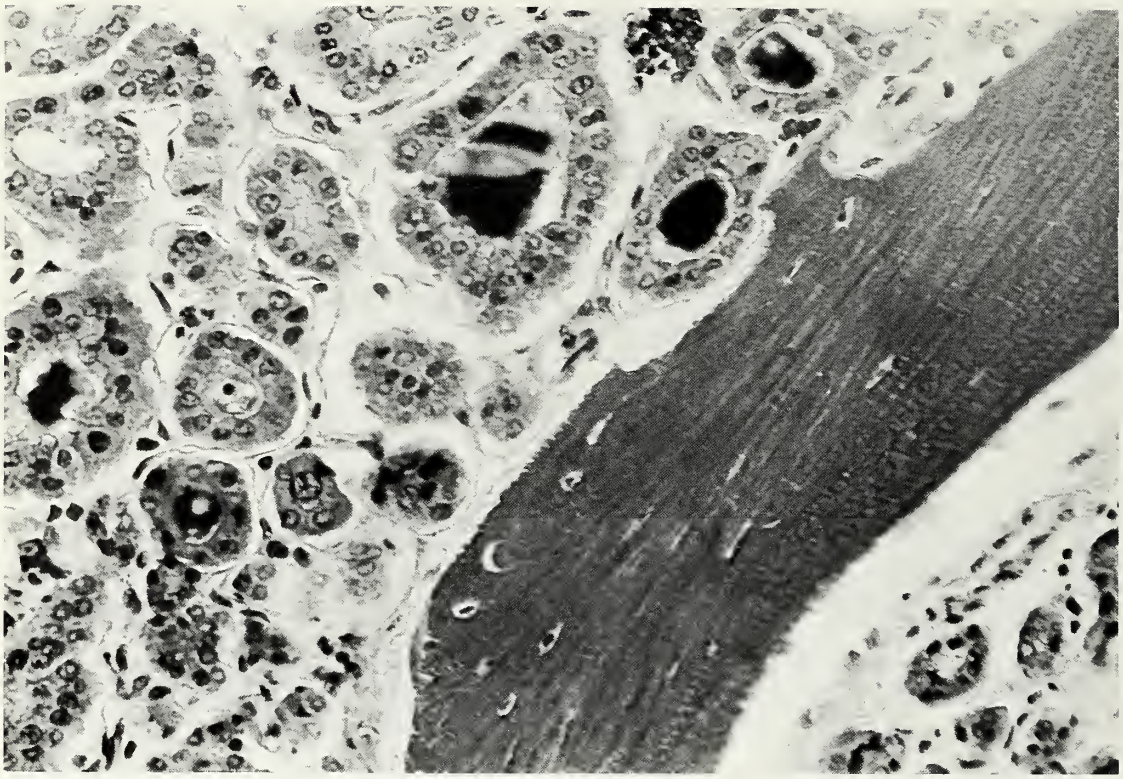

METASTATIC FOLLICULAR CARCINOMA IN BONE

Figure 93. The specimen shows a well differentiated metastasis of follicular carcinoma in bone. × 400. (This is figure 16 from Warren, S., and Feldman, J. D. The nature of lateral "aberrant" thyroid tumors. Surg. Gynec. Obstet. 88: 31–44, 1949.) A.F.I.P. Acc. No. 219764–48.

general, solitary growing nodules in young people or in men are considered more likely to be cancer than similar nodules in older people or in women.

Grossly, the diagnosis of cancer may be obvious from its invasion and extension. Other follicular carcinomas cannot be distinguished from adenoma since invasion is only evident microscopically.

The chief problem in microscopic examination is differentiation of follicular carcinoma from adenoma or adenomatous goiter. The emphasis usually is on demonstrating invasion in what otherwise would be a benign nodule. The best areas to examine microscopically for invasion are the periphery or capsule of the mass where invasion of capsule, adjacent gland, or vessels is most easily recognized. The central portion of a nodule is often distorted by fibrosis or other retrogressive changes and is difficult and confusing to interpret. Invasion of capsule or vessels may not be found on every section; Hazard and Kenyon recommend studying eight or more blocks of the periphery of atypical adenomas before concluding that invasion is absent.

Years ago Graham recognized the value of vascular invasion in the diagnosis of thyroid cancer. Elastic tissue stains, such as those of Verhoeff or Weigert, help to identify vessel walls by accentuating the internal

elastic lamellae and aid considerably in discovering blood vessel invasion (pl. I–D). Tumor cells artifactually introduced into vessels during pathologic examination or processing should not be interpreted as true vascular invasion. To be valid, the tumor cells should be either attached to the intima or associated with a thrombus. Also, as Park and Lees stress, blood vessel invasion is of diagnostic value only if the "epithelium" is unequivocally epithelium and the "blood vessel" is unequivocally a blood vessel.

Occasionally in glands with hyperplasia, thyroiditis, or adenomatous goiter, there are clusters of follicular cells with large, bizarre, pleomorphic, often folded nuclei (figs. 94, 95). The cells may or may not have increased cytoplasm. They resemble oxyphilic cells, but the cytoplasm is neither granular nor acidophilic. Such cells, presumably degenerative, often cause one to suspect cancer. They do not show mitoses. It is unlikely that such cells are caused by thiouracil; in our opinion, thiouracil does not produce diagnostic cellular changes. Bizarre cellular and nuclear changes may, however, result from chronic radiation damage (fig. 62).

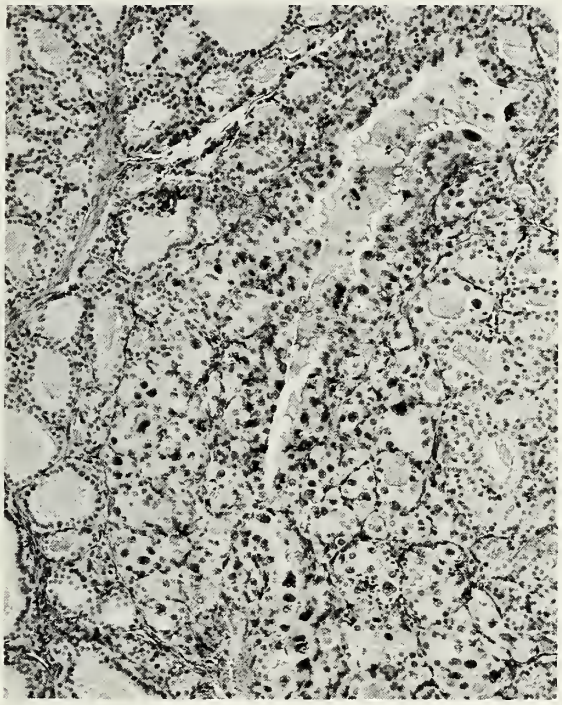

CELLULAR ATYPIA IN GRAVES' DISEASE

(Figures 94 and 95 are from the same case)

Figure 94. A focus of atypical cells was found in the thyroid gland from a patient with Graves' disease. × 100. A.F.I.P. Atlas No. 67-3-46.

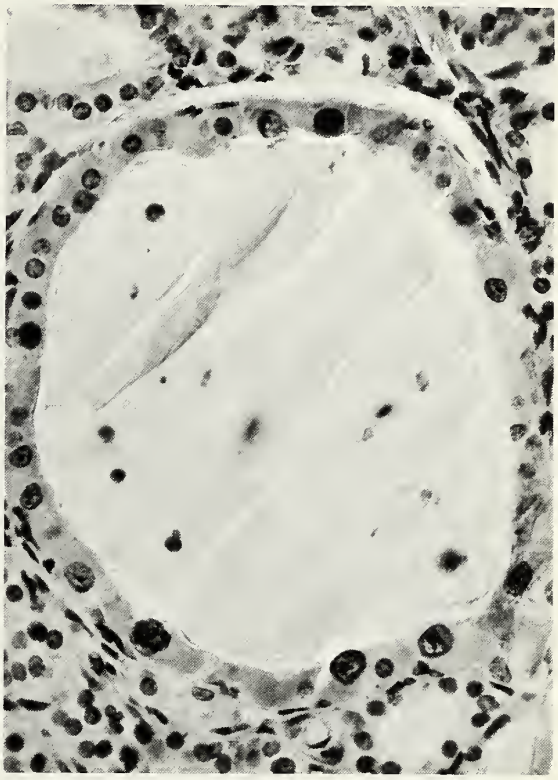

CELLULAR ATYPIA IN GRAVES' DISEASE

(Figures 94 and 95 are from the same case)

Figure 95. A higher magnification is shown of atypical cells from the same gland as shown in figure 94. The large pale cells contain hyperchromatic large nuclei. Similar atypical cells with bizarre nuclei also may be found in adenomatous goiter and may be confused with carcinoma. Presumably, the atypicality of the cells is caused by retrogressive changes. These cells do not show mitoses. × 350. A.F.I.P. Atlas No. 67-3-47.

The possibility that normal or hyperplastic thyroid tissue extends into adjacent muscle and fat (fig. 16) has been discussed on page 26.

Finally, it should be mentioned that occasionally a follicular carcinoma may be so well differentiated that its follicles appear similar to those of the normal thyroid (fig. 96).

PROGNOSIS. The prognosis of follicular carcinoma depends largely on the extent of invasion at the time of the surgical excision. Follicular carcinomas that show minimal invasion and appear grossly similar to adenomas have a very high cure rate merely with local excision; nevertheless, they still may have disseminated, although relatively few will have metastasized at the time of surgery. The latter possibility demands that the prognosis for individual cases must be guarded, even though the prognosis for these tumors with minimal invasion as a group is very good. Warren followed 34 cases of follicular carcinoma in which blood vessel invasion was the sole sign of malignant change and found only 2 patients who developed metastases and died.

With more extensive invasion, the prognosis becomes progressively poorer. Five-year survival reports for follicular carcinomas

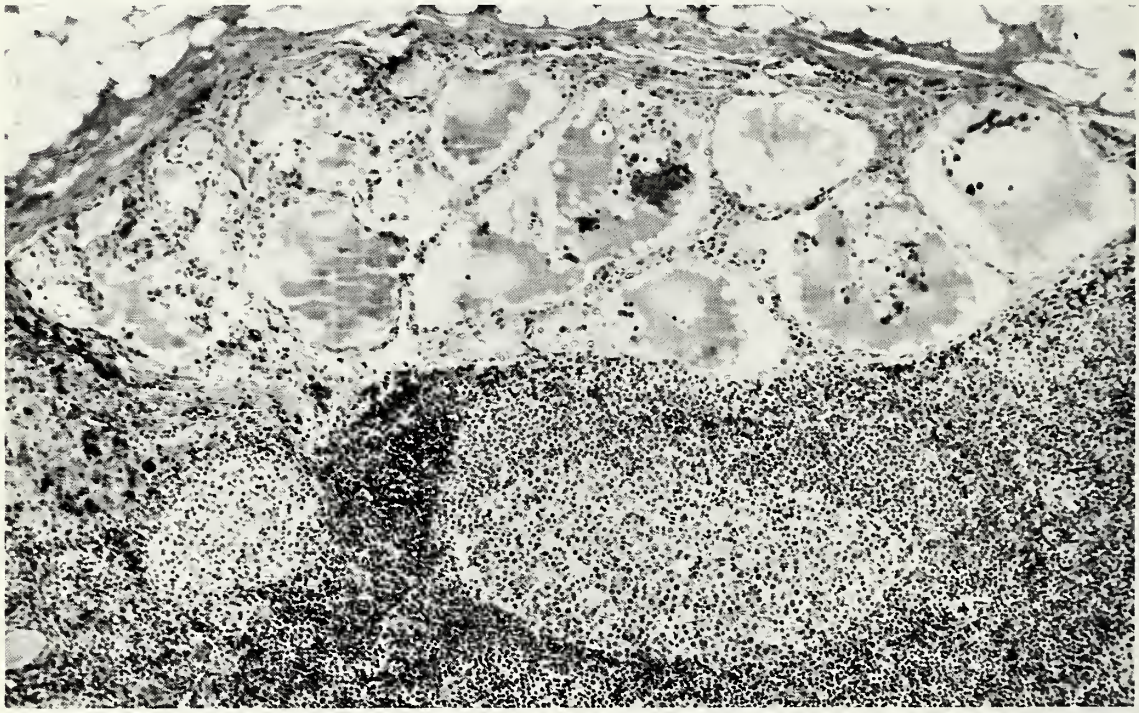

METASTATIC WELL DIFFERENTIATED FOLLICULAR CARCINOMA

Figure 96. Metastatic focus of a well differentiated follicular carcinoma is shown in the periphery of a cervical lymph node. Occasionally follicular carcinomas and their metastases may form follicles similar to those of the normal gland. The diagnosis of cancer from examination of the lymph node alone would be difficult (see figure 18). This 24-year-old man had an unusually well differentiated follicular carcinoma of the thyroid which nevertheless had metastasized to 10 cervical lymph nodes. × 125. (From Meissner, W. A. Abstract from Seminar on Tumors of the Neck, American Society of Clinical Pathologists, 1955.) A.F.I.P. Atlas No. 67-3-48.

with more extensive invasion are less than 50 per cent.

The accumulated statistics of the American Cancer Society, representing reports of prognosis of many different authors, show the 5-year survival of all follicular carcinomas to be 64.7 per cent. Death may be due to local disease or to complications from distant metastases.

TREATMENT. Surgical excision of follicular carcinoma with an adequate margin of uninvolved tissue usually requires a lobectomy. Many, including Russell and others, have emphasized the frequency of intraglandular metastases in the opposite lobe and, for this reason, recommend total thyroidectomy. So-called radical neck dissection on the side of the tumor is performed by many surgeons, particularly if lymph node metastases are suspected; the value of such lymph node dissection is still being debated.

Of all thyroid cancers, follicular carcinoma is the one most likely to take up sufficient radioiodine to be of therapeutic value. Radioiodine may be particularly useful in the treatment of metastases. Since normal thyroid tissue almost always takes up iodine more avidly than tumor tissue, it is necessary to ablate the normal thyroid, surgically or by radioiodine, before the tumor can be effectively treated. Once the normal gland is ablated, tumor may be stimulated by TSH to take up additional radioiodine. Roentgen ray therapy to recurrent carcinoma in the neck or to metastases at more distant foci often proves surprisingly effective according to Smedal and associates. As with all thyroid cancers, suppressive doses of thyroid hormone are usually administered on a permanent basis once the diagnosis is made.

## References


Colcock, B. P., and Adams, H. D. Thyroid surgery for benign and malignant disease. Surg. Clin. N. Amer. 45:533–552, 1965.

Graham, A. Malignant epithelial tumors of the thyroid, with special reference to invasion of blood vessels. Surg. Gynec. Obstet. 39:781–790, 1924.

Hazard, J. B., and Kenyon, R. Atypical adenoma of the thyroid. Arch. Path. 58:554–563, 1954.

———. Encapsulated angioinvasive carcinoma (angioinvasive adenoma) of thyroid gland. Amer. J. Clin. Path. 24:755–766, 1954.

Horn, R. C., Jr. Problems in the pathologic diagnosis of carcinoma of the thyroid. Arch. Path. 69:481–492, 1960.

Meissner, W. A., and McManus, R. G. A comparison of the histologic pattern of benign and malignant thyroid tumors. J. Clin. Endocr. 12:1474–1479, 1952.

Park, W. W., and Lees, J. C. The histology of cancer of the thyroid. Cancer 8:320–335, 1955.

Russell, W. O., Ibanez, M. L., Clark, R. L., and White, E. C. Thyroid carcinoma. Classification, intraglandular dissemination, and clinicopathological study based upon whole organ sections of 80 glands. Cancer 16:1425–1460, 1963.

Silliphant, W. M., Klinck, G. H., and Levitin, M. S. Thyroid carcinoma and death. A clinicopathological study of 193 autopsies. Cancer 17:513–525, 1964.

Smedal, M. I., Salzman, F. A., and Meissner, W. A. The value of 3 mv. roentgen-ray therapy in differentiated thyroid carcinoma. Amer. J. Roentgen. 99:352–364, 1967.

Warren, S. The significance of invasion of blood vessels in adenomas of the thyroid gland. Arch. Path. 11:255–257, 1931.


An occasional carcinoma of the thyroid is composed predominantly, or even entirely, of cells with a very clear cytoplasm. The resemblance of such cells to those of a renal carcinoma may be striking, and the possibility that this **clear cell carcinoma** (figs. 97, 98) might be a metastasis from a renal cell carcinoma must be considered. The cytoplasm of these clear cells of the thyroid does not stain with the PAS reaction or with oil-red O, as cells of renal cell carcinomas usually do.

Too few such cases have been reported to know their exact biologic behavior. It seems probable, however, that they are merely variants of follicular carcinoma, particularly since colloid is formed in some of the tumors. Whether the clear cells represent a metaplasia or whether they arise from a pluripotential cell with capacity to form either thyroid or parathyroid elements is a matter of speculation; the cells resemble the clear cells of the parathyroid gland, but hyperparathyroidism has not been demonstrated in any of the reported cases of clear cell carcinoma of the thyroid.

Kniseley and Andrews suggest that the clear cell change might be associated with increased ability of the tumor to concentrate iodine. They made this suggestion after observing two instances in which follicular and papillary carcinomas changed to a clear cell type after thyroidectomy and before replacement thyroid therapy. In one instance, the clear cell change was then reversed after treating the patient with thyroid hormone.

CLEAR CELL CARCINOMA

(Figures 97 and 98 are from the same case)

Figure 97. This is a follicular carcinoma of the thyroid composed of clear cells. The patient is alive and well 10 years after the removal of the thyroid tumor. × 125. A.F.I.P. Atlas No. 67-3-49.

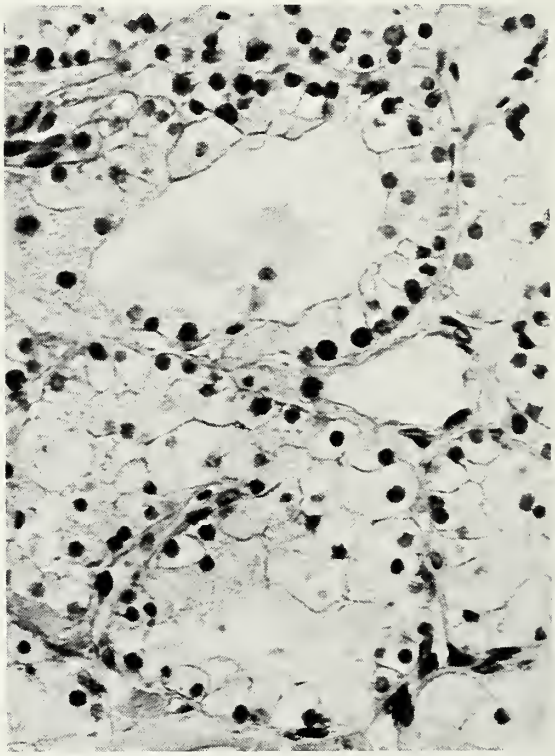

CLEAR CELL CARCINOMA

(Figures 97 and 98 are from the same case)

Figure 98. Higher magnification is shown of the same tumor seen in figure 97. The clear cells did not stain with either PAS or oil-red O. × 400. A.F.I.P. Atlas No. 67-3-50.

## References

Chesky, V. E., Hellwig, C. A., and Barbosa, E. Clear cell tumors of the thyroid. Surgery 42:282–289, 1957.

Kniseley, R. M., and Andrews, G. A. Transformation of thyroidal carcinoma to clear-cell type. Amer. J. Clin. Path. 26:1427–1438, 1956.

Some follicular carcinomas are composed partly, or even completely, of cells of the oxyphilic type. Such tumors have a striking and characteristic microscopic appearance and often have been grouped separately from follicular carcinomas. Some observers have suggested that they are more malignant; others, that they are less malignant than other follicular cancers. The tendency to group **oxyphil carcinomas** *(oncocytic carcinoma*;* eosinophilic cell carcinoma; Hürthle cell carcinoma) (figs. 99, 100; pl. II–D) separately from other thyroid tumors has been stimulated by the confusion regarding the origin of the oxyphilic cell. It is unnecessary to designate these tumors as a separate entity since their biologic behavior is not dependent upon the presence of oxyphilic change of the follicular cells, but upon the pattern and architecture of the tumor as a whole. Oxyphil follicular tumors behave as other follicular carcinomas (Horn). Oxyphilic cells are seen not only in follicular carcinomas, but also may be present in papillary or undifferentiated tumors.

## References

Frazell, E. L., and Duffy, B. J., Jr. Hürthle-cell cancer of the thyroid; a review of forty cases. Cancer 4:952–956, 1951.

Hamperl, H. Onkocytes and the so-called Hürthle cell tumor. Arch. Path. 49:563–567, 1950.

Horn, R. C., Jr. Hürthle-cell tumors of the thyroid. Cancer 7:234–244, 1954.

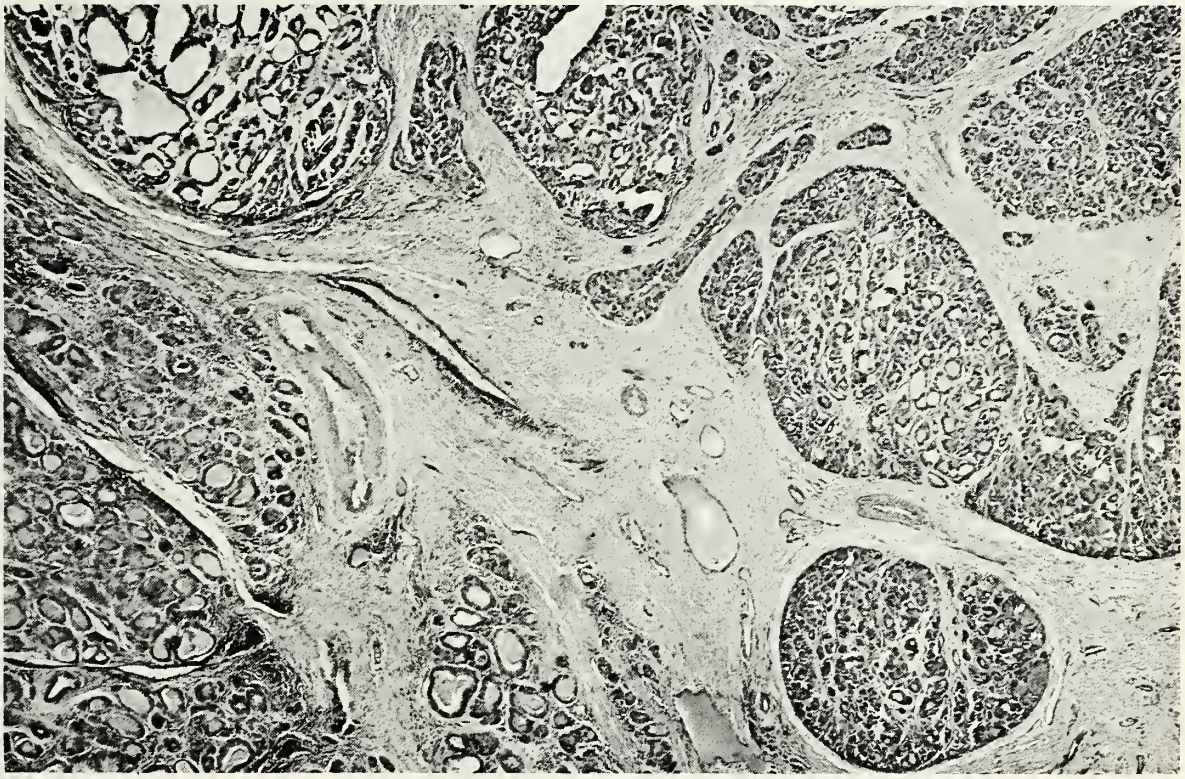

OXYPHILIC FOLLICULAR CARCINOMA

Figure 99. Most of the cells are oxyphilic in this follicular carcinoma. Oxyphilic cells may also be found in papillary or undifferentiated carcinomas. × 48. A.F.I.P. Acc. No. 219764–71.

*Preferred International Nomenclature

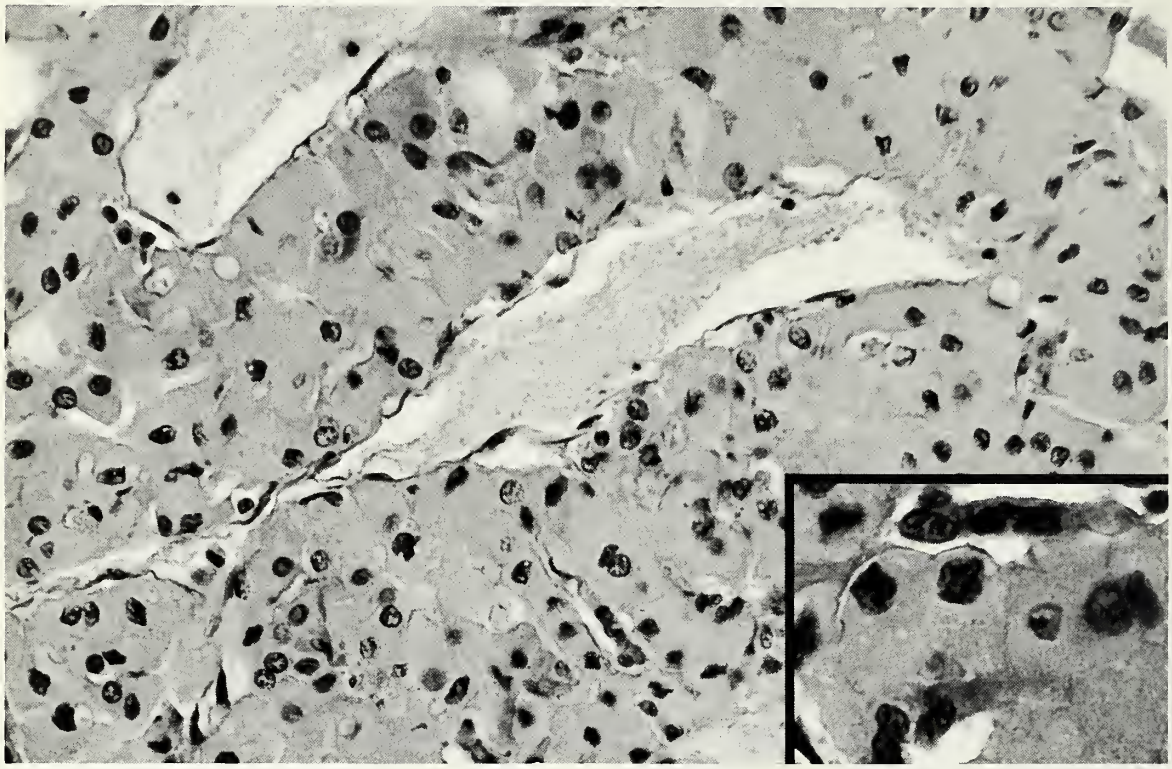

OXYPHILIC FOLLICULAR CARCINOMA

Figure 100. Pulmonary metastasis of a follicular carcinoma with oxyphilic cells is shown with their typical swollen, pale cytoplasm. × 395. Insert × 1000 shows cell detail. (From the Armed Forces Institute of Pathology.) A.F.I.P. Acc. No. 208904.

**MEDULLARY CARCINOMA**† (Figures 101–107; plate IV–C, D, E)

SYNONYMS AND RELATED TERMS: Solid carcinoma; "atypical" carcinoma; compact small cell carcinoma.

DEFINITION. A carcinoma of moderate degree of malignancy, the cells of which grow in solid clusters surrounded by dense stroma. The stroma characteristically contains amyloid.

GROSS. The typical tumor presents as a single, hard, gray-white mass, usually well demarcated and sometimes even encapsulated (pl. IV–C). It is solid and does not show the central scar which is so frequently found in the papillary carcinomas. The size averages 2 to 3 cm. in diameter, but may vary from a few millimeters to as much as 10 cm. Massive blood vessel invasion by the tumor is often grossly evident.

MICROSCOPIC. Tumor cells are clustered into solid, irregular groups separated by a hyaline, amyloid-containing stroma (figs. 101–103). The solid islands of tumor cells are of variable size and sometimes consist only of cords or very small clusters. Cells of the tumor are round or polyhedral and have an eosinophilic granular cytoplasm (figs. 105–107). The nuclei are somewhat

† There is no analogous term for this tumor of the thyroid in the international tumor nomenclature.

# MEDULLARY CARCINOMA

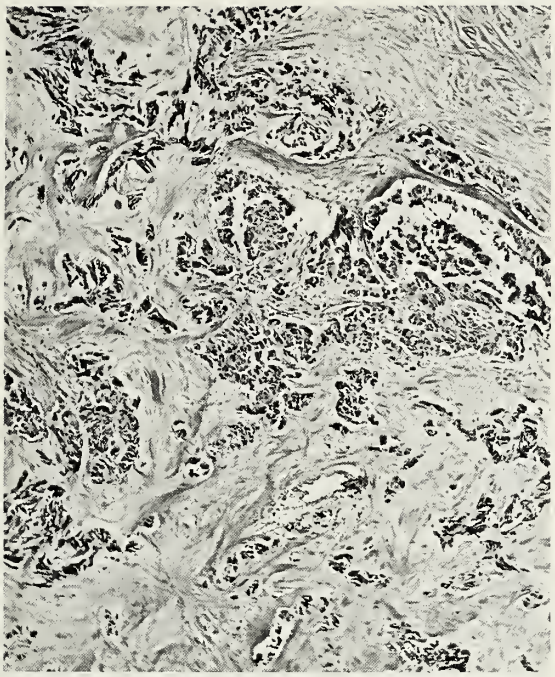

Figure 101. This medullary carcinoma shows solid masses and cords of cells lying in a dense hyaline stroma. Amyloid stains of the stroma were positive. × 50. A.F.I.P. Atlas No. 67-3-53.

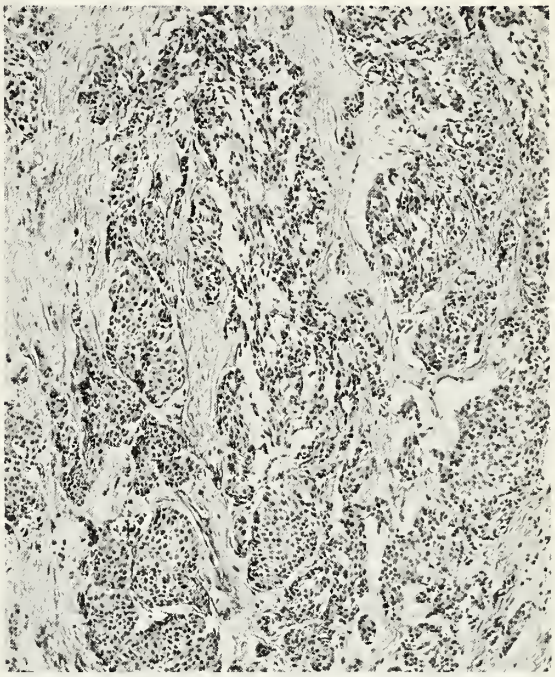

Figure 102. The tumor cells of this medullary carcinoma are in compact clusters. The stroma stained positively for amyloid. × 50. A.F.I.P. Atlas No. 67-3-54.

(Figures 103 and 107 and Plate IV–D, E are from the same case)

Figure 103. In this medullary carcinoma, the tumor cells seem to surround various sized masses of hyaline material which stained positively for amyloid. × 50. A.F.I.P. Atlas No. 67-3-55.

hyperchromatic; binucleate cells are relatively frequent, but mitoses, while often present, are sparse. Many variants of cells and cellular arrangement are possible: for example, the cells may be spindle shaped; they may resemble those of a carcinoid tumor; they may grow in a follicular pattern, but without formation of colloid (fig. 104); they may grow in a perivascular fashion; they may be trabecular or even palisaded in arrangement. Several different variants of cells and patterns may be found within the same tumor. Some of the tumors suggest a papillary pattern, but there is no transition to either papillary or follicular carcinoma.

The hyaline stroma stains focally for amyloid (fig. 107), but the amount of amyloid

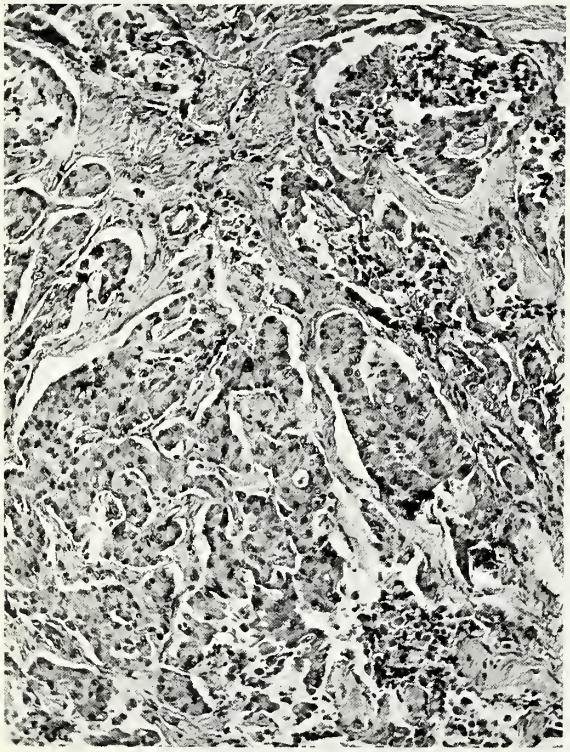

MEDULLARY CARCINOMA

Figure 104. This medullary carcinoma shows an occasional poorly formed gland space but no follicles. × 100. A.F.I.P. Atlas No. 67-3-56.

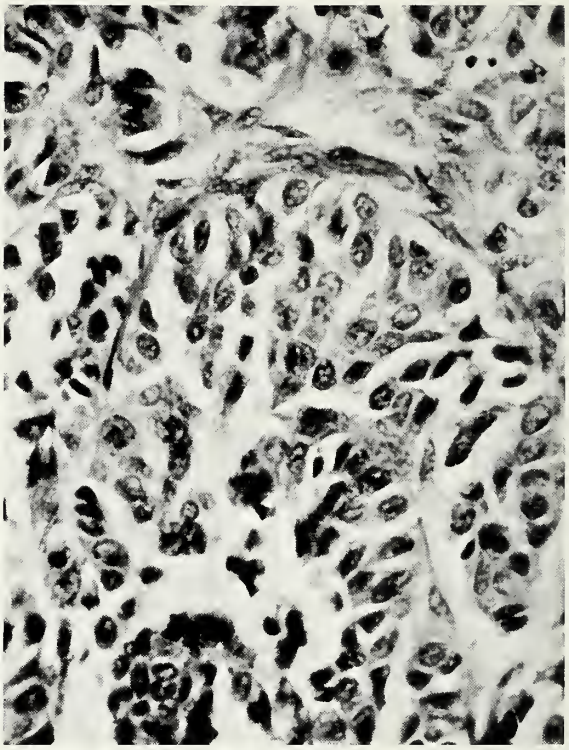

MEDULLARY CARCINOMA

Figure 105. A higher magnification of a medullary carcinoma shows a fairly solid mass of epithelial cells. × 400. A.F.I.P. Atlas No. 67-3-57.

varies from one tumor to another and in different parts of the same tumor. Usually all the common amyloid stains are positive: thioflavin T fluorescence, Congo red, and crystal violet (pl. IV–D, E). Occasionally there is a foreign body giant cell reacting to the amyloid. Detailed studies by Albores-Saavedra and associates of the amyloid by histochemical means, by tissue culture, and by electron microscopy suggest that the amyloid is formed by the epithelial cells of the tumor and, indeed, amyloid may be seen occasionally in the tumor cells (Vassar and Culling). The ultrastructure of the amyloid is similar to that observed in primary, secondary, and experimental amyloidosis. The amyloid is composed of glycoproteins and

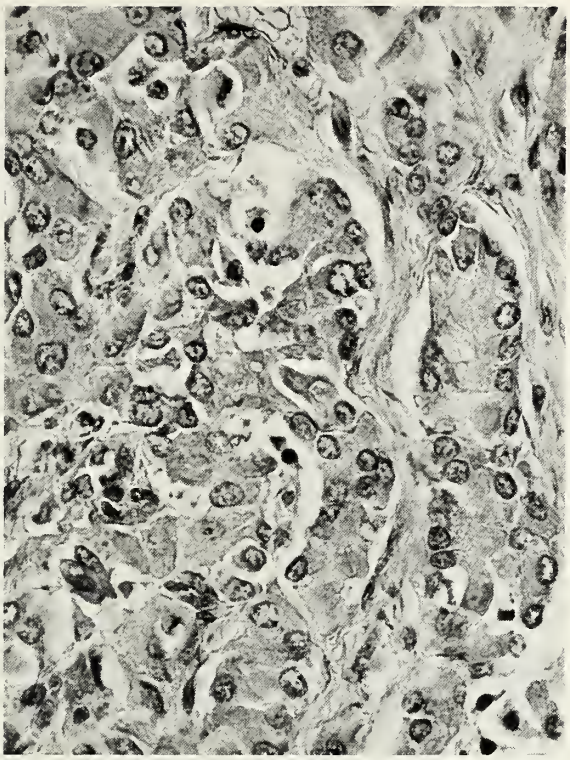

MEDULLARY CARCINOMA

Figure 106. Another pattern of epithelial cells is seen in this medullary carcinoma. Mitoses are infrequent. × 400. A.F.I.P. Atlas No. 67-3-58.

acid mucopolysaccharides. Amyloid may be found in metastases from medullary carcinoma and occasionally in renal glomeruli in patients with medullary carcinoma (Williams et al.). There is, however, no generalized amyloidosis.

Deposits of calcium in the stroma are frequent and may somewhat resemble the appearance of psammoma bodies; the characteristic laminated psammoma body as seen typically in papillary carcinoma may also be present. In addition, the stroma usually contains a few plasma cells and lymphocytes. Vascular invasion by the epithelial tumor cells is common. The thyroid tissue, uninvolved by tumor, shows no consistent noteworthy changes.

NATURAL HISTORY. Medullary carcinoma makes up between 5 and 10 per cent of all thyroid carcinomas. In the large series of Woolner and associates, the incidence was 6.5 per cent of all thyroid cancers. Although most of the cases occur in patients over 40 years of age, the tumor has been seen in children and in elderly people. It is somewhat more common in men than in women. The tumor may arise in either lobe and is occasionally multifocal, presumably due to intraglandular metastasis, but the possibility of multiple foci of origin cannot be excluded. Since the tumors are slow growing,

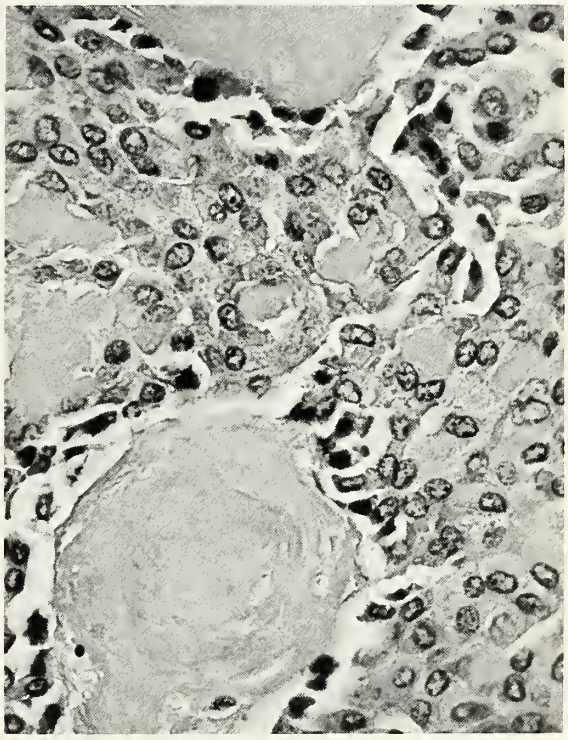

MEDULLARY CARCINOMA

(Figures 103 and 107 and Plate IV–D, E are from the same case)

Figure 107. This medullary carcinoma depicts still another growth pattern with the tumor cells intimately related and seeming to form hyaline masses. The stroma stained positively for amyloid. × 400. A.F.I.P. Atlas No. 67-3-59.

the clinical course is a chronic one, but metastasis to lymph nodes (pl. IV–C) and by blood stream dissemination is very frequent.

In 1951, Horn described a carcinoma characterized by solid groups of regular cells; in 1955, Hazard and associates named the tumor medullary carcinoma and clearly defined it as a clinicopathologic entity in 1959. Since then there has been considerable speculation about its cell of origin and great interest in its associations. Obviously the tumor is more than just a variant of thyroid carcinoma to be distinguished from undifferentiated carcinoma because of its better prognosis. Evidence is accumulating rapidly that the tumor is familial, often associated with pheochromocytoma and with cutaneous or mucous membrane neuromas, and that it may secrete a substance giving rise to a carcinoid-like syndrome with excessive flushing and diarrhea. The syndrome seems closely related to von Recklinghausen's disease.

Of the thyroid carcinomas that have been associated with pheochromocytoma, at least two-thirds have been of the medullary type. Furthermore, in such associations, the pheochromocytomas are usually bilateral (70 per cent). Ljungberg and associates recently investigated 150 members of a family and found 7 cases of medullary carcinoma; 8 persons had symptoms of, or proved pheochromocytoma and multiple cutaneous tumors of the neurofibromatosis type. Ljungberg believes that the syndrome is a distinct genetic entity with an autosomal dominant mode of inheritance, and since some of the medullary carcinomas do stain like chromaffin tissue, his suggested term "familial chromaffinomatosis" is an intriguing one.

Another area of interest that is poorly understood is the association of parathyroid adenoma with medullary carcinoma. While several studies have shown that parathyroid adenoma is associated with any type of thyroid carcinoma more commonly than by chance, the association is even greater with medullary carcinoma. The explanation for such an association is difficult, on either a genetic or a cellular basis. With the recent discovery of the parathyroid hormone-like substance of the thyroid, thyrocalcitonin, it has been suggested that perhaps the same thyroid cell (parafollicular cell in animals) that produces thyrocalcitonin also gives rise to the medullary tumor of the thyroid. High levels of thyrocalcitonin-like activity were found in a medullary carcinoma by Meyer and Abdel-Bari. Williams (2d ref., 1966) states that there is a great resemblance between tumors of the parafollicular cells of rats and dogs and medullary carcinomas of the thyroid in man. Electron microscopic studies of medullary carcinoma cells by Braunstein and associates and by Meyer also demonstrate a striking similarity to the parafollicular cells. The presence of parafollicular cells in the normal thyroid of man has not been demonstrated conclusively as yet.

DIFFERENTIAL DIAGNOSIS. Medullary carcinoma may be confused with benign tumors, thyroiditis, adenomatous goiter, and other types of thyroid carcinoma. Because of its variable growth pattern, it may strongly suggest metastatic carcinoma. The presence of amyloid in the stroma is the most distinctive feature of medullary carcinoma, particularly since the cellular and architectural pattern may be so variable. Studies of the stroma of other types of thyroid carcinoma rarely have demonstrated amyloid in the stroma. While at present most observers diagnose the tumor only if the stroma contains amyloid, it is likely that, as the tumor becomes better defined, variants without amyloid stroma may become recognized.

PROGNOSIS. Although the tumor is slowly growing and has a chronic course, it nevertheless has great ability to metastasize by both lymphatics and blood vessels. As a result, lymph node metastases are common and disseminated metastases relatively frequent. The over-all prognosis lies somewhere between that of the papillary-follicular carcinoma group and that of the undifferentiated carcinomas. At the time of the definitive diagnosis, one-half or more of the cases already show metastases in cervical lymph nodes. Of 33 cases reported by Freeman and Lindsay, 13 patients died of medullary carcinoma, 10 with distant metastases. In 20 postmortem cases described by Williams and associates, the distribution of metastases was as follows: local and mediastinal lymph nodes, 13; lungs, 9; liver, 5; adrenals, 4; bones, 4; pleura, 2; heart, 1; ovary, 1; pancreas, 1; and no disseminated tumor, 4. Death may be caused by local disease such as extension into the trachea as well as by disseminated metastases.

TREATMENT. Inasmuch as the tumor has been shown to be multifocal, the proper initial treatment is thyroidectomy (Rouse and Whelan). Resection of regional lymph nodes, if feasible, should be performed if there is any suspicion that they are involved with the tumor. The tumors do not take up radioiodine; therefore, this method of therapy is of no value. High voltage irradiation is still being evaluated.

## References


Albores-Saavedra, J., Rose, G. G., Ibanez, M. L., Russell, W. O., Grey, C. E., and Dmochowski, L. The amyloid in solid carcinoma of the thyroid gland. Staining characteristics, tissue culture, and electron microscopic observations. Lab. Invest. 13:77–93, 1964.

Braunstein, H., Stephens, C. L., and Gibson, R. L. Secretory granules in medullary carcinoma of the thyroid. Electron microscopic demonstration. Arch. Path. 85:306–313, 1968.

Freeman, D., and Lindsay, S. Medullary carcinoma of the thyroid gland. Arch. Path. 80:575–582, 1965.

Friedell, G. H., Carey, R. J., and Rosen, H. Familial thyroid cancer. Cancer 15:241–245, 1962.

Hazard, J. B., Hawk, W. A., and Crile, G., Jr. Medullary (solid) carcinoma of the thyroid; a clinicopathologic entity. J. Clin. Endocr. 19:152–161, 1959.

———, Crile, G., Jr., Dinsmore, R. S., Hawk, W. A., and Kenyon, R., Cleveland. Scientific exhibits: neoplasms of thyroid; classification, morphology, and treatment. Arch. Path. 59:502–513, 1955.

Horn, R. C., Jr. Carcinoma of the thyroid; description of a distinctive morphological variant and report of seven cases. Cancer 4:697–707, 1951.

Ljungberg, O., Cederquist, E., and Studnitz, W. von. Medullary thyroid carcinoma and phaeochromocytoma: a familial chromaffinomatosis. Brit. Med. J. 1:279–281, 1967.

Meyer, J. S. Fine structure of two amyloid-forming medullary carcinomas of thyroid. Cancer 21:406–425, 1968.

———, and Abdel-Bari, W. Granules and thyrocalcitonin-like activity in medullary carcinoma of the thyroid gland. New Eng. J. Med. 278:523–529, 1968.

Rouse, R. M., and Whelan, T. J. Multicentric medullary carcinoma of the thyroid gland: case report. J. Clin. Endocr. 26:231–232, 1966.

Vassar, P. S., and Culling, C. F. The significance of amyloid in carcinoma of the thyroid gland. Amer. J. Clin. Path. 36:244–247, 1961.

Williams, E. D. A review of 17 cases of carcinoma of the thyroid and phaeochromocytoma. J. Clin. Path. 18:288–292, 1965.

———. Diarrhoea and thyroid carcinoma. Proc. Roy. Soc. Med. 59:602–603, 1966.

———. Histogenesis of medullary carcinoma of the thyroid. J. Clin. Path. 19:114–118, 1966.

———, and Pollock, D. J. Multiple mucosal neuromata with endocrine tumours: a syndrome allied to von Recklinghausen's disease. J. Path. Bact. 91:71–80, 1966.

———, Brown, C. L., and Doniach, I. Pathological and clinical findings in a series of 67 cases of medullary carcinoma of the thyroid. J. Clin. Path. 19:103–113, 1966.

Woolner, L. B., Beahrs, O. H., Black, B. M., McConahey, W. M., and Keating, F. R., Jr. Classification and prognosis of thyroid carcinoma. A study of 885 cases observed in a thirty year period. Amer. J. Surg. 102:354–387, 1961.

## UNDIFFERENTIATED CARCINOMA
(Figures 108–121; plates I–C, III–B)

SYNONYMS AND RELATED TERMS: Anaplastic carcinoma; carcinoma simplex.

The undifferentiated carcinomas of the thyroid are those that form neither papillary nor follicular structures and do not have amyloid stroma. The term undifferentiated is not necessarily synonymous with a high degree of malignancy in other locations, but in thyroid cancers it usually is. About 15 per cent of thyroid carcinomas are undifferentiated. Many classifications of thyroid tumors place all undifferentiated carcinomas in a single group, but it is possible and desirable to separate such tumors into several subgroups because of differences in differential diagnosis and in prognosis. One group of undifferentiated carcinomas consists principally of small cells; a second group consists of cells which are large, bizarre, and often of giant size.

Just as differentiated follicular and papillary tumors are often mixed, so, too, the undifferentiated carcinomas may show *mixed patterns* (figs. 117–120; pl. III–B). The mixtures may include not only the various types of undifferentiated cancer but also follicular and papillary foci. It is possible that some mixed carcinomas are mixtures from the beginning; it is also possible, as has been suggested by many observers, that foci within chronic low grade cancer may become more malignant.

### SMALL CELL CARCINOMA* (Figures 109–113)

A highly malignant carcinoma composed of small cells, growing either diffusely or compactly, with little or no differentiation is termed small cell carcinoma.

GROSS. These tumors are typical cancers, being firm and ill-defined (fig. 108). At the time of diagnosis, there frequently is ex-

*Preferred International Nomenclature

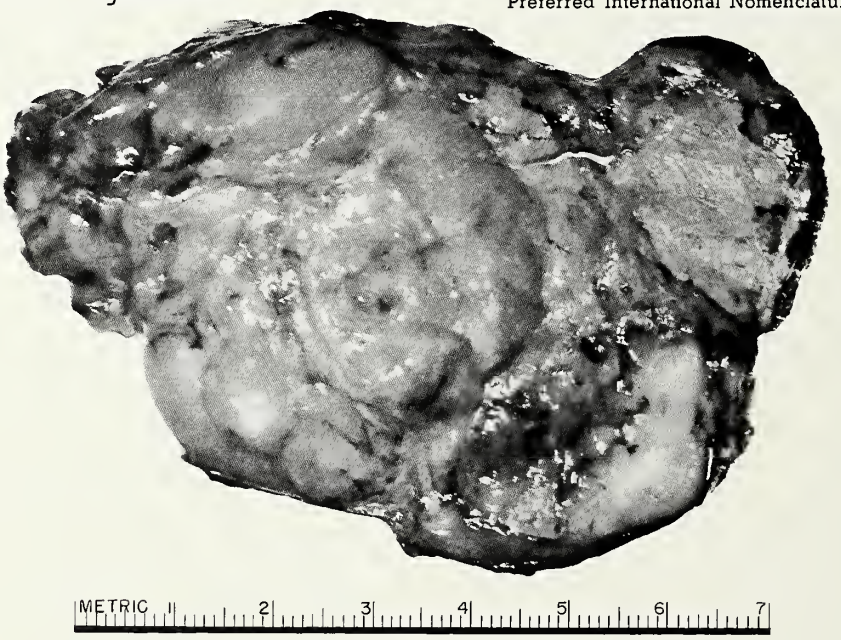


UNDIFFERENTIATED CARCINOMA

Figure 108. The extensive involvement of the gland by this undifferentiated carcinoma is typical. The type of undifferentiated carcinoma cannot be determined without histologic examination. A.F.I.P. Acc. No. 219764–57.

tension not only into adjacent thyroid tissue but also into structures adjacent to the thyroid. Extension across the isthmus into the opposite lobe is common. Retrogressive changes such as hemorrhage and cyst formation, which are so common in less malignant and benign tumors, are not prominent in small cell carcinomas.

MICROSCOPIC. Small cell carcinomas are histologically of two types, although there may be transitions between them. In either type there may be occasional follicle formation.

The *compact type* most resembles other neoplasms of the thyroid. It has a uniform appearance and is composed of small, closely packed cells growing in strands or, more commonly, in clusters (fig. 109). Mitoses are frequent, but cellular and nuclear pleomorphism is not prominent. The tumors often lie in a stroma that is fibrous and hyaline, frequently resembling the stroma of the medullary carcinomas, but without amyloid (fig. 110). Possibly some of these tumors do represent medullary carcinomas, but the amyloid is either absent or not readily identified.

The *diffuse type* of small cell carcinoma resembles, and is often mistaken for, a tumor of the lymphoma group, particularly lymphosarcoma (Meissner and Phillips). In the majority of these tumors, the cells grow in a diffuse, lymphoma-like arrangement and only occasionally show the cohesiveness of epithelial neoplasms or a follicular grouping (figs. 111–113, 119). It is often necessary to search many fields, or even many sections, before such epithelial foci are identified. The recognizable epithelial components consist of abortive follicles and solid clumps of tumor cells. In some of the tumors the cells are uniformly round with scanty cytoplasm and resemble in size the lymphoblast rather

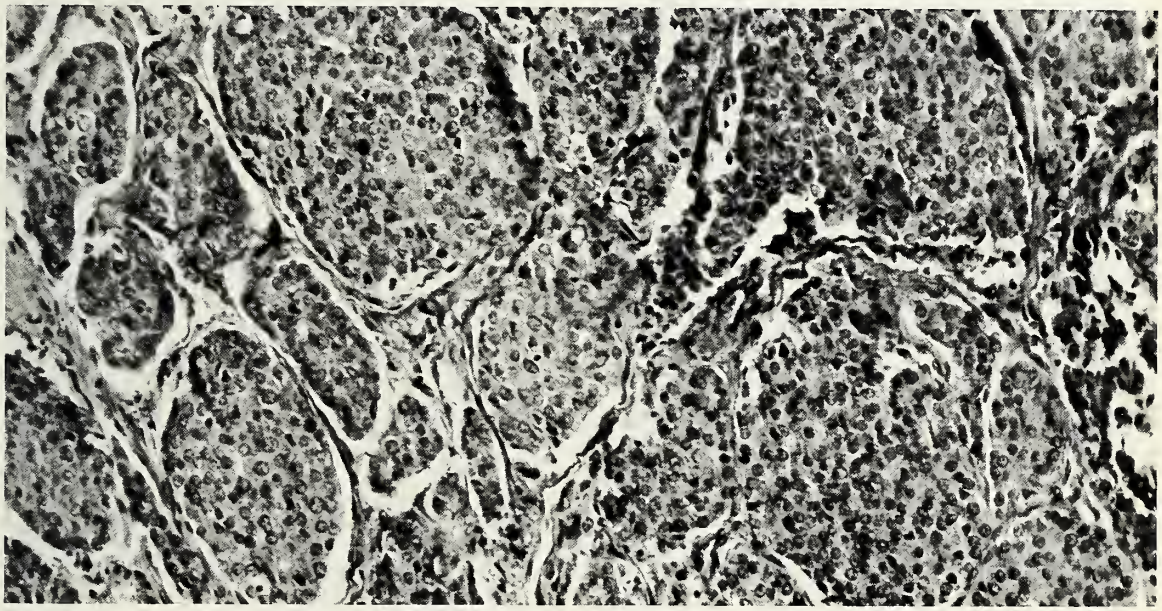

UNDIFFERENTIATED CARCINOMA, SMALL CELL TYPE

Figure 109. An undifferentiated carcinoma illustrates the small cell, compact type. × 250. (This is figure 5 from Meissner, W. A., and Lahey, F. H. Cancer of the thyroid in a thyroid clinic. J. Clin. Endocr. 8:749–765, 1948; also in Tr. Am. Goiter A. 137–149, 1948.) A.F.I.P. Acc. No. 219764–65.

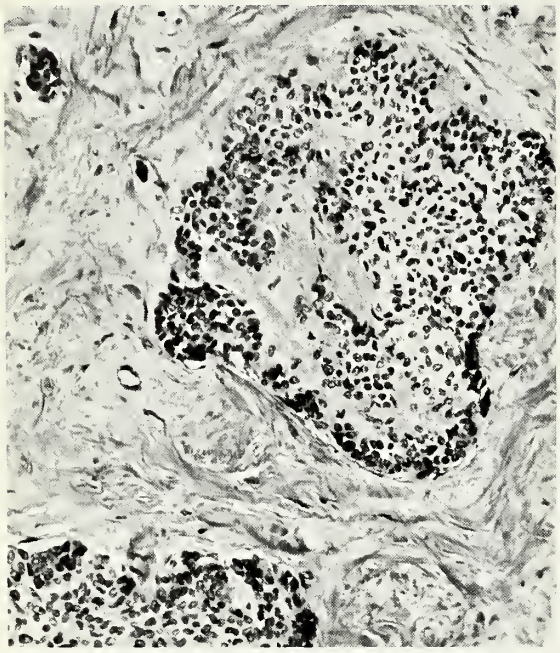

UNDIFFERENTIATED CARCINOMA, SMALL CELL TYPE

Figure 110. Note the resemblance of this small cell, compact type of undifferentiated carcinoma to medullary carcinoma. Although the amyloid stains of the stroma were negative, it is possible nevertheless that this tumor represents a variant of medullary carcinoma. × 200. A.F.I.P. Atlas No. 67-3-60.

than the mature lymphocyte. Another variant consists of cells which are ovoid with small, darkly stained and eccentrically placed nuclei; such cells superficially resemble plasma cells. In most small cell, diffuse carcinomas there are frequent and often atypical mitoses. The stroma is scanty and may be hyalinized. Blood vessel invasion is very common.

NATURAL HISTORY. Although there may be a history of a mass in the thyroid for some years before the diagnosis of small cell carcinoma is made, it can seldom be proved pathologically that the tumor has arisen from a pre-existing adenoma. The tumor is characterized by rapid growth, extensive invasion into the neck structures (fig. 111), and metastases by both lymphatics and blood stream. As with most thyroid carcinomas, it is somewhat more common in women than in men. It is a tumor predominantly of older age groups.

DIFFERENTIAL DIAGNOSIS. A diagnosis of highly malignant tumor usually can be made clinically or from the gross appearance. Exact classification can be made only by microscopic examination. The compact type may be confused with medullary carcinoma because of the microscopic pattern and the hyaline stroma. It may also be confused with metastatic carcinoma, particularly metastatic carcinoma from the breast. Small cell, diffuse carcinomas are often confused with lymphomas (see discussion of lymphoma on page 121).

PROGNOSIS. The prognosis of small cell carcinoma is very poor; the 5-year survival rate is between 20 and 25 per cent. The diffuse type has a poorer prognosis than the compact type. The tumor tends to invade the structures of the neck extensively, and death is often caused by disease in the neck rather than by metastases. Even if the tumor in the neck is controlled, distant metastases are so frequent that the prognosis is still poor.

TREATMENT. Surgical excision is the preferred treatment, if feasible, but unfortunately extension of the disease outside the thyroid or metastases at the time of diagnosis usually prevent curative surgery. If the tumor is diagnosed and treated while it is still contained within the thyroid, however, a cure may be effected by surgical excision. Radioiodine is of no value. High voltage irradiation is chiefly of value in palliation, but occasionally local disease is irradicated. Woolner and associates state that treatment of small tumors should include roentgen ray therapy in all cases because of possible confusion with lymphoma.

## SMALL CELL CARCINOMA, DIFFUSE TYPE

(Figures 112 and 113 are from the same case)

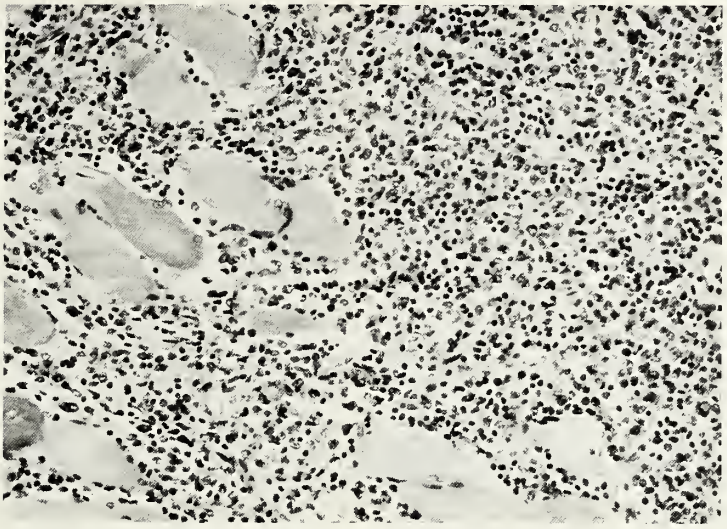

Figure 111. This small cell carcinoma of diffuse type is seen growing in striated muscle. Extensive invasion of neck structures is frequent in this type carcinoma. × 200. A.F.I.P. Atlas No. 67-3-61.



Figure 112. This photomicrograph of the diffuse type of small cell carcinoma also represents an extra-thyroidal extension. An epithelial structure is seen in the upper center. × 125. A.F.I.P. Atlas No. 67-3-62.

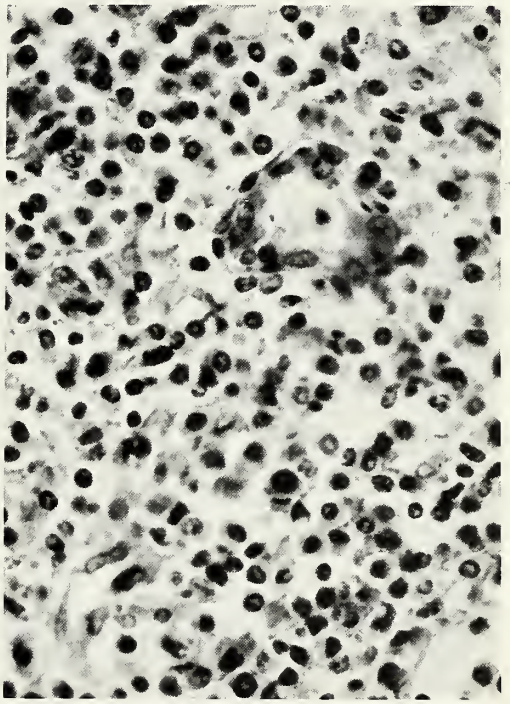

Figure 113. A higher magnification is shown of the same case as figure 112. The gland formation by the tumor cells is obvious. Note the resemblance of some of the tumor cells to plasma cells. × 500. A.F.I.P. Atlas No. 67-3-63.

### References

Meissner, W. A., and Phillips, M. J. Diffuse small-cell carcinoma of the thyroid. Arch. Path. 74:291–297, 1962.

Smedal, M. I., and Meissner, W. A. The results of x-ray treatment in undifferentiated carcinoma of the thyroid. Radiology 76:927–935, 1961.

Woolner, L. B., Beahrs, O. H., Black, B. M., McConahey, W. M., and Keating, F. R., Jr. Classification and prognosis of thyroid carcinoma. A study of 885 cases observed in a thirty year period. Amer. J. Surg. 102:354–387, 1961.

## GIANT CELL CARCINOMA*

SYNONYMS AND RELATED TERMS: Carcinosarcoma; spindle cell carcinoma; anaplastic carcinoma; polymorphous cell tumor.

A highly malignant, undifferentiated carcinoma composed of cells larger than the usual follicular cells, with many giant and/or spindle forms is termed giant cell carcinoma (figs. 57, 114–116).

GROSS. The gross appearance is that of a typical cancer. The tumor is firm, white, and ill-defined. At the time of diagnosis, it is usually extensive throughout the gland and growing into the adjacent soft tissues. Remnants of structures suggesting either a pre-existing adenoma or less malignant carcinoma frequently are visible (fig. 57).

MICROSCOPIC. The tumor cells are large, often giant size, and pleomorphism of the cells is common (fig. 114). Some of the cells are spindly (fig. 115), resembling those of a fibrosarcoma; still others may resemble the strap cells of a rhabdomyosarcoma (fig. 116). Mixtures of bizarre forms are common. Mitoses are frequent and often atypical. Multinucleated cells are numerous.

*Preferred International Nomenclature

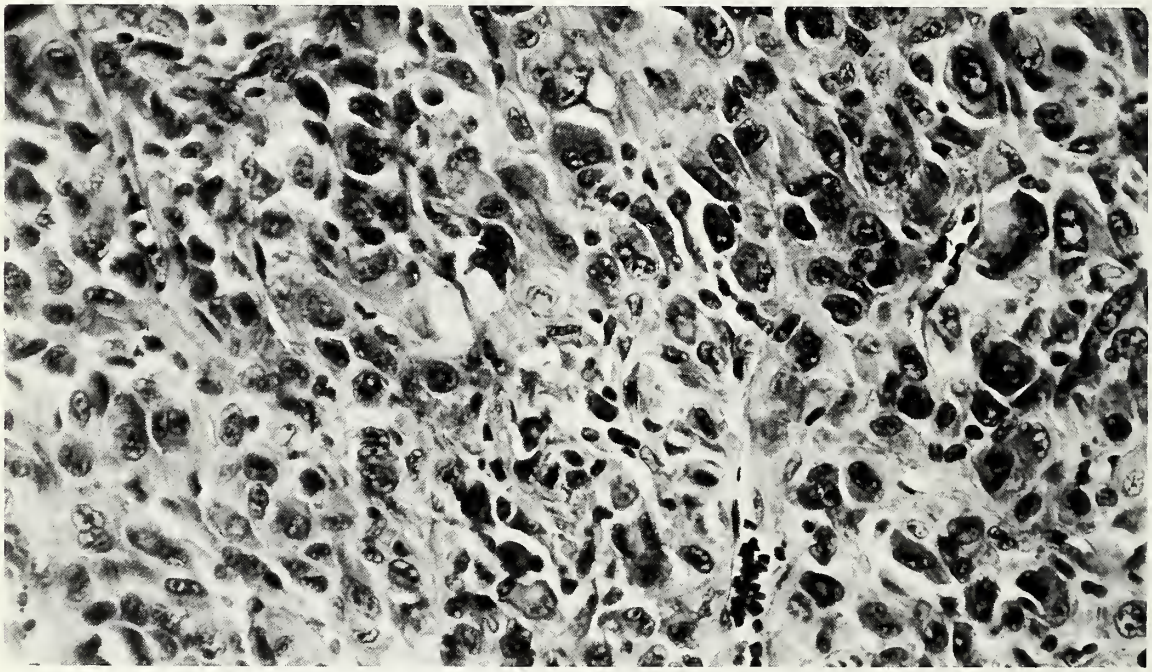

UNDIFFERENTIATED CARCINOMA, GIANT CELL TYPE

Figure 114. In this undifferentiated carcinoma, giant cell type, there is marked pleomorphism of cells with many bizarre nuclei and multinucleated cells. × 400. (This is figure 11 from Clute, H. M., and Warren, S. Cancer of the thyroid gland. Amer. J. Cancer 15:2563–2582, 1931.) A.F.I.P. Acc. No. 219764–68.

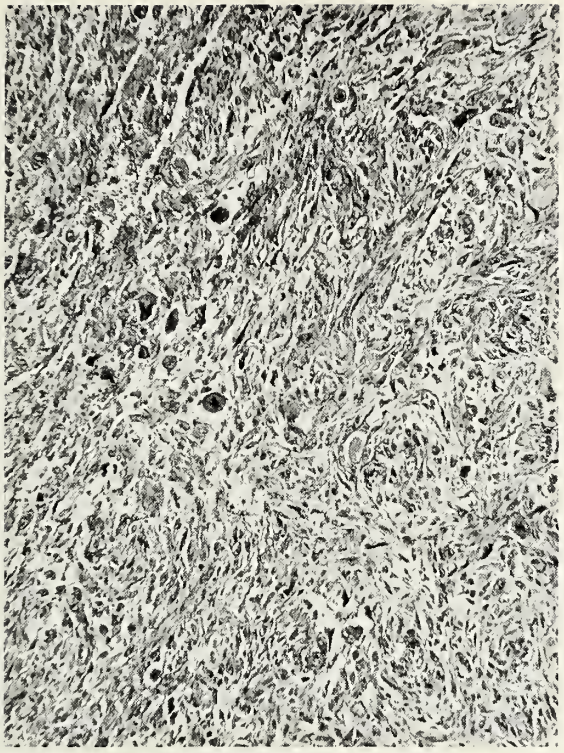

## UNDIFFERENTIATED CARCINOMA, GIANT CELL TYPE

(Figures 115 and 116 are from the same case)

Figure 115. This undifferentiated carcinoma, giant cell type, has numerous spindle cells. A mixture of spindle cells and giant cells often gives these carcinomas a sarcomatous appearance. × 100. A.F.I.P. Atlas No. 67-3-64.

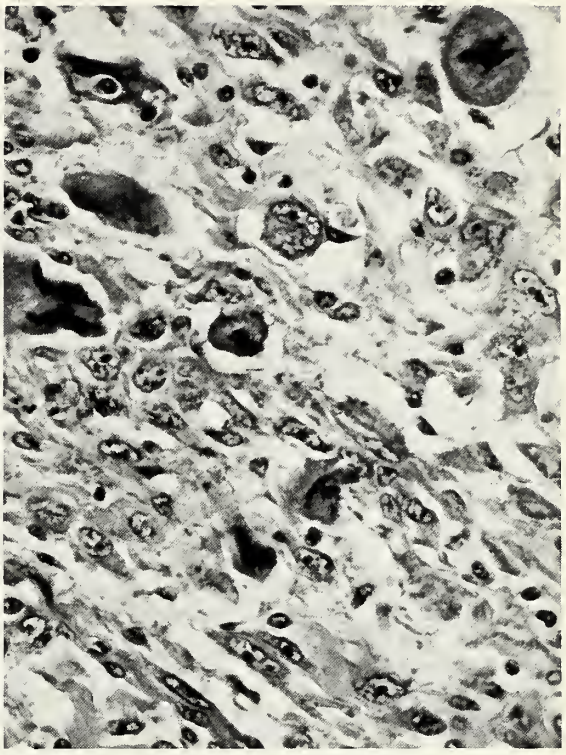

## UNDIFFERENTIATED CARCINOMA, GIANT CELL TYPE

(Figures 115 and 116 are from the same case)

Figure 116. The higher magnification of figure 115 reveals both the bizarre giant cells and the spindle cells. Atypical mitoses are common. × 400. A.F.I.P. Atlas No. 67-3-65.

## CARCINOMA OF MIXED PATTERN

Figure 117. This carcinoma of mixed pattern shows follicular and solid components and a focus of oxyphilic cells centrally. × 100. A.F.I.P. Atlas No. 67-3-68.

Fig. 117

Identifiable epithelial structures, signifying the epithelial origin of the tumor, may be difficult to find without extensive search. Some have admixtures of other carcinoma types (figs. 118, 120).

NATURAL HISTORY. Giant cell carcinoma is almost exclusively a tumor of older age groups; it is rarely found in patients under 60 years of age. It is slightly more frequent in women than in men. It is the most common type of undifferentiated carcinoma of the thyroid. Chesky and associates report that the tumor represents 6.3 per cent of their thyroid cancers. A typical history is that of a thyroid nodule which suddenly increases rapidly in size after having been stationary and without significant change for 15 or more years. More than any other type of thyroid carcinoma, giant cell carcinoma suggests origin from a pre-existing benign tumor or low grade carcinoma. There is clinical (Hare and Salzman) as well as gross and microscopic evidence for this statement. It seems likely that transition to giant cell carcinoma may occur not only from benign adenoma but also from follicular or papillary carcinoma. Such transition has been reported on numerous occasions and seems to be fairly well established. In one case studied by the authors, a papillary carcinoma which had been present for 31 years ultimately changed to a giant cell carcinoma and caused death by massive mediastinal involvement. Although the patient usually comes for medical assistance after a short history of a rapidly growing tumor, in most instances at time of diagnosis the tumor is inoperable and incurable. Extension of the disease into the neck is massive and rapid

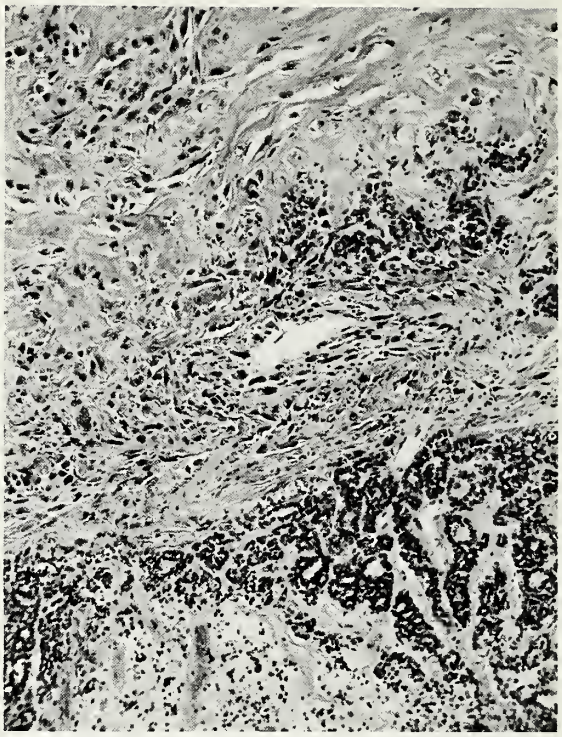

CARCINOMA OF MIXED PATTERN

Figure 118. In this carcinoma of mixed pattern, follicular carcinoma is in the lower part of the field; giant cell and spindle cell carcinoma appear in the upper portion of the field. It is not unusual to find foci of follicular or even papillary carcinoma in predominantly undifferentiated tumors. × 100. A.F.I.P. Atlas No. 67-3-69.

(pl. I–C). While metastases to distant parts of the body are frequent, death usually occurs from local disease before the metastases have time to become of clinical significance.

DIFFERENTIAL DIAGNOSIS. Giant cell carcinoma must be distinguished from other thyroid tumors, both benign and malignant, as well as from metastatic tumors of the thyroid. The resemblance to sarcoma is often striking, but it should be remembered that true sarcoma of the thyroid is rare. The epithelial nature of the giant cell carcinoma

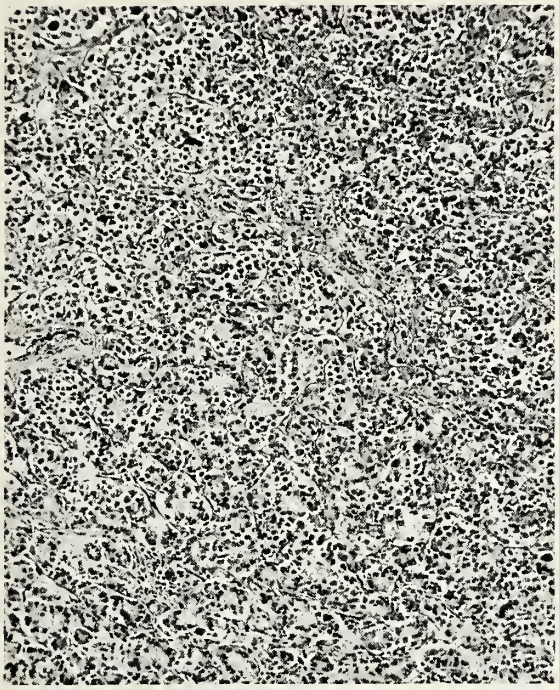

CARCINOMA OF MIXED PATTERN

(Figures 119 and 120 are from the same case)

Figure 119. A carcinoma of mixed pattern of growth shows predominantly follicular and small cell components. × 100. A.F.I.P. Atlas No. 67-3–70.

CARCINOMA OF MIXED PATTERN

(Figures 119 and 120 are from the same case)

Figure 120. Another focus of the same carcinoma of mixed pattern as illustrated in figure 119 shows predominantly undifferentiated carcinoma of small cell and giant cell types. × 100. A.F.I.P. Atlas No. 67-3–71.

may be recognized only after prolonged search for epithelial tumor foci.

Occasionally, clusters of cells of an *osteoclastic* or *foreign-body type* are found in association with various types of thyroid cancer (fig. 121). The multinucleated giant cells do not seem to be an inherent part of the tumor, but rather they seem to represent a reaction to components of the tumor. In the authors' experience, they have most frequently been associated with follicular carcinoma, but occasionally with other types of carcinoma as well. The presence of these cells, therefore, should not lead one to the diagnosis of a giant cell type of undifferentiated carcinoma. Their exact significance is unknown; they do not appear to be reacting to colloid. Similar accumulations of giant cells are sometimes seen associated with cancers of other organs of the body, again without known significance. Rather (1950) reports a case of thyroid tumor in which all the cells were of this giant cell type; he believed that they represented giant cells arising from the lining of blood vessels.

PROGNOSIS. The prognosis of giant cell carcinoma of the thyroid is extremely poor. In a study of 38 cases, Frazell and Foote found that the average duration of life from diagnosis to death was 4.8 months; they state that in no other form of human cancer is a lethal outcome so inevitable. In the series of Silliphant and associates, 44 patients with giant cell cancer died within 3 years.

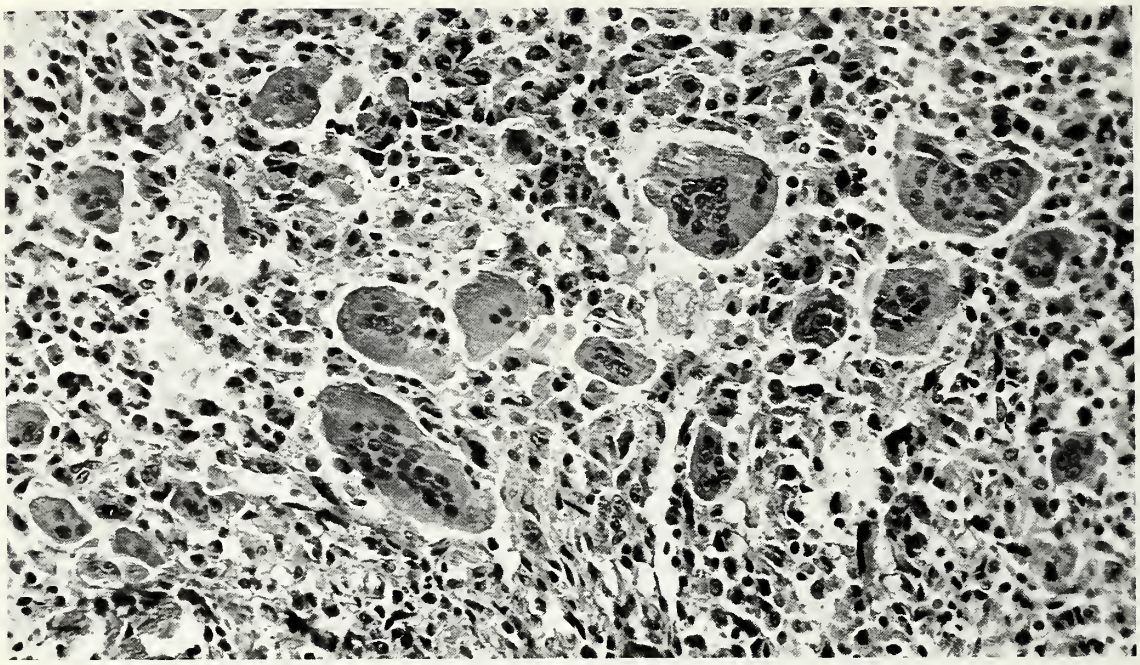

NON-NEOPLASTIC GIANT CELLS IN FOLLICULAR CARCINOMA

Figure 121. This focus of a foreign body or osteoclastic type of giant cell tumor in the thyroid, considered to be non-neoplastic, was found in a gland with follicular carcinoma. The relationship of such giant cells to neoplasms is obscure. × 250. (Courtesy of Dr. Merlin L. Trumbull, Memphis, Tenn.) A.F.I.P. Acc. No. 219764–69.

We have seen one patient treated intensively with x-irradiation who survived 10 years.

TREATMENT. Radical surgery is the treatment of choice if it is feasible. Since most cases are inoperable at the time of diagnosis, the usual treatment is whatever surgery is possible to attempt complete removal of the tumor. Radioiodine is without value. Intensive high voltage irradiation controls the tumor locally in some instances.

## References


Berkheiser, S. W. Malignant giant-cell tumors of thyroid gland. Amer. J. Clin. Path. 24:166–171, 1954.

Chesky, V. E., Hellwig, C. A., and Welch, J. W. Polymorphous cell tumor of the thyroid. Amer. J. Surg. 99:857–865, 1960.

Frazell, E. L., and Foote, F. W., Jr. The natural history of thyroid cancer. A review of 301 cases. J. Clin. Endocr. 9:1023–1030, 1949.

Hare, H. F., and Salzman, F. A. Cancer of the thyroid. Ten to twenty-year follow-up. Amer. J. Roentgen. 63:881–888, 1950.

Hutter, R. V., Tollefsen, H. R., DeCosse, J. J., et al. Spindle and giant cell metaplasia in papillary carcinoma of the thyroid. Amer. J. Surg. 110:660–668, 1965.

Rather, L. J. A note on the origin of multinucleated giant cells from vascular channels in tumors; tumors arising in thyroid gland, bone, and soft tissue. Arch. Path. 52:98–103, 1951.

———. Giant cell tumors of the thyroid. Stanford M. Bull. 8:202–208, 1950.

Silliphant, W. M., Klinck, G. H., and Levitin, M. S. Thyroid carcinoma and death. A clinicopathological study of 193 autopsies. Cancer 17:513–525, 1964.

Smedal, M. I., and Meissner, W. A. The results of x-ray treatment in undifferentiated carcinoma of the thyroid. Radiology 76:927–935, 1961.

## EPIDERMOID CARCINOMA (Figure 122)

Primary epidermoid carcinoma (squamous cell carcinoma) of the thyroid is rare. Goldman, in 1964, analyzed nine series of thyroid cancers and found only 22 reported cases of epidermoid carcinoma—an incidence of 1.1 per cent of all thyroid cancers. Most cases occur in the fifth and sixth decades without sex predilection. A long history of goiter is usual. The tumors appear clinically and grossly similar to glandular carcinoma. Although often fairly well differentiated, as evidenced microscopically by keratinization or pearl formation, they are quite malignant and relatively unresponsive to radiation therapy.

Squamous metaplasia occurs in glandular, especially papillary, carcinoma. When the metaplasia is extensive, such tumors have been called adenoacanthomas (Cocke and Carrera).

DIFFERENTIAL DIAGNOSIS. The possibility must always be considered that epidermoid carcinoma in the thyroid may be a metastasis or an extension from a primary tumor in the trachea or esophagus. Squamous metaplasia in benign conditions, such as thyroiditis, must also be considered in the differential diagnosis.

EPIDERMOID CARCINOMA

Figure 122. This epidermoid carcinoma was thought to be primary in the thyroid since no carcinoma was found elsewhere. However, a similar pattern could be produced by metastatic tumor. × 100. A.F.I.P. Atlas No. 67-3-67.

### References

Bullock, W. K., Hummer, G. J., and Kahler, J. E. Squamous metaplasia of the thyroid gland. Cancer 5:966–974, 1962.

Cocke, W. M., Jr., and Carrera, G. M. Mixed squamous cell carcinoma and papillary adenocarcinoma (adenoacanthoma) of the thyroid gland. Amer. J. Surg. 108:432–433, 1964.

Goldman, R. L. Primary squamous cell carcinoma of the thyroid gland: report of a case and review of the literature. Amer. Surg. 30:247–252, 1964.

PLATE I

## FIBROUS NODULE OF ADENOMATOUS GOITER

A. This nodule, removed from a 55-year-old woman, was suspected grossly of being carcinoma because of its firmness and lack of encapsulation, but microscopically it proved to be merely a fibrous nodule of adenomatous goiter. Diagnosis of cancer of the thyroid from the gross appearance may be difficult. A.F.I.P. Atlas No. 67-3-79.

## FOLLICULAR ADENOMA

B. This shows the cut surface of a fleshy, well demarcated follicular adenoma. The small white nodule at the top of the specimen is an incidental finding which proved to be follicular carcinoma. A.F.I.P. Atlas No. 67-3-80.

## MASSIVE BLOOD VESSEL INVASION

C. Massive blood vessel invasion of the jugular vein has occurred. The vein has been opened to show that it is filled with a direct extension of undifferentiated carcinoma from the thyroid. Vascular invasion by thyroid carcinoma is common, but rarely is it this prominent. A.F.I.P. Atlas No. 67-3-81.

## BLOOD VESSEL INVASION

D. In this photomicrograph of blood vessel invasion by carcinoma, the accentuation of the internal elastic lamellae by Verhoeff stain is helpful in identifying intravascular growth. Verhoeff stain. × 150. A.F.I.P. Atlas No. 67-3-82.

A

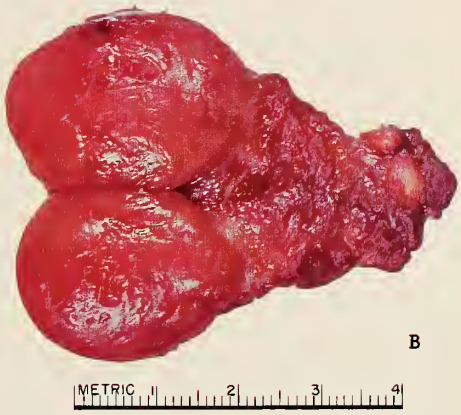


B

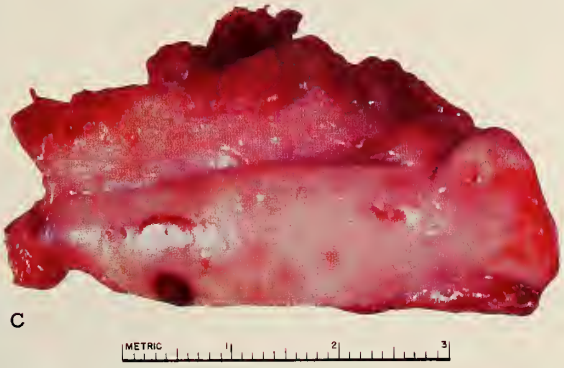


C

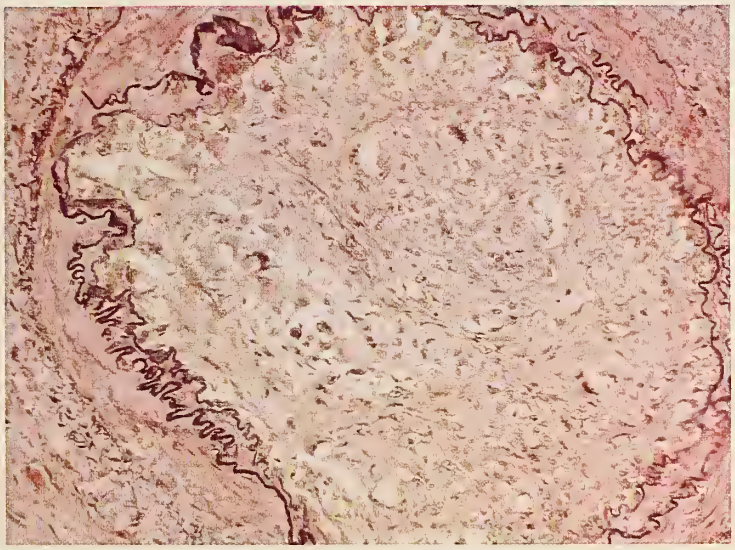

D

PLATE I

PLATE II

## PAPILLARY CARCINOMA

A. This photomicrograph shows a typical intracystic frond of papillary carcinoma. Psammoma bodies are present in the stalk. × 150. A.F.I.P. Atlas No. 67-3-83.

## IMPLANTS OF PAPILLARY CARCINOMA

B. This recurrent papillary carcinoma was found in soft tissue of the neck. The recurrences were thought to be implants in suture tracts. × 100. A.F.I.P. Atlas No. 67-3-84.

## SMALL PRIMARY PAPILLARY CARCINOMA

C. A 37-year-old man had a completely encapsulated, slightly cystic mass removed from the lateral neck area. The diagnosis was metastatic papillary adenocarcinoma. Although the thyroid was normal to palpation, the thyroidectomy specimen showed the 0.3 cm. primary papillary adenocarcinoma illustrated here. The primary tumor was one-tenth the diameter of the metastasis in the cervical lymph node. × 30. A.F.I.P. Atlas No. 67-3-85.

## OXYPHILIC VARIANT OF FOLLICULAR CARCINOMA

D. This photomicrograph illustrates an oxyphilic variant of follicular carcinoma. × 500. A.F.I.P. Atlas No. 67-3-86.

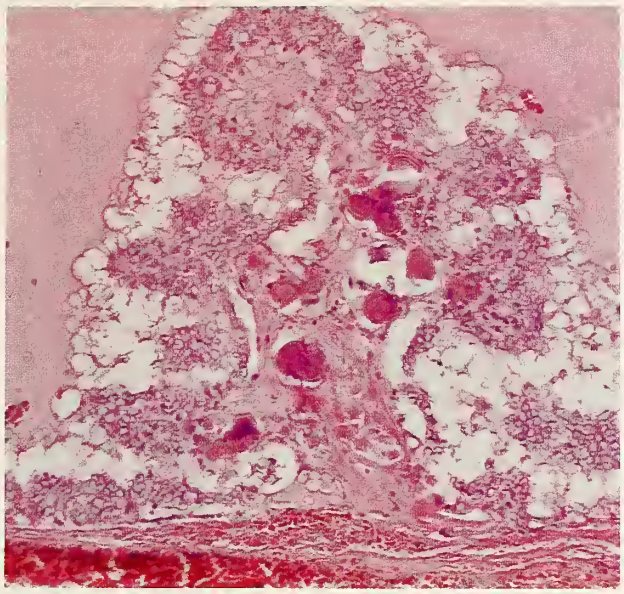

A

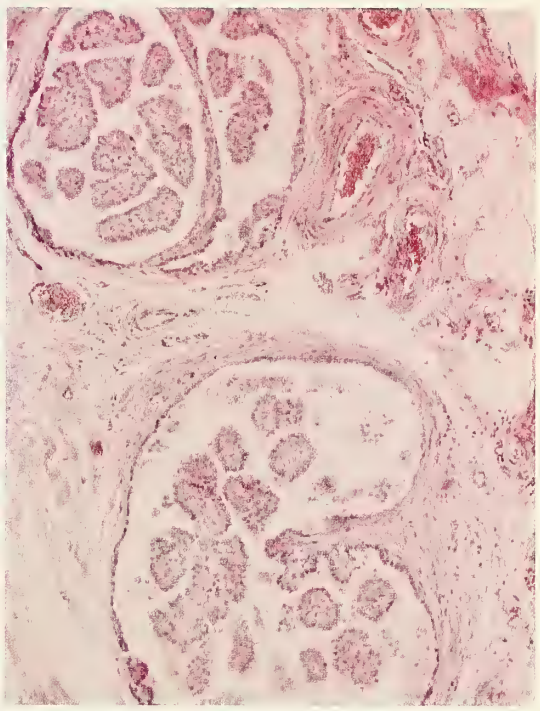

B

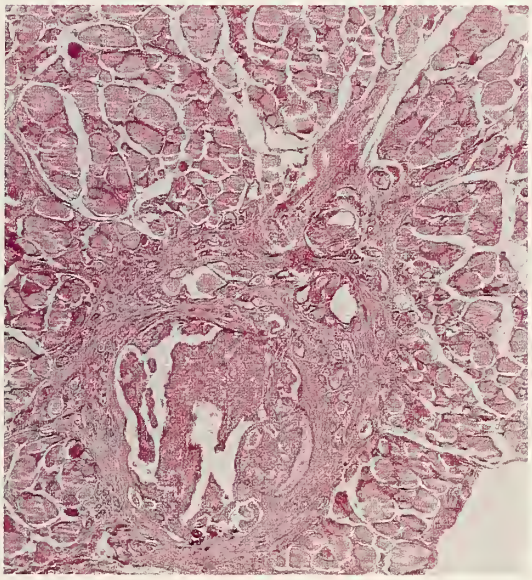

C

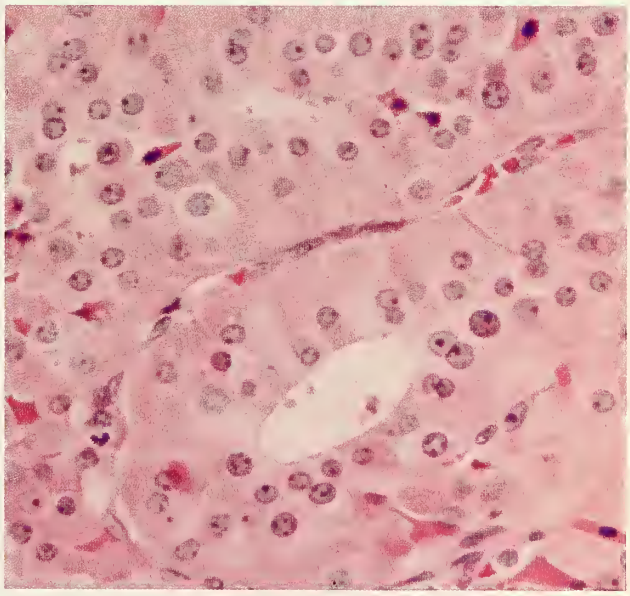

D

PLATE II

PLATE III

## METASTATIC MALIGNANT MELANOMA

A. A metastatic malignant melanoma in the thyroid was removed from a 31-year-old woman who died from multiple metastases of a malignant melanoma of the skin. There are three nodules of tumor in the thyroid, one of which is pigmented. A.F.I.P. Atlas No. 67-3-92.

## UNDIFFERENTIATED CARCINOMA OF THYROID

B. This undifferentiated carcinoma of thyroid of mixed type was removed from a 77-year-old woman. There are multiple foci of the tumor appearing in the gland. A.F.I.P. Atlas No. 67-3-93.

## STRUMA LYMPHOMATOSA

C. This struma lymphomatosa illustrates the typical moderate, symmetrical enlargement and lobular yellow-gray appearance. A.F.I.P. Acc. No. 219764-C1.

## METASTATIC CARCINOMA FROM STOMACH

D. This metastatic carcinoma of the stomach invaded the thyroid gland. Although the tumor is growing partly in papillary fashion, the individual cells are mucus-secreting and do not resemble primary thyroid carcinoma. × 33. A.F.I.P. Atlas No. 67-3-94.

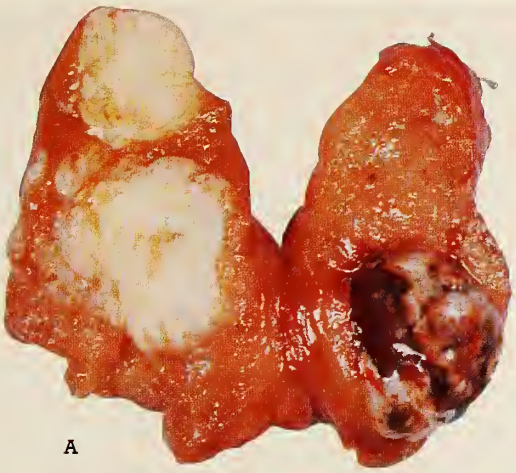

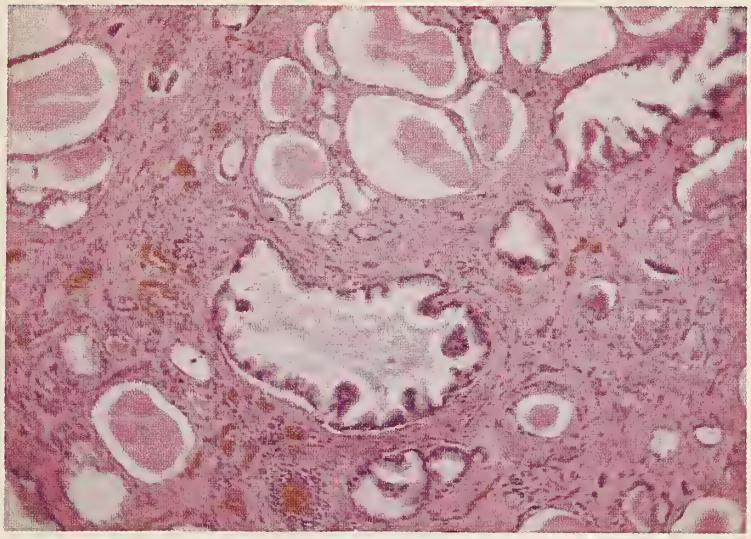


PLATE III

PLATE IV

## METASTATIC PAPILLARY CARCINOMA OF THYROID TO LUNG

(Plate IV–D, E and Figures 103 and 107 are from the same case)

A. A 66-year-old man had numerous recurrences of papillary adenocarcinoma of the thyroid over a period of 29 years before he died from massive mediastinal involvement. The only other metastases were in both lungs and in peritracheal lymph nodes. An incidental finding was a small islet cell carcinoma of the pancreas. × 33. A.F.I.P. Atlas No. 67-3–95.

## SQUAMOUS METAPLASIA IN PAPILLARY ADENOCARCINOMA

B. This shows a focus of squamous metaplasia in papillary adenocarcinoma of the thyroid. × 83. A.F.I.P. Atlas No. 67-3–96.

## MEDULLARY CARCINOMA

C. A medullary carcinoma with amyloid stroma of the thyroid was removed from a 26-year-old woman. The poorly demarcated primary tumor was in the left upper lobe. There were metastases in 5 of 37 cervical lymph nodes. A.F.I.P. Atlas No. 67-3–97.

## MEDULLARY CARCINOMA

D. In this medullary carcinoma with amyloid stroma, the amyloid is evident both by the positive Congo-red stain and its birefringence (see figures 103 and 107). × 100. A.F.I.P. Atlas No. 67-3–98.

## MEDULLARY CARCINOMA

E. This illustrates the amyloid fluorescence after staining with thioflavin T. × 100. A.F.I.P. Atlas No. 67-3–99.

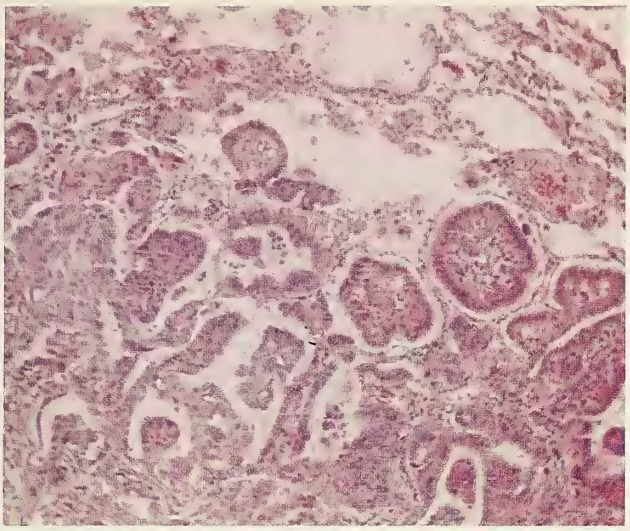

A

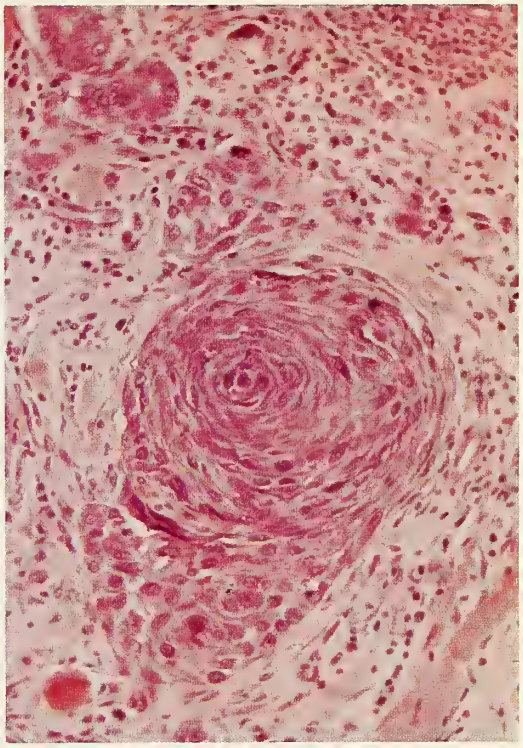

B

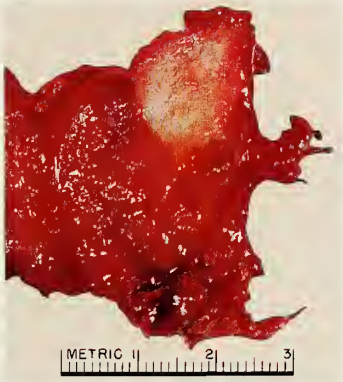


C

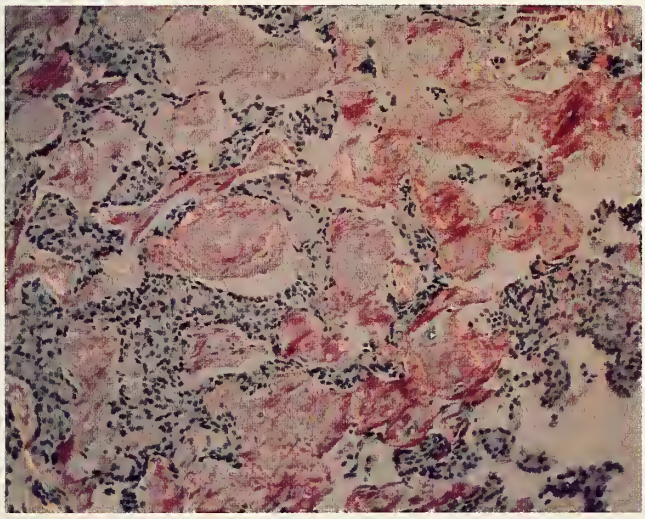

D

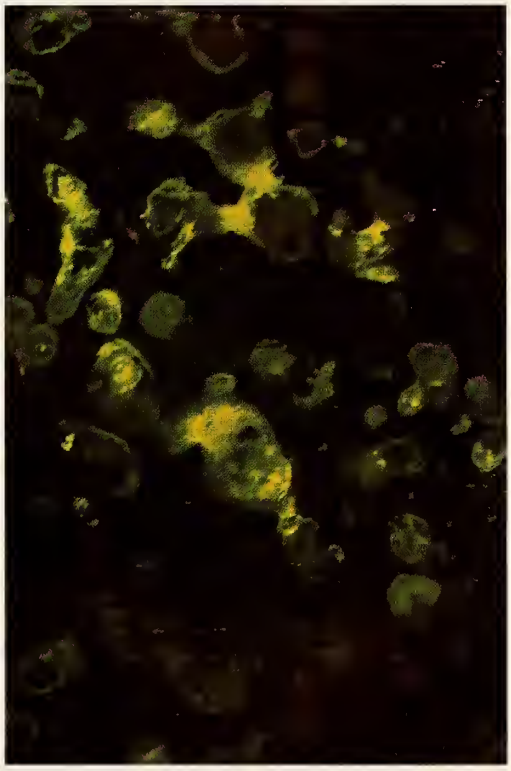

E

PLATE IV

## MISCELLANEOUS MALIGNANT TUMORS

**LYMPHOMA OF THE THYROID** (Figures 123, 124)

In the past, the opinion has been expressed that *all* malignant tumors of the thyroid were carcinoma. There are instances, however, in which thyroid tumor seems to have all the requisites for diagnosis of **primary lymphoma.** This is not unexpected since primary lymphomatous tumors are known to arise in other parenchymatous organs of the body. Walt and associates reported 30 cases of small cell cancer of the thyroid, 18 of which were classified as lymphomas. Lymphosarcoma (fig. 123) has been reported by Dinsmore and associates, and reticulum cell sarcoma by Winship and Green. Kellett and Sutherland reported "reticulosarcoma" of the thyroid gland. Shaw and Smith reported plasmocytoma of the thyroid (fig. 124). Mikal reviewed 165 reported cases of lymphoma of the thyroid and noted that reticulum cell sarcoma was the most common type, with lymphosarcoma next; 13 of the cases were diagnosed as Hodgkin's disease. Woolner and associates noted the difficulty of an exact classification of many thyroid lymphomas.

All reports agree that the distinction clinically and grossly between lymphoma and carcinoma is extremely difficult, and even with microscopic examination, the similarity between small cell carcinoma and lymphoma is often remarkable. Reticulin and PAS stains are of little help in differentiating lymphoma from carcinoma in the thyroid. Scott has pointed out that the cytologic appearance and the presence or absence of reticulum in the tumor are unreliable diagnostic criteria for the differentiation of lymphoma from carcinoma. He concluded it is only by the demonstration of other foci of tumor outside the thyroid, which leaves little doubt that they are lymphoma, that the final diagnosis can be made with any degree of certainty. Meissner and Phillips state that with any small cell cancer of the thyroid,

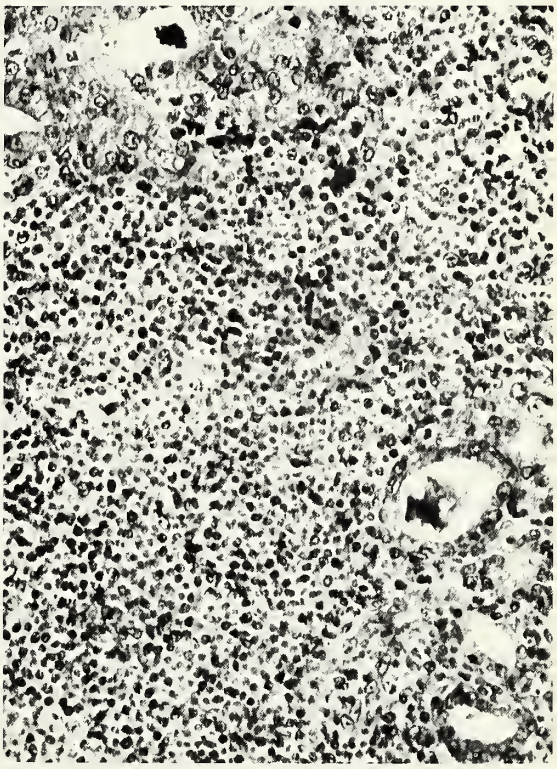

LYMPHOSARCOMA INVOLVING THYROID

Figure 123. This lymphosarcoma was thought to be primary in the thyroid, but actually is indistinguishable from secondary lymphoma. × 250. A.F.I.P. Acc. No. 219764–77.

multiple sections, preferably from outside the gland, may need to be examined in order to determine whether the tumor is forming epithelial structures (figs. 112, 113). It was their feeling that while primary lymphoma of the thyroid does occur, in many instances the diagnosis of lymphoma might have been changed to small cell carcinoma if sufficient sections had been studied.

The occasional problem of differentiation of lymphoma from thyroiditis is emphasized by Brewer and Orr. Rarely lymphoma seems to arise in struma lymphomatosa (Kenyon and Ackerman). Serological tests (anti-thyroid antibodies) often indicate a concomitant or pre-existent thyroiditis, according to Cox.

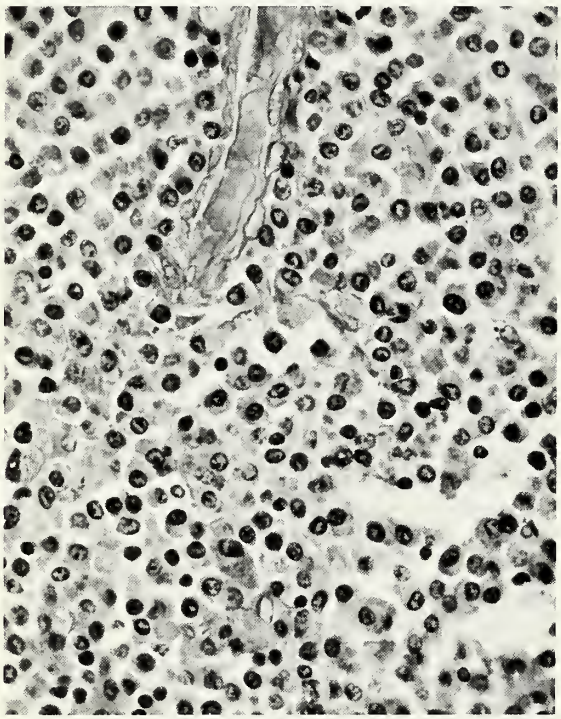

PLASMACYTOMA

Figure 124. In this case, the patient did not have multiple myeloma, and there were no other apparent foci of plasmacytoma. Many types of lymphoid tumors have been described as arising in or involving the thyroid. Plasmacytoma is one of the less frequent types. × 400. A.F.I.P. Atlas No. 67-3-66.

The course and prognosis of primary lymphoma of the thyroid are open to some disagreement, probably because it is difficult to make a definitive diagnosis. Furthermore, some cases presenting clinically as primary thyroid lymphoma, later prove to be disseminated lymphoma with prominent secondary involvement of the thyroid. Some cases diagnosed as lymphoma have responded very favorably to irradiation therapy, as have lymphomas in other parts of the body; others—perhaps unrecognized small cell carcinomas—have responded poorly. The greater responsiveness of lymphoma to irradiation may be helpful in differentiating lymphoma from carcinoma.

**Secondary lymphoma** involvement of the thyroid gland by generalized lymphoma is common. In a review by Meissner and Phillips of 100 consecutive autopsies on patients with generalized lymphoma, 20 cases showed thyroid involvement: Hodgkin's disease, 4; lymphosarcoma, 5; reticulum cell sarcoma, 4; lymphocytoma, 3; and macrofollicular lymphoma, 4. The 13 women and 7 men ranged from 25 to 86 years of age; most were in the 40 to 60-year age group. Thyroid involvement was the presenting symptom in only three instances; in one, treatment by radical surgery plus irradiation destroyed the local disease before widespread lymphoma was discovered, and the patient died 21 months after treatment.

Involvement of the thyroid in generalized lymphoma varies from minimal microscopic foci to gross replacement of the gland. Of the 20 cases previously mentioned, 14 patients had concomitant involvement of the cervical lymph nodes and 18 of the 20 showed lymphomatous foci, often massive, in the gastrointestinal tract.

In patients dying with generalized lymphoma, the thyroid involvement was easily diagnosed as lymphoma, and distinction from small cell carcinoma was rarely a problem histologically. Examination of foci of tumor which extended beyond the thyroid capsule was of great value, since confusion of the tumor with distorted residual atrophic follicles was avoided. Blood vessel invasion was rare in contrast with small cell carcinoma.

### References


Brewer, D. B., and Orr, J. W. Struma reticulosa: a reconsideration of the undifferentiated tumours of the thyroid. J. Path. Bact. 65:193–208, 1953.

Cox, M. T. Malignant lymphoma of the thyroid. J. Clin. Path. 17:591–601, 1964.

Dinsmore, R. S., Dempsey, W. S., and Hazard, J. B. Lymphosarcoma of the thyroid. J. Clin. Endocr. 9:1043–1047, 1949.

Kellett, H. S., and Sutherland, T. W. Reticulosarcoma of the thyroid gland. J. Path. Bact. 61:233–244, 1949.

Kenyon, R., and Ackerman, L. V. Malignant lymphoma of thyroid apparently arising in struma lymphomatosa. Cancer 8:964-969, 1955.

Meissner, W. A., and Phillips, M. J. Diffuse small-cell carcinoma of the thyroid. Arch. Path. 74:291–297, 1962.

Mikal, S. Primary lymphoma of the thyroid gland. Surgery 55:233–239, 1964.

Scott, G. B. Diagnosis of reticulosarcoma of thyroid gland. J. Clin. Path. 5:183–189, 1952.

Shaw, R. C., and Smith, F. B. Plasmocytoma of the thyroid gland: report of a case. Arch. Surg. 40:646–657, 1940.

Walt, A. J., Woolner, L. B., and Black, B. M. Primary malignant lymphoma of the thyroid. Cancer 10:663–677, 1957.

Winship, T., and Greene, R. Reticulum cell sarcoma of the thyroid gland. Brit. J. Cancer 9:401–408, 1955.

Woolner, L. B., McConahey, W. M., Beahrs, O. H., et al. Primary malignant lymphoma of the thyroid. Review of forty-six cases. Amer. J. Surg. 111:502–523, 1966.


**OTHER SARCOMAS** (Figures 125–130)

Sarcomas of the thyroid other than those of the lymphoma group are extremely rare and make up less than 1 per cent of all thyroid cancers. There is a tendency to overdiagnose sarcoma of the thyroid since many cases resembling sarcoma prove, after more careful examination, to be spindle cell or giant cell carcinoma. The true nature of such tumors may be determined only after study of multiple foci of the tumor (Smith; Buckwalter and Nordschow). Figures 115, 116, and 118 through 120 illustrate how the diagnosis of sarcoma (either fibrosarcoma or hemangiosarcoma) might have been made if insufficient sections had been studied. Just as in the breast and other epithelial organs, carcinoma of the thyroid sometimes stimulates unusual stromal activity with excessive proliferation of fibrous tissue (fig. 125) and

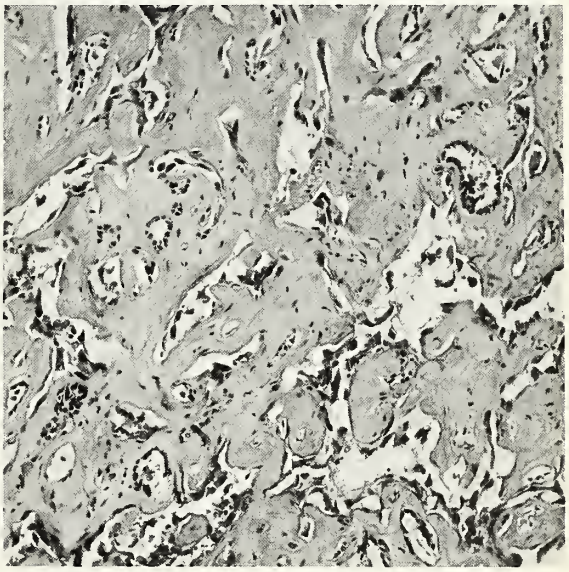

FOLLICULAR CARCINOMA WITH DESMOPLASIA

Figure 125. This follicular carcinoma had an unusually desmoplastic stromal response. The stroma did not stain for amyloid. × 100. A.F.I.P. Atlas No. 67-3-74.

even formation of bone (fig. 126) and cartilage. Carcinomas with such actively proliferating stroma are always difficult to evaluate. While most such tumors in the thyroid probably represent carcinomas, there have been a few cases of coexistent carcinoma and sarcoma which seem to be fairly well authenticated and have been diagnosed as carcinosarcoma (Arean and Schildecker).

The few cases of pure sarcoma in the thyroid that have been reported include fibrosarcoma (figs. 127, 128), hemangiosarcoma (figs. 129, 130), osteogenic sarcoma, osteochondrosarcoma, and malignant hemangiopericytoma. There are too few cases of individual types to permit conclusions regarding natural history, prognosis, and therapy. As a group, however, such sarcomas tend to occur in older people and to have a high degree of malignancy.

FOLLICULAR CARCINOMA WITH OSSEOUS METAPLASIA

Figure 126. This follicular carcinoma had a bizarre stromal response. The stroma shows active proliferation of spindle cells and foci of new bone formation. The stromal response and new bone formation are probably metaplasia rather than tumor. × 100. A.F.I.P. Atlas No. 67-3-75.

FIBROSARCOMA

(Figures 127 and 128 are from the same case)

Figure 127. A fibrosarcoma of the thyroid shows extension into adjacent fat. True primary fibrosarcomas of the thyroid are rare. Most spindle cell tumors of the thyroid are variants of undifferentiated carcinoma of the giant cell type. × 48. A.F.I.P. Acc. No. 219764-73.

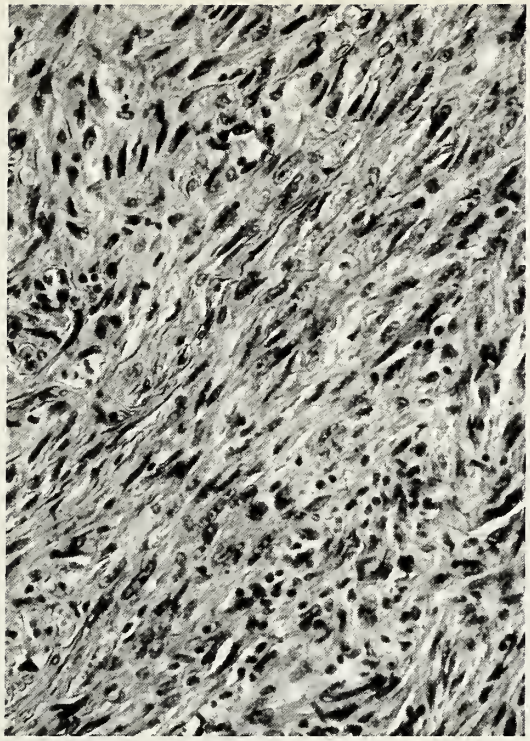

## FIBROSARCOMA

(Figures 127 and 128 are from the same case)

Figure 128. This is a higher magnification of the fibrosarcoma of the thyroid illustrated in figure 127. × 250. A.F.I.P. Acc. No. 219764–74.

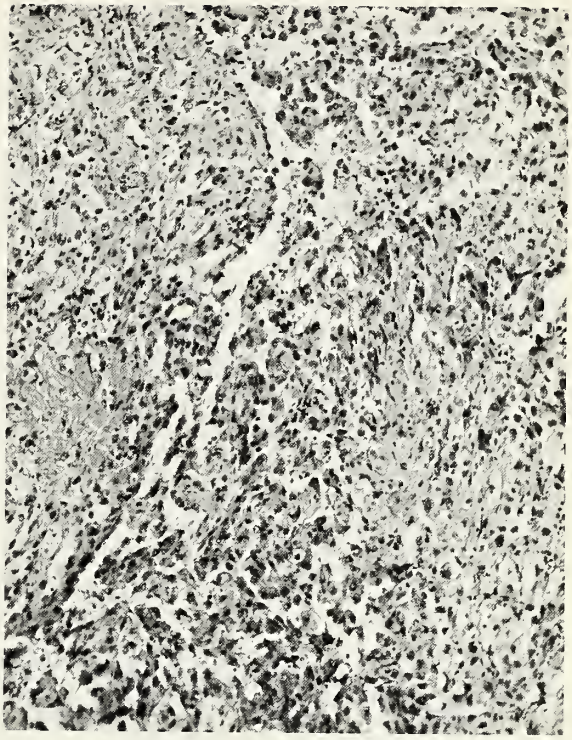

## UNCLASSIFIED TUMOR

(Figures 129 and 130 are from the same case)

Figure 129. This undifferentiated malignant tumor in the thyroid cannot be classified from this field; however, many tumors that show this pattern contain foci of recognizable carcinoma disclosing the true nature of the tumor. × 100. A.F.I.P. Atlas No. 67-3–72.

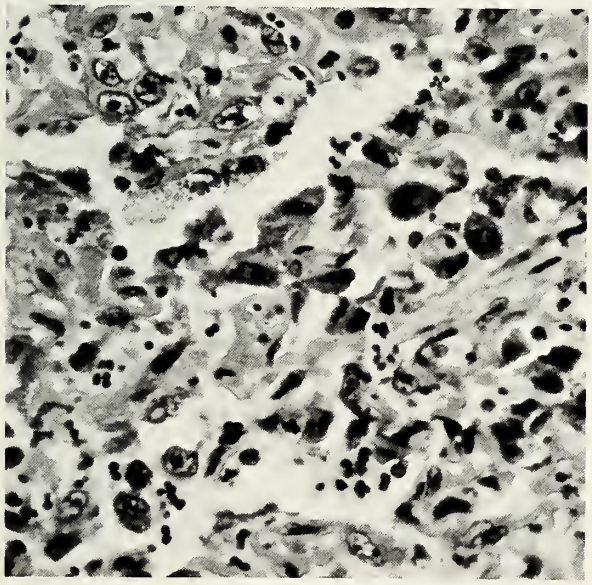

Fig. 130

Figure 130. A higher magnification of figure 129 is shown. Tumors of this appearance have been called hemangioendotheliomas or hemangiosarcomas of the thyroid. The authors feel, however, that these tumors usually represent undifferentiated carcinomas, and their epithelial nature can be demonstrated after examination of multiple sections. × 400. A.F.I.P. Atlas No. 67-3–73.

Chesky and associates (1960) reported 4 cases of fibrosarcoma in 628 cases of cancer of the thyroid and were able to find only 4 other cases reported from the United States. Marks and associates described a metastasizing fibrosarcoma involving the thyroid gland of the sheep exposed continuously to 5 millicuries of $I^{131}$ for a period of four and one-half years.

Livingstone and Sandison reported an osteogenic sarcoma of the thyroid in a 36-year-old woman; the tumor showed metaplastic as well as neoplastic bone and a transition to chondroid tissue. Although there were two recurrences after initial surgery, the patient was well five years after the original diagnosis.

It should be noted that the diagnosis of hemangiosarcoma is much more frequent in Switzerland than in the United States.

A malignant hemangiopericytoma of the thyroid with multiple metastases was reported by Prokš.

### References

Arean, V. M., and Schildecker, W. W. Carcinosarcoma of the thyroid gland; report of two cases. Southern Med. J. 57:446–451, 1964.

Buckwalter, J. A., and Nordschow, C. D. A moot thyroid neoplasm: carcinoma or sarcoma. Ann. Surg. 148:115–118, 1958.

Chesky, V. E., Dreese, W. C., and Hellwig, C. A. Hemangioendothelioma of thyroid; review of literature and report of case. J. Clin. Endocr. 13:801–808, 1953.

———, Hellwig, C. A., and Welch, J. W. Fibrosarcoma of the thyroid gland. Surg. Gynec. Obstet. 111:767–770, 1960.

Livingstone, D. J., and Sandison, A. T. Osteogenic sarcoma of thyroid. Brit. J. Surg. 50:291–293, 1962.

Marks, S., George, L. A., Jr., and Bustad, L. K. Fibrosarcoma involving the thyroid gland of a sheep given $I^{131}$ daily. Cancer 10:587–591, 1957.

Prokš, C. Generalized hemangiopericytoma of the thyroid gland. Report of a case. Neoplasma (Bratisl) 8:219–224, 1961.

Smith, L. W. Certain so-called sarcomas of the thyroid. Arch. Path. 10:524–530, 1930.

Walther, Hans E. Krebsmetastasen. Basel: Benno Schwabe and Co., Verlag, 1948.

## MALIGNANT TERATOMA OF THE THYROID AND THYROID REGION

Of 86 cases collected from the literature by Newstedt and Shirkey, 82 teratomas were in infants and 4 were in adults. In one of the infants the teratoma was questionably malignant. Three of the 4 teratomas in adults, however, metastasized widely either as anaplastic sarcomas or as tumors of mixed tissue types. One of the teratomas is the interesting case in an adult reported by Keynes in which the teratoma was removed at 4 months of age and recurred 24 years later as a benign-appearing teratoma containing thyroid tissue, muscle, gastrointestinal mucosa, pancreas, cartilage, and glial tissue.

### References

Buckwalter, J. A., and Layton, J. M. Malignant teratoma in thyroid gland of adult. Ann. Surg. 139:218–223, 1954.

Keynes, W. M. Teratoma of the neck in relation to the thyroid gland. Brit. J. Surg. 46:466–472, 1959.

Newstedt, J. R., and Shirkey, H. C. Teratoma of the thyroid region. Report of a case with seven-year follow-up. Amer. J. Dis. Child. 107:88–95, 1964.

**CARCINOMA IN ECTOPIC THYROID TISSUE** (Figure 131)

Carcinomas occasionally arise in remnants of the thyroglossal duct; about 25 cases have been reported. They may appear at any age, are more common in women, and are almost invariably papillary adenocarcinomas. The prognosis generally is good, although a few tumors have metastasized and resulted in death. Carcinoma arising in sublingual ectopic thyroid tissue is more common and instead of being almost exclusively papillary adenocarcinomas as those arising in the thyroglossal duct, surprisingly, the tumors have been of the various types encountered in the main gland. Tumors arising from other ectopic thyroid tissues are extremely rare.

METASTATIC STRUMA OVARII

Figure 131. An implant of well differentiated follicular carcinoma is illustrated in the serosa of the appendix. The site of the primary tumor was bilateral struma ovarii (see figure 19). × 40. A.F.I.P. Atlas No. 67-3-76.

About 40 adenocarcinomas of the thyroid (mostly follicular) have been reported arising in struma ovarii; many have implanted on the peritoneum or have metastasized to liver, brain, or bone (fig. 131) (Gonzalez-Angulo et al.).

### References

Fish, J., and Moore, R. M. Ectopic thyroid tissue and ectopic thyroid carcinoma: a review of the literature and report of a case. Ann. Surg. 157:212–222, 1963.

Gonzalez-Angulo, A., Kaufman, R. H., Braungardt, C. D., Chapman, F. C., and Hinshaw, A. J. Adenocarcinoma of thyroid arising in struma ovarii (malignant struma ovarii). Report of two cases and review of the literature. Obstet. Gynec. 21:567–576, 1963.

Snedecor, P. A., and Groshong, L. E. Carcinoma of the thyroglossal duct. Surgery 58:969–978, 1965.

**SECONDARY TUMOR IN THYROID** (Figures 132–135; plate III–A, D)

The thyroid gland is such a vascular organ that it is not surprising to find a high incidence of metastasis to the gland. In a review of metastatic spread in 5,673 autopsies from our laboratory on patients who had cancer, but did not necessarily die from it, 9.5 per cent of cancers of the breast and 8.5 per cent of cancers of the lung metastasized to the thyroid gland, and 20 per cent of cancers of the skin of the trunk, largely melanomas (pl. III–A), metastasized to the thyroid. With routine examination of the gland, the

incidence of metastasis to the thyroid in patients who died of cancer has generally been reported from 3 to 5 per cent. However, with meticulous examination, Silverberg and Vidone found that 24 per cent of 62 metastasizing tumors had metastasized to the thyroid. The most common tumors to metastasize to the thyroid are malignant melanoma, bronchogenic carcinoma, renal carcinoma (figs. 132, 133), and carcinoma of the breast (figs. 134, 135) (Walther). From our own laboratory, a study of 100 consecutive autopsies of patients who died of lymphoma showed thyroid involvement in 20 per cent.

METASTATIC RENAL CELL CARCINOMA TO THYROID

(Figures 132 and 133 are from the same case)

Figure 132. A 104 gm. hemorrhagic nodular substernal goiter was removed from a 69-year-old man who complained of respiratory distress. It was composed almost entirely of metastatic renal cell carcinoma. A left nephrectomy for renal cell carcinoma had been performed one and one-half years earlier. × 125. A.F.I.P. Atlas No. 67-3–77.

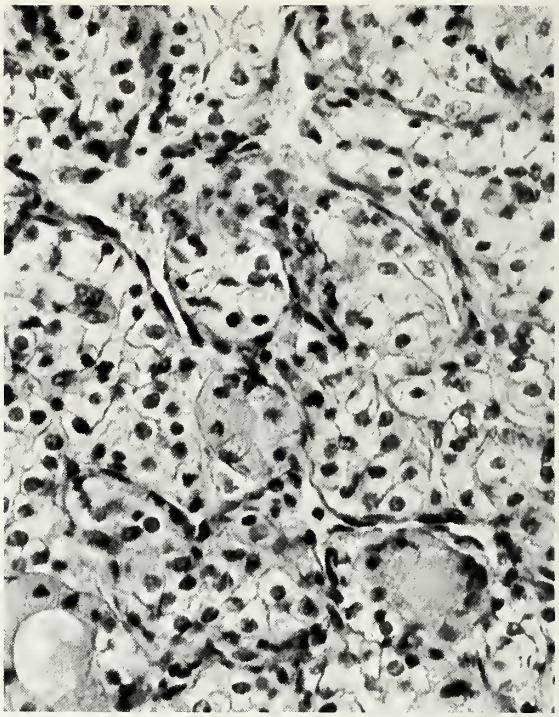

METASTATIC RENAL CELL CARCINOMA TO THYROID

(Figures 132 and 133 are from the same case)

Figure 133. This is a higher magnification of the metastatic renal cell carcinoma to thyroid illustrated in figure 132. Note the similarity to primary clear cell carcinoma of the thyroid as shown in figures 97 and 98. × 400. A.F.I.P. Atlas No. 67-3–78.

While the incidence of metastasis to the thyroid gland is high, the incidence of metastatic tumors to the thyroid masquerading as primary thyroid cancer is relatively low. Elliott and Frantz in 1960 reported 14 cases of metastatic tumor to the thyroid which simulated primary tumor and resulted in surgical operation. These 14 cases occurred in a service where surgery had been performed in more than 500 cases of thyroid cancer. They found 44 other cases that had been reported. The most common metastatic tumor to masquerade as a primary thyroid neoplasm is renal cell carcinoma.

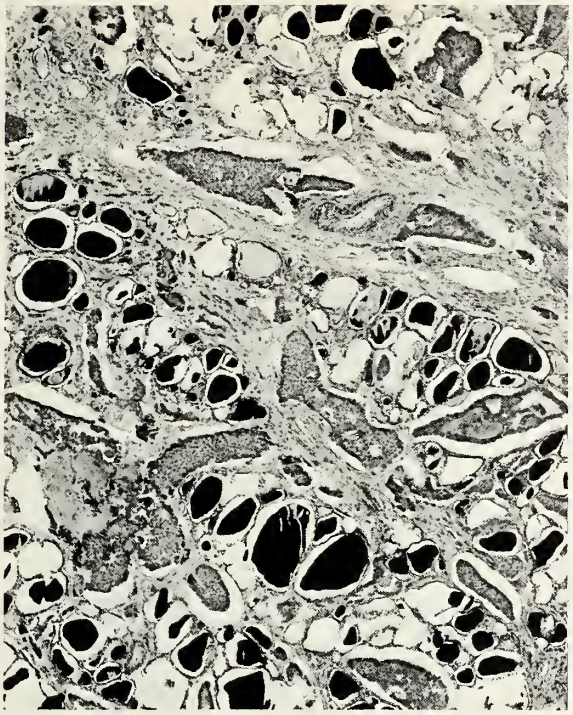

METASTATIC ADENOCARCINOMA TO THYROID

(Figures 134 and 135 are from the same case)

Figure 134. This adenocarcinoma which was metastatic to the thyroid is composed of poorly differentiated cells. The primary tumor was in the breast. × 48. A.F.I.P. Acc. No. 219764–78.

METASTATIC ADENOCARCINOMA TO THYROID

Figure 135. A higher magnification of figure 134 reveals metastatic carcinoma in the stroma. Follicles also may be invaded by the metastatic tumor cells. Carcinoma of the breast is one of the tumors that commonly metastasizes to the thyroid. × 200. A.F.I.P. Acc. No. 219764–79.

Many other tumors may similarly metastasize to the thyroid and mimic primary thyroid cancer however; these include carcinoma of the breast, lung, and even rectum. As suggested previously, differentiation of metastatic renal cell carcinoma from clear cell carcinoma primary in the thyroid (figs. 97, 98) may be very difficult. In a patient with a history of renal cell carcinoma, or for that matter of any metastasizing cancer, the possibility that a thyroid mass may be a metastasis should always be considered. From the practical point of view, usually a biopsy or even removal of the bulk of the mass is necessary in order to make the definitive diagnosis.

## References

Elliott, R. H., Jr., and Frantz, V. K. Metastatic carcinoma masquerading as primary thyroid cancer. A report of authors' 14 cases. Ann. Surg. 151:551–561, 1960.

Meissner, W. A., and Phillips, M. J. Diffuse small-cell carcinoma of the thyroid. Arch. Path. 74:291–297, 1962.

Silverberg, S. G., and Vidone, R. A. Metastatic tumors in the thyroid. Pacif. Med. Surg. 74:175–180, 1966.

Walther, Hans E. Krebsmetastasen. Basel: Benno Schwabe and Co., Verlag, 1948.

# INDEX


Adenitis, tuberculous, 65
Adenoacanthoma, 111
Adenocarcinoma, 84
  alveolar (see also Carcinoma, follicular), 84
  papillary, **64**, 70-83, **70-79**
    and follicular carcinoma, mixed, 82, **82**, **83**
    incidence, 73
    low grade, 11
    metastasis, 71, 73, 78, 80, **115**
    metastatic, with regression, **81**
    squamous metaplasia, **119**
Adenocystoma, papillary (see also Adenoma, papillary), 50
Adenolipoma, 41
Adenoma, 43-52
  alveolar, 43
  angioinvasive, 56, 84
  benign, relationship, thyroid cancer, 61-62, **62**, **63**
  differentiation, adenomatous goiter, 35, 48-50, 52
  discrete, 43
  follicular, 43-50, **43-49**, **113**
    admixture, papillary, 82, **82**, **83**
    atypical, 43, 46-48, **47**
    colloid, 43, 45
    embryonal, 43, 45, **45**
    fetal, 43, 45, **46**
    oxyphil, 43, 45, 46, **47**
    simple, 43, 45, **46**
  Hürthle cell (see also Adenoma, follicular, oxyphil), 43, 46
  macrofollicular (see also Adenoma, follicular, colloid), 43, 46, **47**
  malignant, 56, 84
  microfollicular (see also Adenoma, follicular, fetal), 43, 45
  multiple endocrine, 64
  oncocytic (see also Adenoma, follicular, oxyphil), 46
  papillary, 50-52, **51**
    admixture, follicular, 82, **82**, **83**
    relation, benign adenoma, 61, **64**
  solitary, 43
  trabecular (see also Adenoma, follicular, embryonal), 43, 45, **45**
  with invasion, 56
Adenomatous goiter (see under Goiter)
Adiposity, hamartomatous, 41, **41**
Albores-Saavedra, J., 64, 65, 98, 101
Anderson, J. E., 64, 65
Anomalies, tumor-like, 25-29
Arean, V. M., 124, 126
Astwood, E. B., 65
Atypia, cellular, Graves' disease, **91**
Axelrad, A. A., 59

Ballard, H. S., 64, 65
Batsakis, J. G., 80, 83
Beahrs, O. H., 81, 83
Bell, G. O., 33, 36
Berkheiser, S. W., 110
Black, B. M., 81, 83
Block, M. A., 26, 27
Braunstein, H., 22, 23, 100, 101
Brewer, D. B., 122, 123
Buckwalter, J. A., 123, 126
Bullock, W. K., 42, 111

Cade, S., 65, 67
Cancer (see also Carcinoma), 11
  classification, 55-56
  early, 56
  low grade, 56
  relationship
    adenoma, 61-62, **62**, **63**
    hyperplasia, 60
    ionizing radiation, 65-66, **66**
    other endocrine disease, 64
    thyroiditis, 61
Carcinoma (see also Cancer)
  alveolar, 84
  anaplastic, 64, 102, 106
  atypical, 96
  clear cell, 93-94, **94**
  compact small cell (see also Carcinoma, undifferentiated, small cell type), 96

Carcinoma (see also Cancer) (Continued)
ectopic thyroid tissue, 127
eosinophilic cell, 95
epidermoid, 111, 111
follicular, 84-95, **84**, **86**
desmoplasia, **123**
incidence, 90
invasion (see also Invasion)
blood vessel, 85, **86**, **87**, 96
lymphatic, 85, **87**
metastasis, 88-89, **88-90**, 92-93, **92**, **96**
non-neoplastic giant cells, **110**
osseous metaplasia, **124**
oxyphilic, 95, **95**, **96**, **115**
giant cell (see Carcinoma, undifferentiated, giant cell)
Hürthle cell, 95
incidence, **57**, 69
invasion (see also Carcinoma, follicular, invasion), blood vessel, 85, **86**, **87**, 90, 96, **113**
medullary, 58, 96-101, **97-99**, **119**
association, parathyroid adenoma, 100
incidence, 99-100
metastasis, 99-101
metastatic (see Metastasis)
mixed papillary and follicular, 82, **82**, **83**
oncocytic, 95
oxyphil, 95
papillary, (see also Adenocarcinoma, papillary), 42, 60, 70, **115**
metastatic to lung, **119**
sclerosing
occult, **70**, 79
papillary, nonencapsulated, **70**
simplex, 102
solid, 96
spontaneous, animals, 58, **58**
squamous cell, 111
differentiation, squamous metaplasia, 40, 42
spindle cell, 106
surgical and pathologic staging, 56
trabecular, 84
undifferentiated, 102-110, **102**, **117**
giant cell type, 11, 106-110, **106**, **107**
mixed pattern, 102, **107-109**
small cell type, 102-105, **103**, **104**
Carcinosarcoma, 106
Carroll, R. E., **57**
Chesky, V. E., 41, 94, 110, 126
Chromaffinomatosis, familial, 100
Clements, F. W., 60, 61
Clute, H. M., 106
Cocke, W. M., Jr., 111
Colcock, B. P., 93
Cole, W. H., 61
Conard, R. A., 65, **67**
Cooper, T. V., 25, **28**
Cope, O., 52
Cox, M. T., 122, 123
Crile, G., Jr., 61, **81**, 83
Cushing's disease, association, anaplastic carcinoma, 64
Cyst
adenoma
follicular, **44**, 45
papillary, 50-52, **70**
dermoid, 29
intrathyroidal, 29
sources, 19
thyroglossal duct, 28-29, **28**
Cystadenocarcinoma, papillary (see also Adenocarcinoma, papillary), **70**
Cystadenoma (see also Adenoma, papillary), 50

De Amicis, E., 68
DeLawter, D. S., 67
Dinsmore, R. S., 121, 123
Doll, R., **57**
Doniach, I., 23, 59, 62
Dorn, H. F., 61

Ectopic thyroid tissue, 25-27, **25**, **27**
Ellenberg, A. H., 64, 65
Elliott, R. H., Jr., 128, 129

Fibrosarcoma, 123-126, **124-125**
Fish, J., 25, **28**, **127**
Fisher, E. R., 80, 83
Fitzgerald, P. J., **67**, **68**
Follicular adenoma, carcinoma (see under nouns)
Follis, R. H., Jr., 59
Fortner, J. G., 59
Frazell, E. L., 78, **83**, 95, 109, 110
Freeman, D., 101
Friedell, G. H., 101
Friedman, N. B., 45, 48
Fuller, R. H., 41
Furth, J., 59

Gardiner, W. R., 26, 28
Gilmore, Charles, 58
Goiter
adenomatoid, 30
adenomatous, 21, 30-35, **30-32**, **34**, **35**
differentiation from adenoma, 35, 48-50, 52
fibrous nodule, **113**
multiple colloid, 30
relationship, cancer, 60-61, 74
amyloid, 41, **41**
colloid, 30, 33, **34**
congenital, 30, **32**, **33**
endemic, 30, 33, 49
exophthalmic, 37
lymphadenoid, 38
metastasizing, 84
benign, 89
nodular, 30, 49
simple, 30
Goitrogens, relation, cancer, 57, 59, 65
Goldberg, H. M., 29
Goldberg, R. C., 59
Goldman, R. L., 111
Gonzalez-Angulo, A. 127
Gonzalez-Licea, A., 22, 23
Goodwin, B. D., 53
Graham, A., 56, 90, 93
Graves' disease, 26, 37, **37**, 60
cellular atypia, **91**
differentiation, papillary carcinoma, 79
relationship, papillary adenocarcinoma, 74
Gricouroff, G., 28, 84
Grieve, J., 25, 28
Gross, R. E., 29

Hamperl, H., 18, 23, 52, 95
Hanford, J. M., 67
Hare, H. F., 62, 81, 108, 110
Hashimoto's disease (see also Struma lymphomatosa), 38, **40**
Hawk, W. A., 40
Hazard, J. B., 40, 47, 52, 70, 79, 84, 90, 93, 100, 101
Heimann, P., 14, 23
Hempelmann, L. H., 67
Hendrick, J. W., 53
Hill, C. S., Jr., 70
Hirabayashi, R. N., 61
Hirsch, P. F., 11, 23
Hodgkin's disease, 121, 122
Holtz, S., 80, 84
Horn, R. C., Jr., 79, 84, 93, 95, 100, 101
Hürthle cell adenoma (see also Adenoma, follicular, oxyphil), 43, 46
Hutter, R. V., 110
Hyperparathyroidism, relation, cancer, 64
Hyperplasia
adenomatous goiter, 30-35, **35**
differentiation
cancer, 79-80
neoplasia, 49, 60
epithelium, 60
nodular, 30
nontoxic, 30
primary, 37, **37**
radioiodine induced, **66**
relationship, cancer, 60
Hyperthyroidism
adenomatous goiter, 35
primary, 37

Invasion (see also Carcinoma, invasion)
adenocarcinoma, papillary, 73, **73**, 78, 80
carcinoma
follicular, 73, 83-93, **83**, **86**, **87**
medullary, 96, 99
undifferentiated, 104-105, **105**, **113**
diagnosis, malignancy, 47-48, 52, 56, 80
Iswariah, J. D., 29

Kay, C., 23
Kellett, H. S., 121, 123
Kenyon, R., 122, 123
Keynes, G., 29
Keynes, W. M., 126
Klinck, G. H., 14, 18, 23, 42, 80, 84
Kline, B. S., 36
Klopp, C. T., 28
Kniseley, R. M., 94

Lahey, F. H., 30, 79
Langhans' wuchernde struma, 84, 85
Lesions, tumor-like (see also specific type), 25-42
causes, 19
Liechty, R. D., 52
Lincoln, A. F., 33, 36

Lindsay, S., 59
Livingstone, D. J., 126
Ljungberg, O., 100, 101
Long, R. T., 28
Louw, J. H., 36
Lymphoma, 121-123, **121**
plasmacytoma, **122**
primary, 121-122
secondary, **121**, 122-123
Lymphosarcoma, 121, **121**

Marks, S., 126
Marshall, S. F., 40
Means, J. H., 36, 37, 65
Meissner, W. A., 52, 60-62, 72, 78, 82, 84, 86, 92, 93, 103, 106, 121-123, 129
Metaplasia
osseous, follicular carcinoma, **124**
squamous, 42, **42**, **75**, 111, 118
adenocarcinoma, papillary, 72, 74, **75**
differentiation, squamous cell carcinoma, 40, 42
thyroiditis, 40
Metastasis (see also specific type of cancer)
benign, 27
radiation treatment, 93
Metastasis from thyroid, 56, 69
carcinoma
follicular, 88-90, 88-**90**, 92-93, **92**, **96**
medullary, 99-101
papillary, 70, **71**, 78-80, **115**, **117**
undifferentiated, 104, 108
fibrosarcoma, 126
hemangiopericytoma, maligant, 126
melanoma, malignant, **117**
teratoma, 126
Metastasis to thyroid, 27, 127-129
adenocarcinoma, breast, **129**
carcinoma
renal cell, 128-129, **128**
stomach, **117**
Meyer, J. S., 22, 24, 100, 101
Mikal, S., 121, 123
Miller, J. M., 36
Mochizuki, Y., 13, 24
Money, W. L., 59, 60
Moore, R. A., 45, 48
Mortensen, J. D., 24
Murphy, W. B., 52
Muscle, striated, in thyroid, **26**

Mustacchi, P., 57

Neoplasia, and hyperplasia
association, 60
differentiation, 49
Neoplasm, differentiation, nodule, endemic goiter, 11, 49
Newstedt, J. R., 53, 126
Nicastri, A. D., 26, 28
Nodule, 61
cold, 35, **36**, 68
discrete, 43, 50
endemic goiter, differentiation from true neoplasm, 11, 49
fibrous, adenomatous goiter, **113**
radiation induced, 65-66, **66**
solitary, 43
Noteboom, G., 29

Ogburn, P. L., 64, 65
Olen, E., 60

Papillary adenocarcinoma, adenoma, carcinoma (see under nouns)
Park, W. W., 91, 93
Pemberton, J. deJ., 60
Pendergast, W. J., 60, 61
Pifer, J. W., 65, 67
Plasmacytoma, **122**
Pochin, E. E., 68, 81, 84
Pollock, W. F., 29
Potter, G. D., 52, 59, 60
Prokš, C., 126

Radiation
differentiation, lymphoma and sarcoma, 122
hyperplasia, **66**
reaction, thyroid, **66**
relation, cancer, 65-66, **66**, 69, 91
Radioiodine uptake
carcinoma, 67-68, **68**
follicular, 68, **68**, 85, 93
papillary, 81
normal thyroid, 67, **67**
Rather, L. J., 109, 110
Raventos, A., 65, 67
Rosvoll, R. V., 69, 70

Roth, L. M., 26, 28
Roth, S. I., 18, 24
Rouse, R. M., 101
Russell, W. O., 78, 82, 84, 85, 93
Russfield, A. B., 65

Sarcoma, 123-126
Scar, 70, 79, 96
Schlumberger, H. G., 58
Scott, G. B., 121, 123
Shaw, R. C., 121, 123
Shimaoka, K., 68
Silberman, R., 53
Silliphant, W. M., 89, 93, 109, 110
Silverberg, S. G., 57, 128, 129
Sinha, D., 59, 60
Smedal, M. I., 56, 84, 85, 93, 106, 110
Smith, L. W., 123, 126
Snedecor, P. A., 127
Socolow, E. L., 65, 67
Stanbury, J. B., 36
Starr, P., 78, 84
Struma
    Langhans' wuchernde, 84, 85
    lymphomatosa, 38, **39**, **40**, 61, **117**
    ovarii, 27, **27**, 127, **127**
    Riedel's, 38
Studer, H., 36

Taylor, S., 36
Teratoma
    benign, 53, **53**
    malignant, 126
Thomas, C. G., Jr., 24
Thyroglossal duct
    adenocarcinoma, papillary, 74, 127
    cysts, 28-29, 28
Thyroid gland
    carcinoma (see Carcinoma)
    normal, 13-23, **13-17**
        radioiodine uptake, 67, **67**
    sublingual, 25, **25**
Thyroiditis
    chronic
        diffuse, fibrotic, **40**
        nonspecific chronic, 40, **40**
    de Quervain's, 38
    differentiation, tumor, 37
    granulomatous, 38
    invasive fibrous, 38
    pseudotuberculous, 38
    relationship, cancer, 61, 74
    subacute, 38, **38**
    viral, 38
Thyrotoxicosis, from struma ovarii, 27
Tollefsen, H. R., 80, 81, 84
Tonietti, G., 24
Tremblay, G., 18, 20, 24
Trumbull, Merlin L., 110
Tumor (see also specific type)
    anaplastic, 55-56
    benign, 53
    malignant
        experimental, 59
        miscellaneous, 121-129
        potentially, 56
        radiation-induced, 65-66
        spontaneous, animals, 58, 58
        unclassified, **125**
    parafollicular cell, 22, **23**, 58
    polymorphous cell, 106
    secondary, 127-129
Tumor-like lesions, causes, 19

Valenta, L., 24
Van Dyke, J. H., 42
Vassar, P. S., 98, 101
Vickery, A. L., 66, 67
von Recklinghausen's disease, 100

Walker, G. A., 41
Walt, A. J., 121, 123
Walther, Hans E., 126, 128, 129
Warren, S., 75, 87, 90, 92, 93
Wegelin, C., 60, 61
Wegmann, W., 66, 67
Welch, C. E., 36
Werner, S. C., 37
Williams, E. D., 22, 24, 58, 99-101
Willis, J., 57
Winship, T., 69, 70, 121, 123
Woolner, L. B., 40, 80, 84, 99, 101, 104, 106, 121, 123

Young, B. A., 18, 24

Zondek, H., 52

NH LIBRARY

PROFESSIONAL NOTES AND FINDINGS

DATE DUE

DEC 22 1975

JAN 26 1976

GAYLORD

PRINTED IN U.S.A.

NIH LIBRARY

LIBRARY
NIH
Amazing Research.
Amazing Help.

http://nihlibrary.nih.gov

10 Center Drive
Bethesda, MD 20892-1150
301-496-1080

NIH LIBRARY
4 0087 8621

NIH LIBRARY
3 1496 00195 0826

OCT 8 1986
NOV 29 1986
APR 5 1989
MAY 26 1989